

# Global™ Fx

SHOULDER FRACTURE SYSTEM



TABLE OF CONTENTS

Introduction . . . . . 2

    System Highlights . . . . . 3

Surgical Technique . . . . . 6

    Patient Positioning . . . . . 6

    Deltpectoral Incision . . . . . 7

    Releasing the Pectoralis Major Tendon and Clavipectoral Fascia . . . . . 8

    Musculocutaneous Nerve Identification. . . . . 9

    Greater and Lesser Tuberosity Identification . . . . . 9

    Axillary Nerve Identification . . . . . 10

    Humeral Head Excision and Measurement . . . . . 10

    Cancellous Bone Removal . . . . . 12

    Humeral Prosthesis Shaft Preparation . . . . . 12

    Medullary Canal Reaming . . . . . 13

    Lesser and Greater Tuberosity Mobilization . . . . . 14

    Restoring Proper Humeral Length . . . . . 15

    Proper Trial Prosthesis Positioning . . . . . 16

    Restoring Proper Retroversion . . . . . 17

    Global Fx Positioning Jig . . . . . 18

        Fin Clamp Attachment . . . . . 19

        Adjusting Humeral Retroversion . . . . . 20

        Trial Reduction . . . . . 21

    Trial Reduction of Tuberosities Around the Trial Prosthesis . . . . . 22

    Modular Prosthesis Assembly . . . . . 23

    Shaft Preparation Technique for Tuberosity Fixation . . . . . 24

    Cementing the Prosthesis . . . . . 24

    Removing Excess Cement . . . . . 25

    Bone Graft Between the Prosthesis Collar and the Humeral Shaft . . . . . 25

    Reattaching the Greater and Lesser Tuberosities to the Proximal Humeral Shaft . . . . . 26

        Sutures from the Shaft to the Tuberosities . . . . . 26

        Sutures Between the Tuberosities and Through the Anterior Fin . . . . . 26

        Sutures From the Medial Fin Around Both Tuberosities . . . . . 27

    Tying the Suture Fixation . . . . . 28

    Rotator Interval Closure and Long Head Biceps Tenodesis . . . . . 28

    Importance of Repairing the Tuberosities in Relationship to the Anterior Fin. . . . . 29

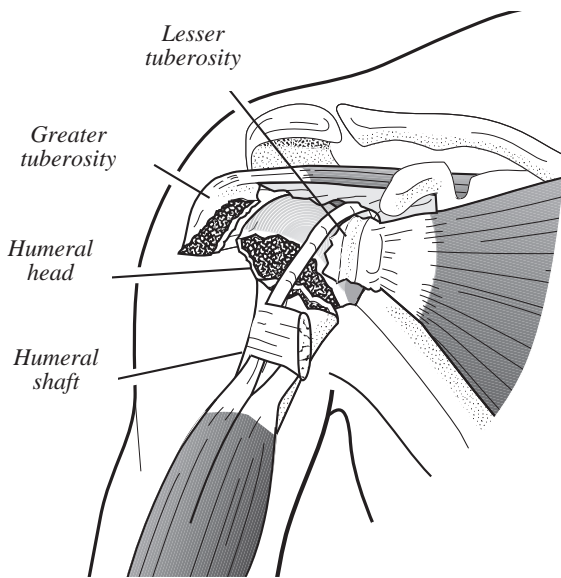
    External Rotation Problem When Repairing Tuberosities to the Lateral Fin . . . . . 30

    Wound Closure . . . . . 31

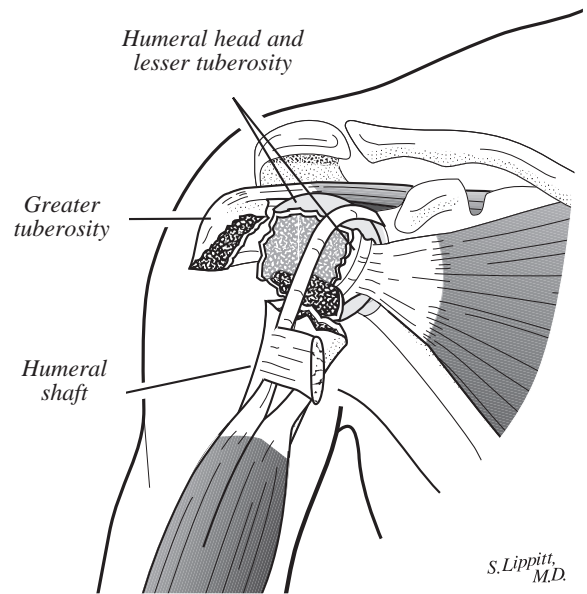
Proximal humeral fractures are one of the most common indications for shoulder replacement. The Global Fx Shoulder Fracture System meets the unique challenges of prosthetic reconstruction of proximal humeral fractures previously unaddressed by earlier shoulder arthroplasty systems.

Managing proximal humeral fractures using a prosthesis is ordinarily indicated for patients over 59 years old with a four-part fracture (Figure 1), fracture dislocation or, in some cases, a three-part fracture (Figure 2) with osteopenia, comminution and generalized patient debilitation. In younger patients, surgeons may choose to treat the fracture with open reduction and internal fragment fixation or with an implant.

If an implant is chosen as treatment, the goals to be met are restoring proper mechanics, achieving adequate range of motion and eliminating patient discomfort. These goals can be met by selecting the proper humeral prosthesis height, establishing the desired humeral component retroversion and achieving anatomic and secure fixation of the tuberosities to each other and to the humeral shaft.

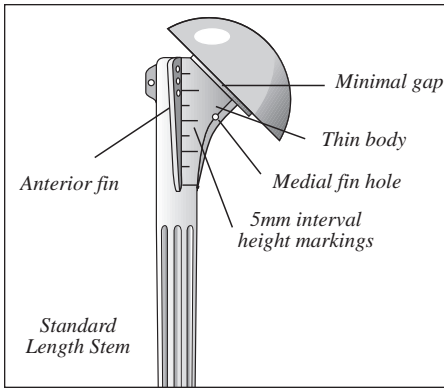


**Figure 1**  
Four-part proximal humeral fracture. The articular segment is a free fragment void of any soft tissue attachment or blood supply. The greater tuberosity is displaced superiorly and posteriorly by the pull of the attached rotator cuff while the lesser tuberosity is retracted medially by the pull of the subscapularis. The surgical neck of the humeral shaft is displaced medially by the pull of the pectoralis major.

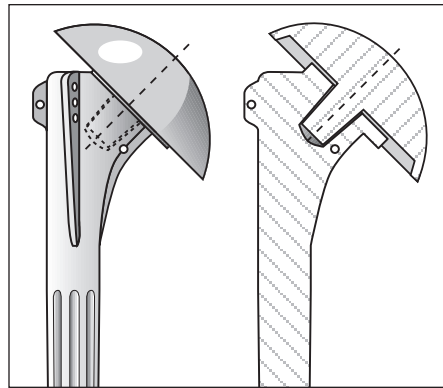


**Figure 2**  
Three-part greater tuberosity proximal humeral fracture. The articular segment is rotated internally by the pull of the subscapularis tendon attached to the lesser tuberosity. The greater tuberosity is displaced superiorly and posteriorly by the pull of the attached rotator cuff. The humeral shaft is displaced medially by the pull of the pectoralis major.

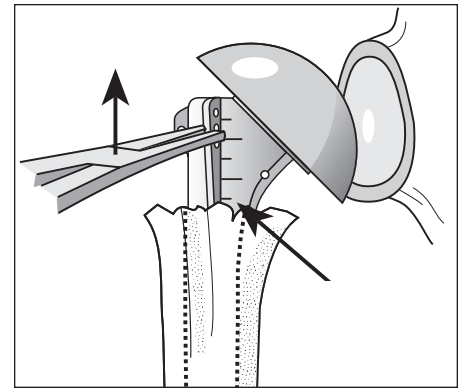
S. Lippitt, M.D.



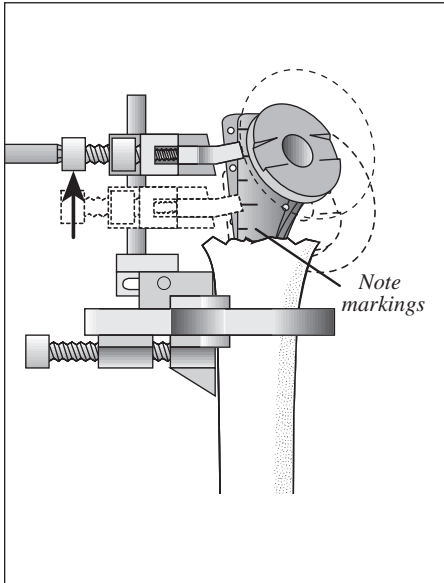
1. The reduced proximal humeral body helps preserve bone stock when reattaching the tuberosities.



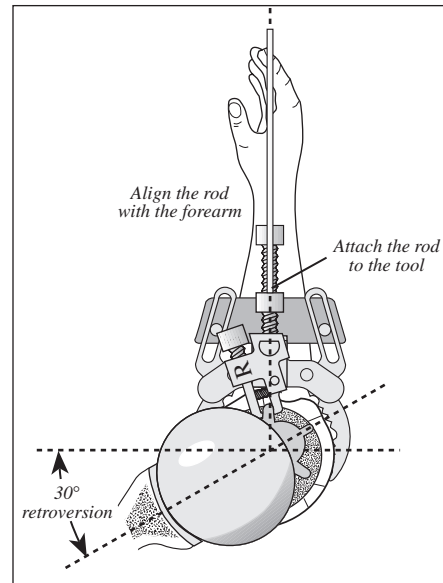
2. The new head and collar design, developed from an extensive anthropometric study, increases articular surface area and improves joint biomechanics.



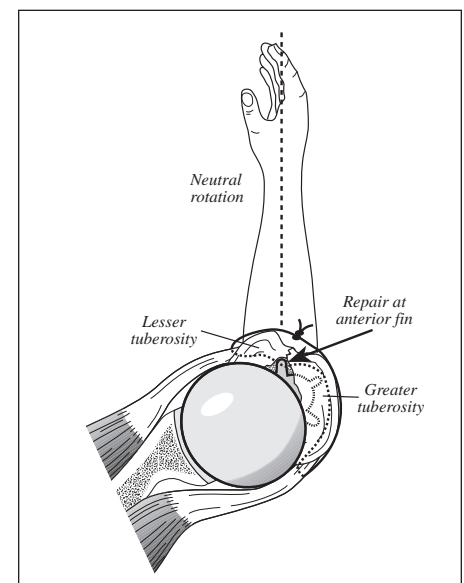
3a. Height indications on the humeral stem and trials help improve height assessment accuracy.



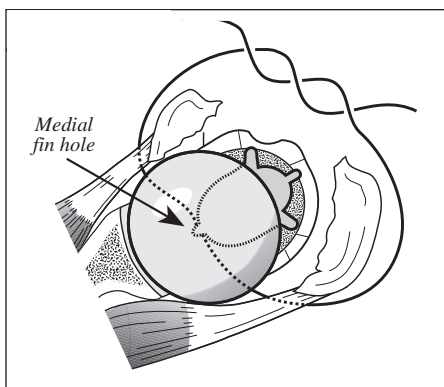
3b. A Positioning Jig provides easier, more accurate height and version adjustments.



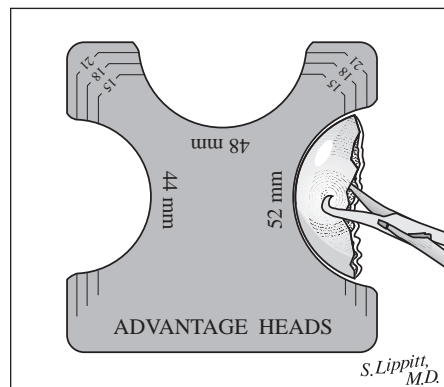
3c. Version of the prosthesis.



4. The anterior fin alignment provides a landmark for a more anatomic tuberosity reconstruction.

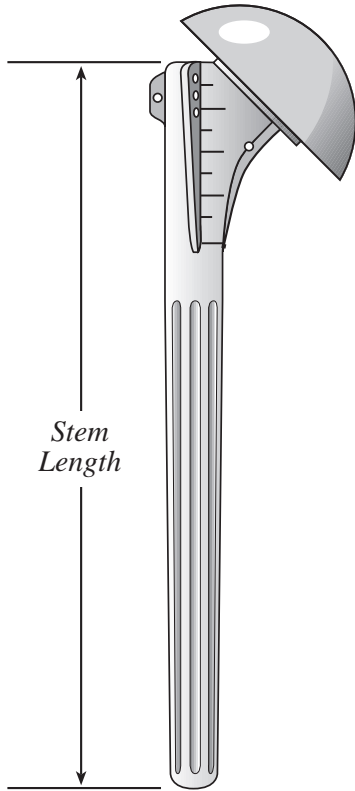


5. A medial hole in the body provides an additional point-of-suture fixation around the tuberosities.



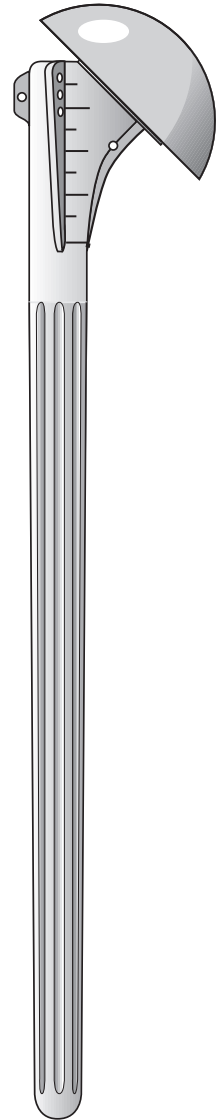
The Global Fx System is available in four body sizes (6, 8, 10 and 12mm) with standard and long stem lengths (Figures 3a and b). Modular head sizes

are defined by the spherical diameter and head height and the include the sizes noted in Figure 4.



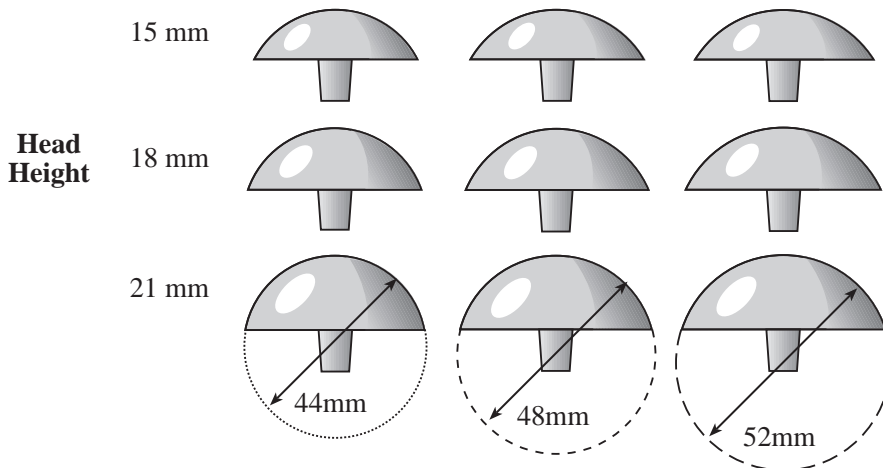
**Figure 3a**  
Global Fx  
standard length  
stem with an  
Advantage  
Humeral Head.

Stem Lengths		
Body Size	Std Length	Long Length
6mm	120mm	160mm
8mm	130mm	200mm
10mm	140mm	210mm
12mm	150mm	220mm



**Figure 3b**  
Global Fx long  
stem with an  
Advantage  
Humeral Head.

**Global Advantage Humeral Head Sizes**



**Figure 4**

S. Lippitt,  
M.D.

# INTRODUCTION

As a result of designing the collar to recess into the humeral head underside, there is minimal articular gap between the assembled modular humeral head

and stem components (Figure 5). This helps maximize the humeral articular surface area when reconstructing the humeral head anatomy.

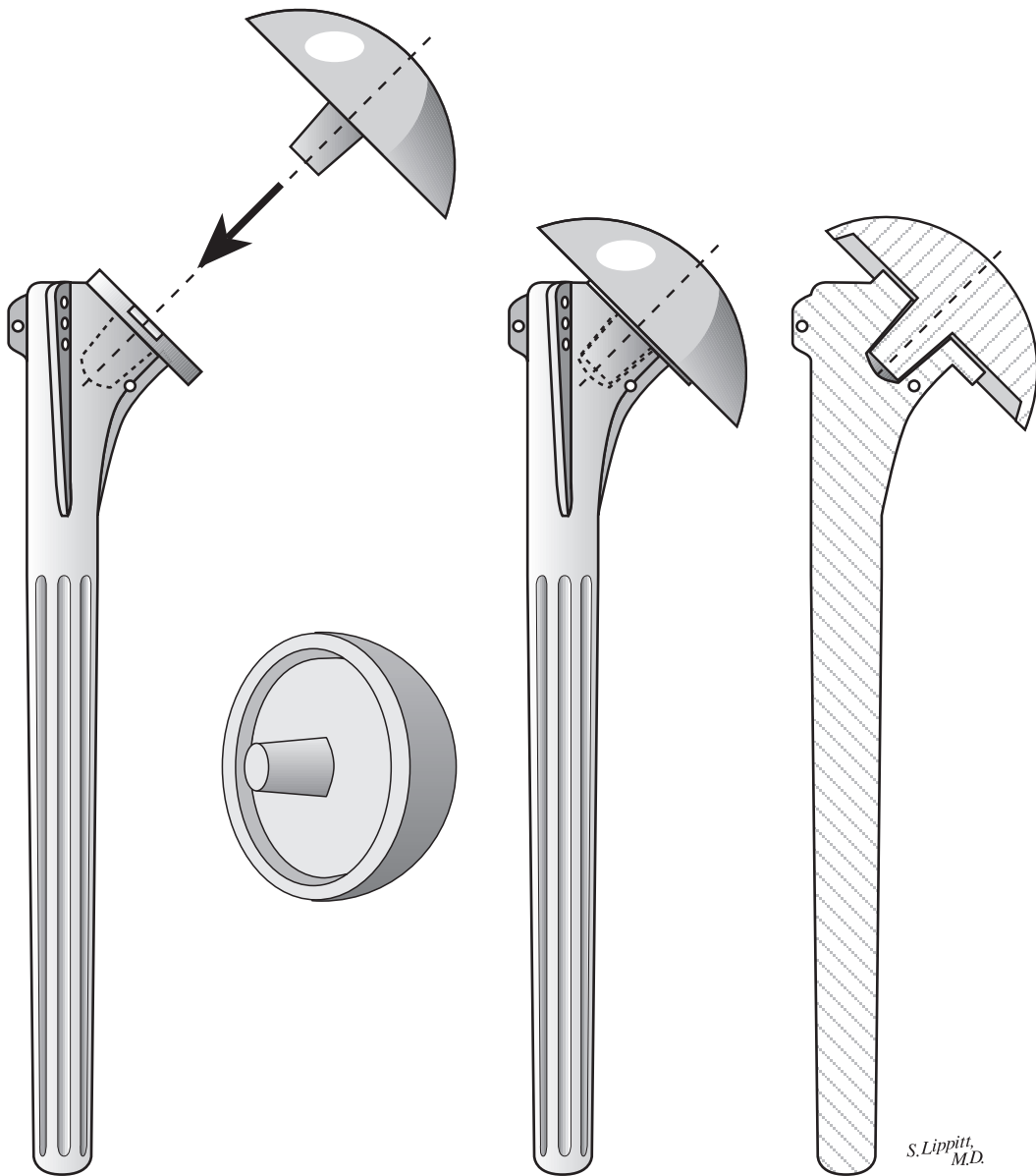


Figure 5

S. Lippitt, M.D.

GLOBAL FX SHOULDER FRACTURE SYSTEM SURGICAL TECHNIQUE  
FOR PROXIMAL HUMERAL FRACTURES

Charles A. Rockwood, Jr., MD, Frederick A. Matsen, III, MD and Steven B. Lippitt, MD

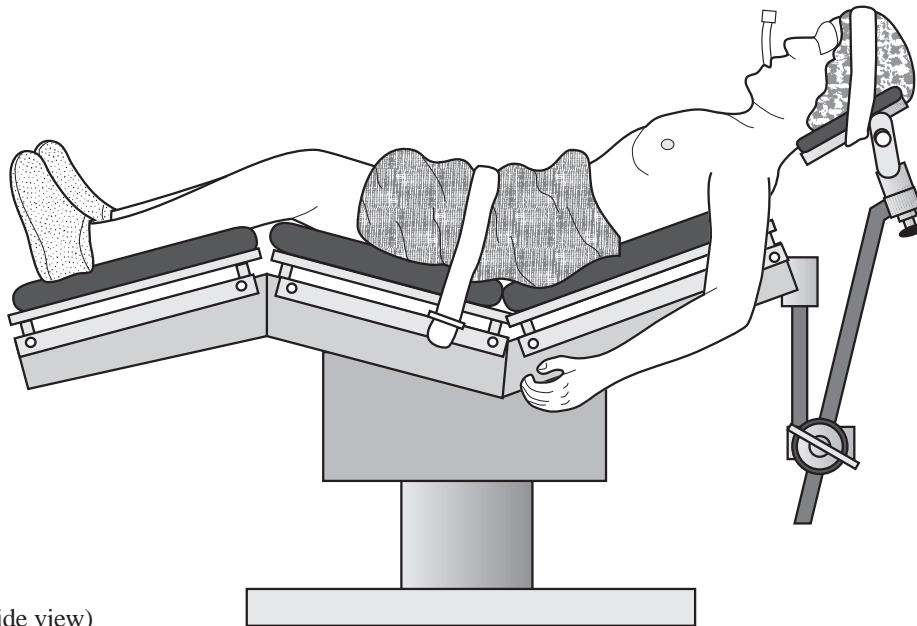
Illustrations by Steven B. Lippitt, MD

PATIENT POSITIONING

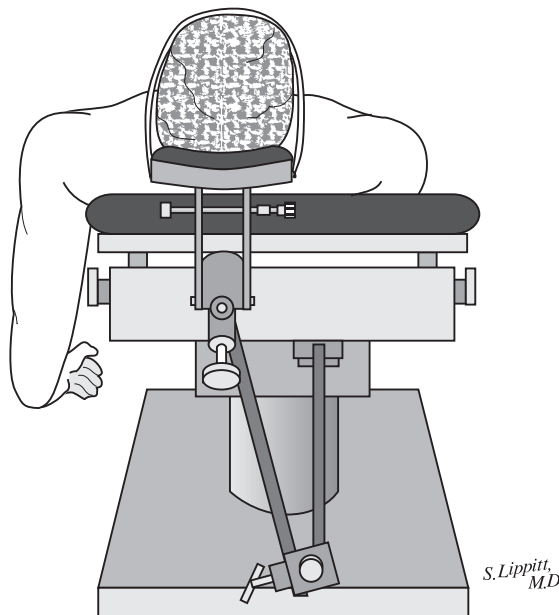
Place the patient in a semi-Fowler position (Figure 6a). Remove the table's standard headrest and replace it with a McConnell headrest, which allows free access to the shoulder's superior aspect.

Position the patient so the involved shoulder extends over the top corner and edge of the table (Figures 6a and b).

Secure the patient's head with tape. Use a drape to isolate the anesthesia equipment from the sterile field.



**Figure 6a**  
Patient positioning (side view)



**Figure 6b**  
The involved shoulder should extend over the table edge.

S. Lippitt, M.D.

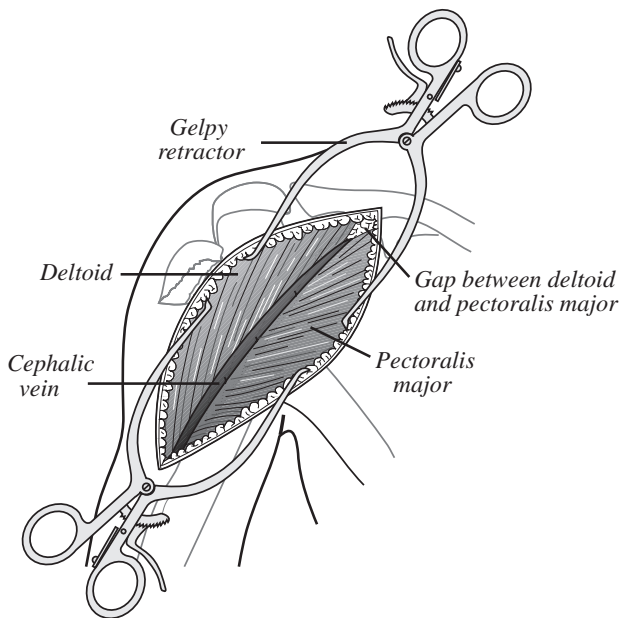
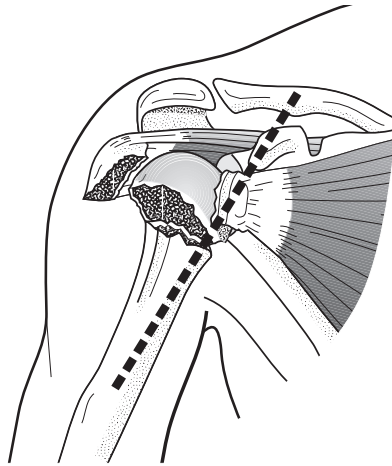
DELTOPECTORAL INCISION

Extend the incision from the distal clavicle across the coracoid process and down to the anterior aspect of the arm (Figure 7). Once the incision is made, locate the cephalic vein on the deltoid muscle near the deltopectoral interval

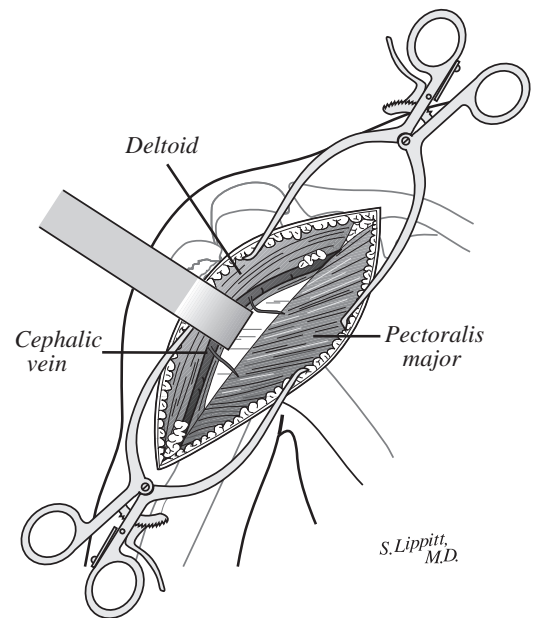
(Figure 8a). There is usually a gap superiorly between the deltoid and the pectoralis major muscles, and the pectoralis major muscle fibers are more horizontal than the deltoid fibers.

To preserve the venous drainage of the deltoid muscle, retract the cephalic vein laterally with the deltoid muscle while developing the deltopectoral interval (Figure 8b). Cauterize or ligate the venous tributaries from the pectoralis major.

**Figure 7**  
Deltopectoral incision



**Figure 8a**  
Deltopectoral interval



**Figure 8b**  
Retract the cephalic vein laterally to preserve the venous drainage of the deltoid muscle.

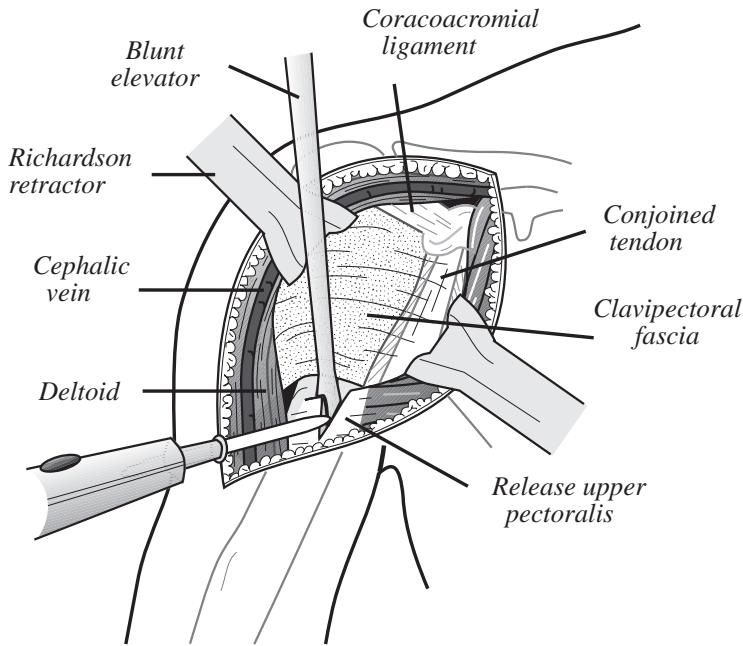
S. Lippitt, M.D.



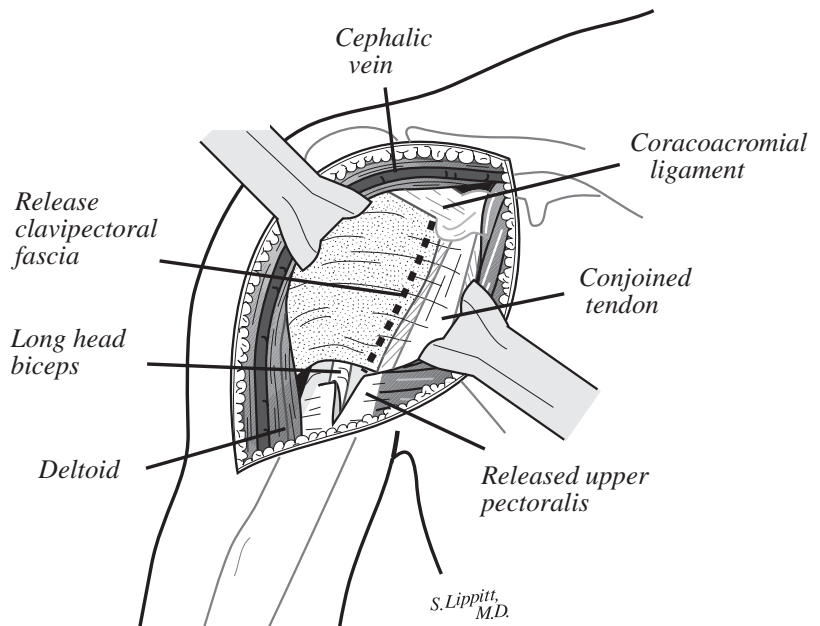
RELEASING THE PECTORALIS MAJOR TENDON AND CLAVIPECTORAL FASCIA

Protect the long head of the biceps tendon with a retractor or finger while releasing the upper portion of the pectoralis major tendon (Figure 9a). Releasing the tendon provides better exposure of the joint's inferior aspect.

Retract the deltoid and pectoralis major tendon to reveal the underlying clavipectoral fascia (Figure 9b). Divide the clavipectoral fascia just lateral to the conjoined tendon (dotted line) superiorly to the level of the coracoacromial ligament, which is preserved.



**Figure 9a**  
Release the upper portion of the pectoralis major tendon.



**Figure 9b**  
Divide the clavipectoral fascia lateral to the conjoined tendon (dotted line).

**MUSCULOCUTANEOUS NERVE IDENTIFICATION**

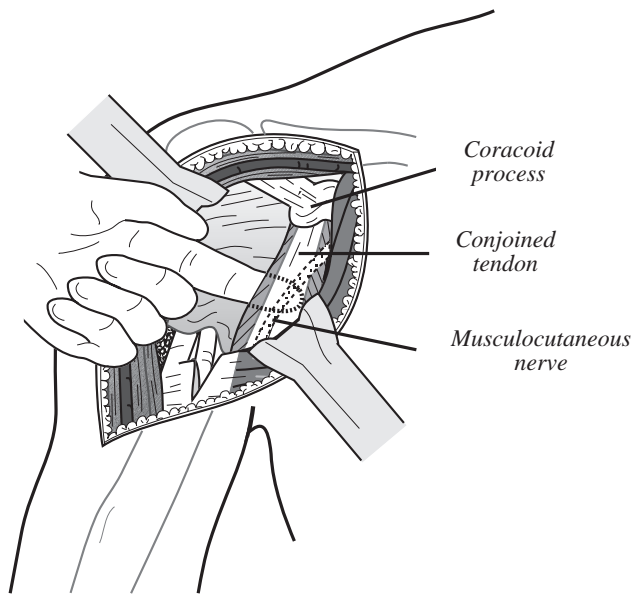
In fracture cases, it is important to identify and protect the musculocutaneous nerve. Palpate the musculocutaneous nerve as it comes from the brachial plexus into the posteromedial aspect of the conjoined

tendon (Figure 10). The nerve usually penetrates the muscle one to two inches inferior to the tip of the coracoid process. In some instances, the nerve has a higher penetration into the conjoined muscle tendon unit. Remember the nerve location when retracting the conjoined tendon.

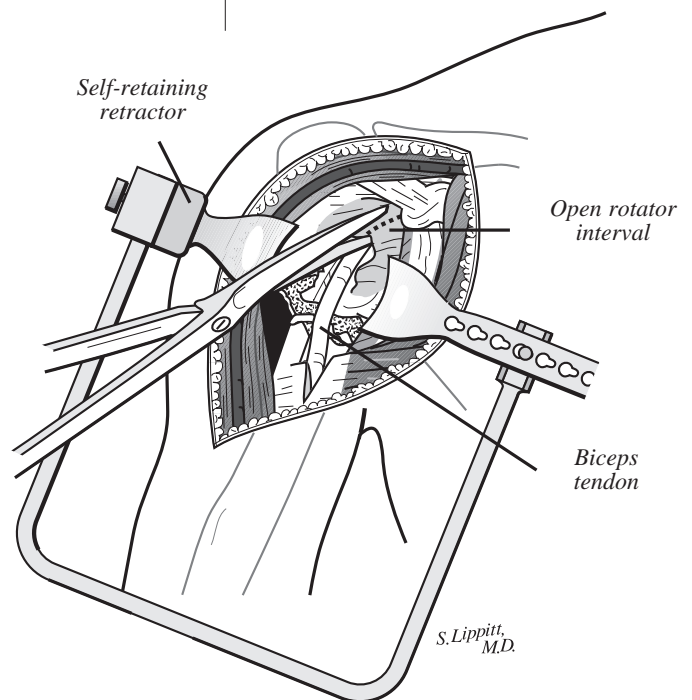
**GREATER AND LESSER TUBEROSITY IDENTIFICATION**

The biceps tendon is an excellent landmark to identify the interval between the lesser and greater tuberosity. Place a pair of scissors into the sheath of the biceps tendon and divide the transverse humeral ligament.

Continue proximally to open the rotator interval between the subscapularis and the supraspinatus tendons to the base of the coracoid process. Obtain retraction with the Hawkins-Bell Self-Retaining Retractor (Figure 11). If adequate assistance is available, use Richardson retractors medially and laterally.



**Figure 10**  
Palpate the musculocutaneous nerve beneath the conjoined tendon.



**Figure 11**  
Identify the long head of the biceps and release the transverse humeral ligament and rotator interval.

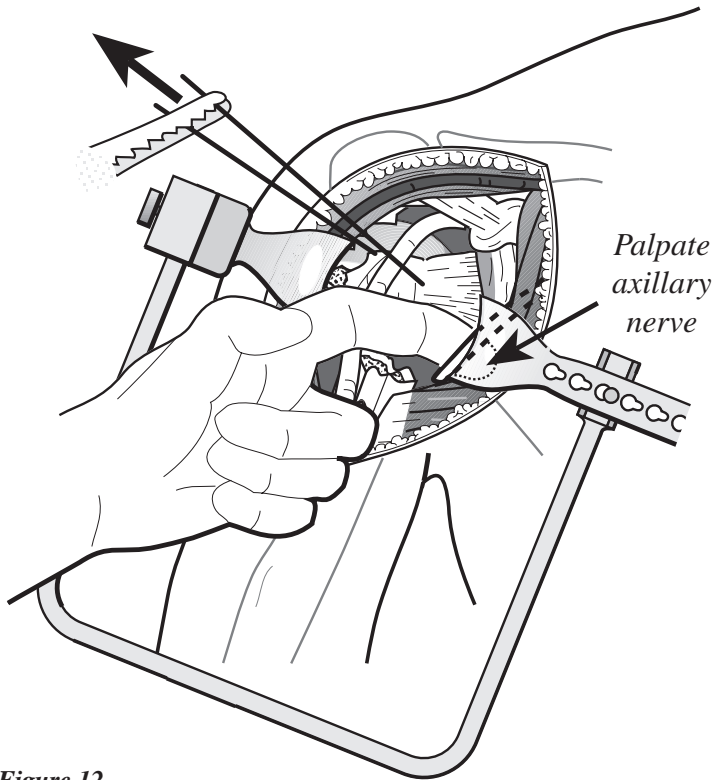
**AXILLARY NERVE IDENTIFICATION**

Palpate the axillary nerve by passing the volar surface of the index finger down along the anterior surface of the subscapularis muscle. Rotate and hook the finger anteriorly to identify the

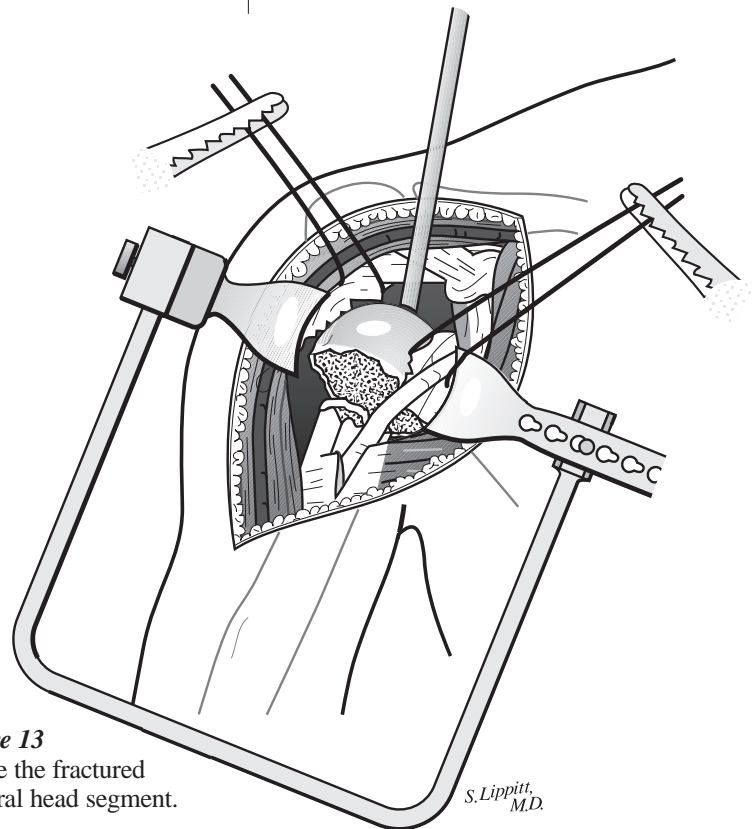
axillary nerve (Figure 12). Traction on the lesser tuberosity fragment will make it easier to identify the axillary nerve. Use a Scofield-type retractor to retract and protect the nerve during inferior capsule release.

**HUMERAL HEAD EXCISION AND MEASUREMENT**

With the greater and lesser tuberosities retracted out of the way by stay sutures, use a bone hook or clamp to retrieve the fractured humeral head (Figure 13).



**Figure 12**  
Palpate the axillary nerve.



**Figure 13**  
Excise the fractured humeral head segment.

S. Lippitt, M.D.

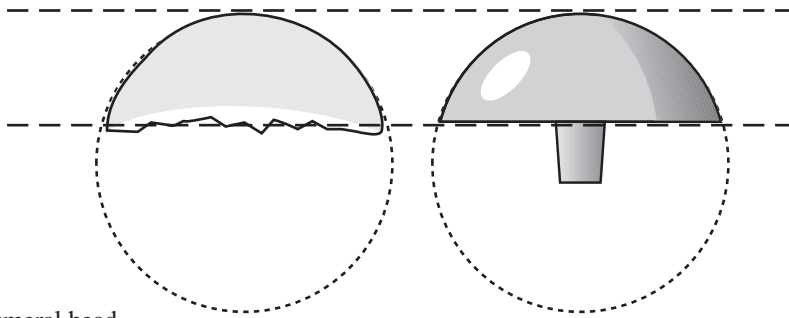
SURGICAL TECHNIQUE

HUMERAL HEAD EXCISION AND MEASUREMENT (cont.)

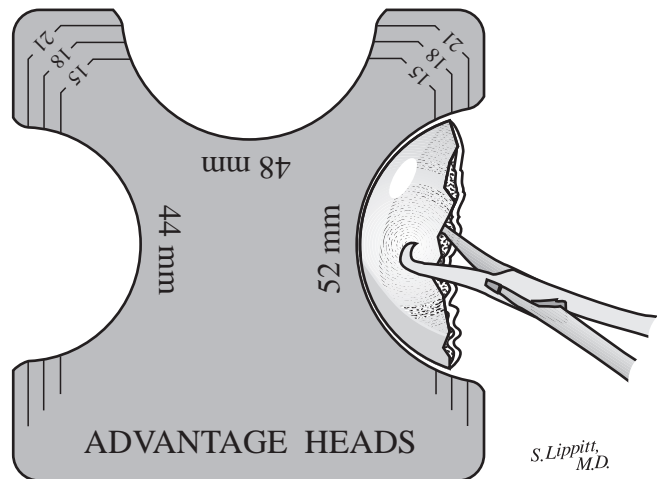
The selected humeral head component must approximate the resected humeral head height and radius of curvature

(Figure 14a). Measure the resected humeral head for height and diameter using the Humeral Head Template (Figure 14b). The Global Advantage

Humeral Head trials for the fracture set range from 15, 18 and 21mm heights and 44, 48 and 52mm diameters (Figure 4, pg. 4).



**Figure 14a**  
Compare the humeral head component to the resected head's height and curvature.



**Figure 14b**  
Measure the resected humeral head height and diameter with the template to select the head component.

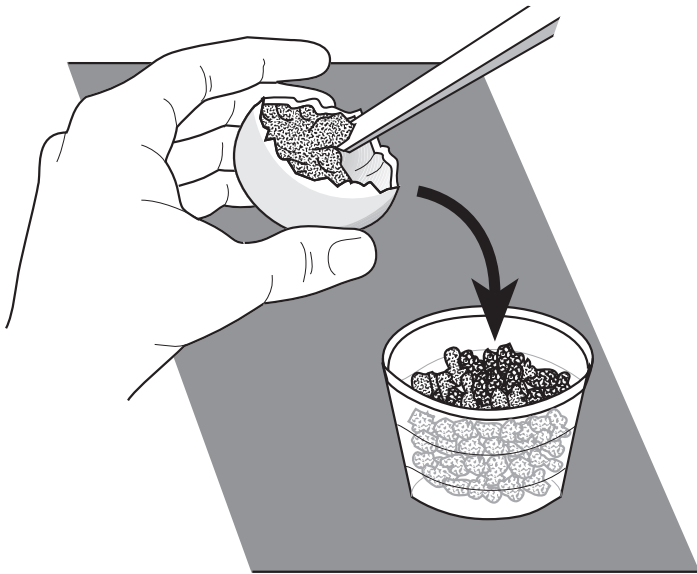
CANCELLOUS BONE REMOVAL

After selecting the humeral head component, place the humeral head on

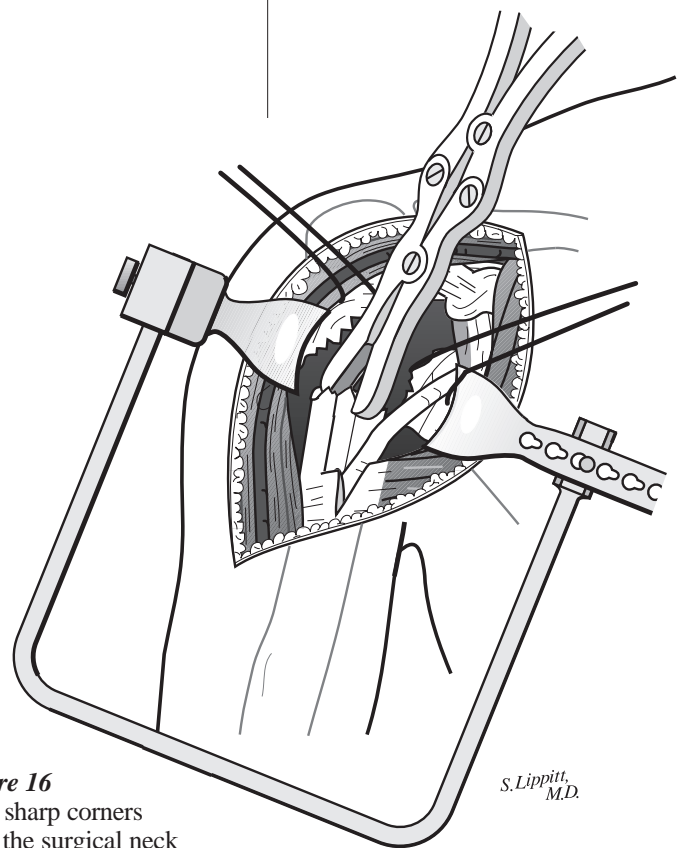
the back table to remove the cancellous bone (Figure 15). Use the cancellous graft to help secure the tuberosity fixation.

HUMERAL PROSTHESIS SHAFT PREPARATION

Extend the arm off the side of the table, which delivers the shaft up and out of the wound. Use a rongeur to trim the sharp corners of the shaft (Figure 16). Remove bone fragments and blood clots from the humeral shaft canal.



**Figure 15**  
Obtain cancellous bone from the resected humeral head for later use as a bone graft.



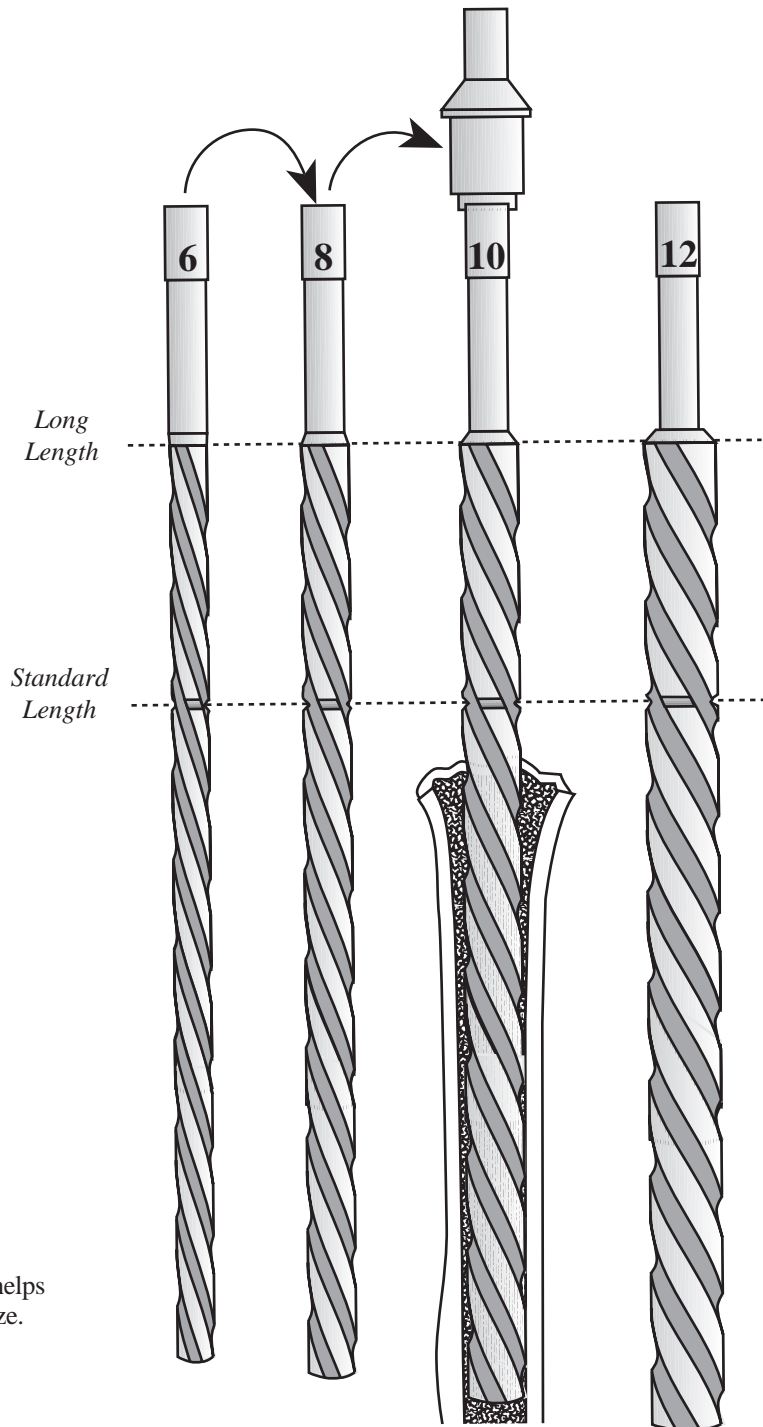
**Figure 16**  
Trim sharp corners from the surgical neck of the shaft.

S. Lippitt, M.D.

MEDULLARY CANAL REAMING

Ream the medullary canal if necessary to remove bony fragments and to determine a humeral body size. Four hand reamer sizes are available in 2mm increments from 6 to 12mm (Figure 17).

The horizontal groove on the reamer identifies its use for the standard length and the end of the flute for the long stem prosthesis. The 10mm reamer fills the canal in Figure 17, suggesting that a 10mm standard length humeral body should be used.



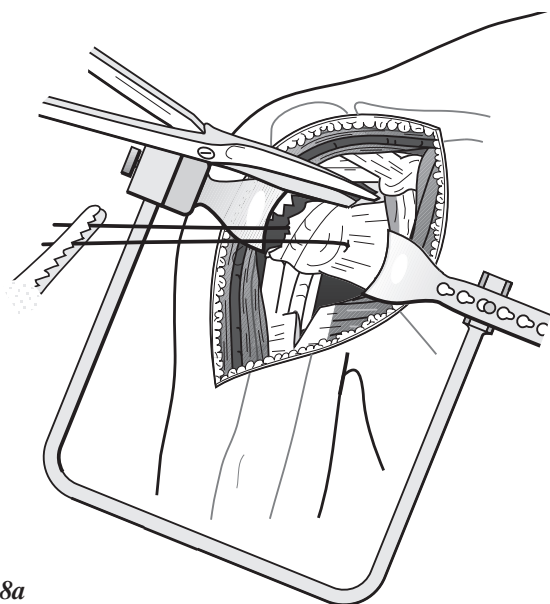
**Figure 17**  
Reaming the medullary canal helps determine the humeral body size.

S. Lippitt,  
M.D.

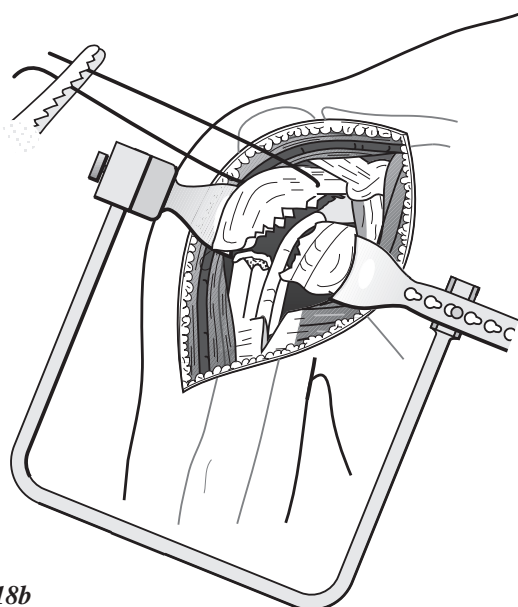
LESSER AND GREATER TUBEROSITY MOBILIZATION

Free the lesser tuberosity from the underlying soft tissues (Figure 18a). Take care to protect the axillary nerve while mobilizing the lesser tuberosity and the attached subscapularis muscle tendon unit.

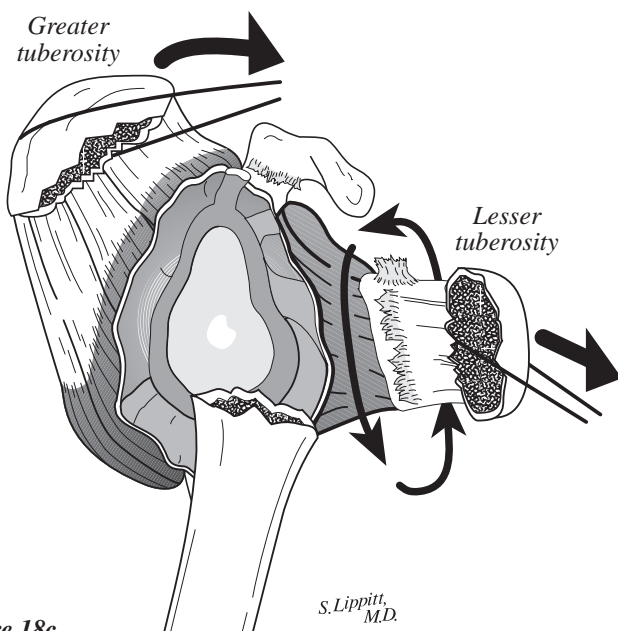
Carefully identify and free the greater tuberosity in a similar manner (Figure 18b). It is important to free and mobilize the lesser and greater tuberosities so they can be attached to each other, around the prosthesis and back to the humeral upper shaft (Figure 18c).



**Figure 18a**  
Freeing the lesser tuberosity



**Figure 18b**  
Freeing the greater tuberosity



**Figure 18c**

S. Lippitt, M.D.

RESTORING PROPER HUMERAL LENGTH

Attach the proper size trial head to a small trial prosthesis, and place it into the intramedullary canal. The body should be small enough to allow passage

into the canal with the inferior aspect of the head sitting on the humeral proximal shaft (Figure 19a). With the arm held at the patient's side, parallel to the floor and in zero degrees of rotation (Figure 19b), apply gentle traction to the arm.

Zero degrees of rotation is most easily determined when the elbow is flexed 90 degrees and the forearm is pointed directly anterior (Figure 19c).

While maintaining traction on the arm, use an instrument to lift the prosthesis head up to the level of the glenoid fossa. The prosthesis shaft has horizontal marks to determine how high the prosthesis should be when the head is adjacent to the glenoid fossa (Figure 19d).

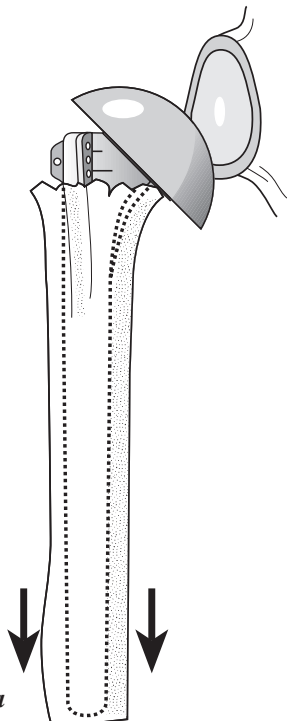


Figure 19a

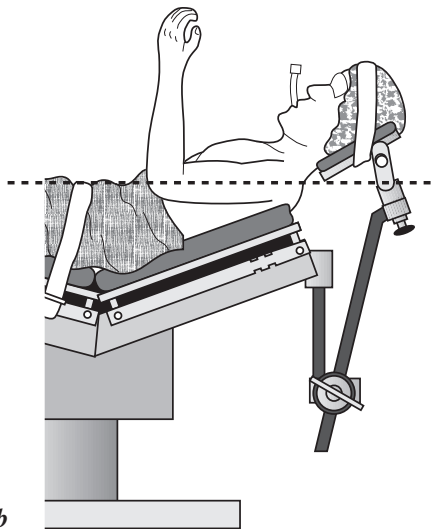


Figure 19b

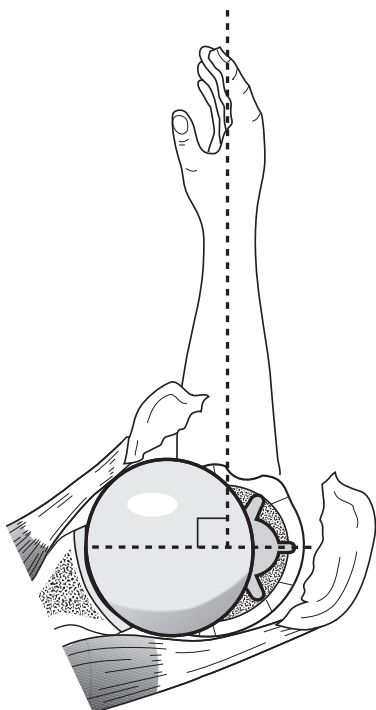


Figure 19c

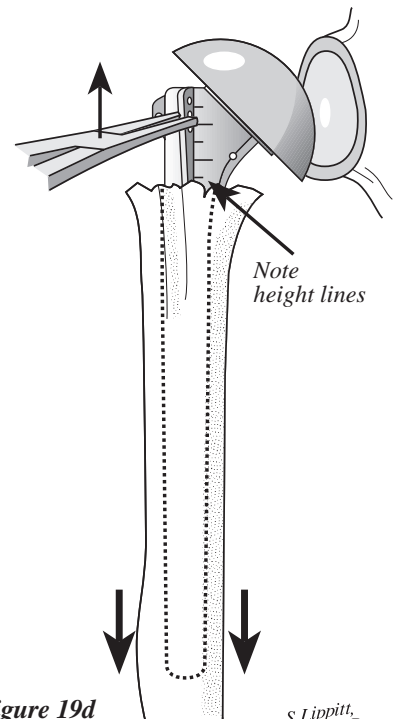


Figure 19d

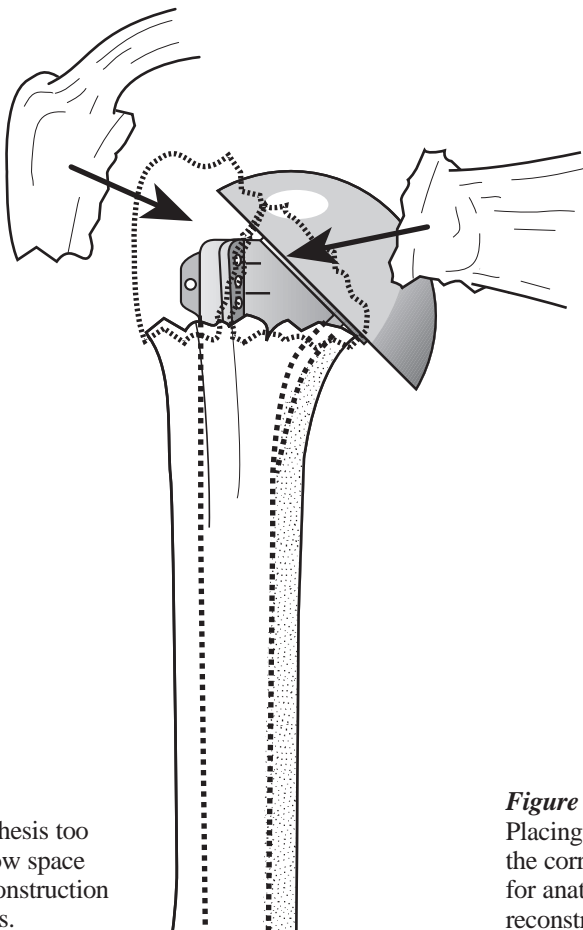
S. Lippitt, M.D.



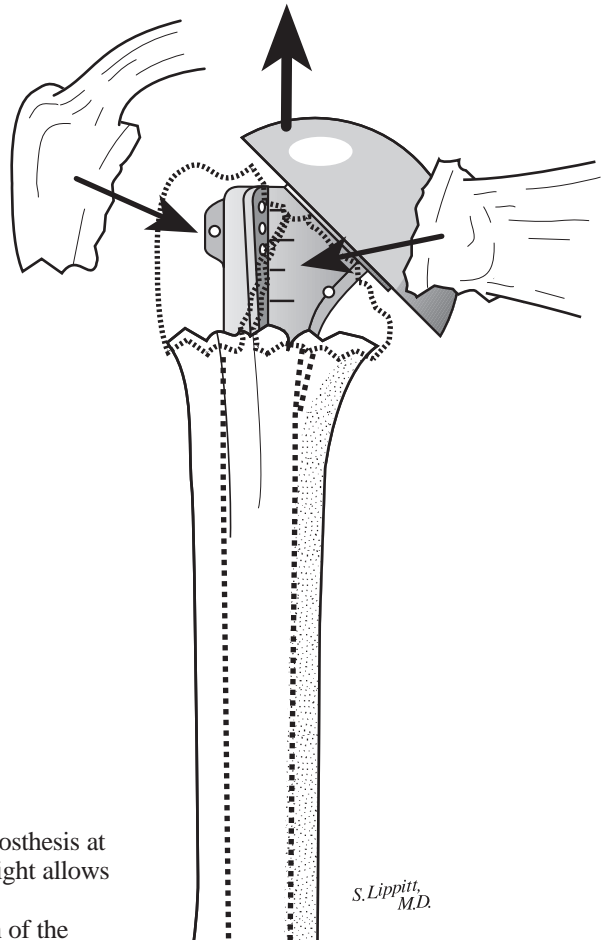
PROPER TRIAL PROSTHESIS POSITIONING

Position the trial stem at the correct height to preserve space for anatomic reconstruction of the tuberosities below

the collar and head of the prosthesis (Figures 20a and b). A slight overlap of the tuberosities on the shaft is desirable.



**Figure 20a**  
Placing the prosthesis too low does not allow space for anatomic reconstruction of the tuberosities.



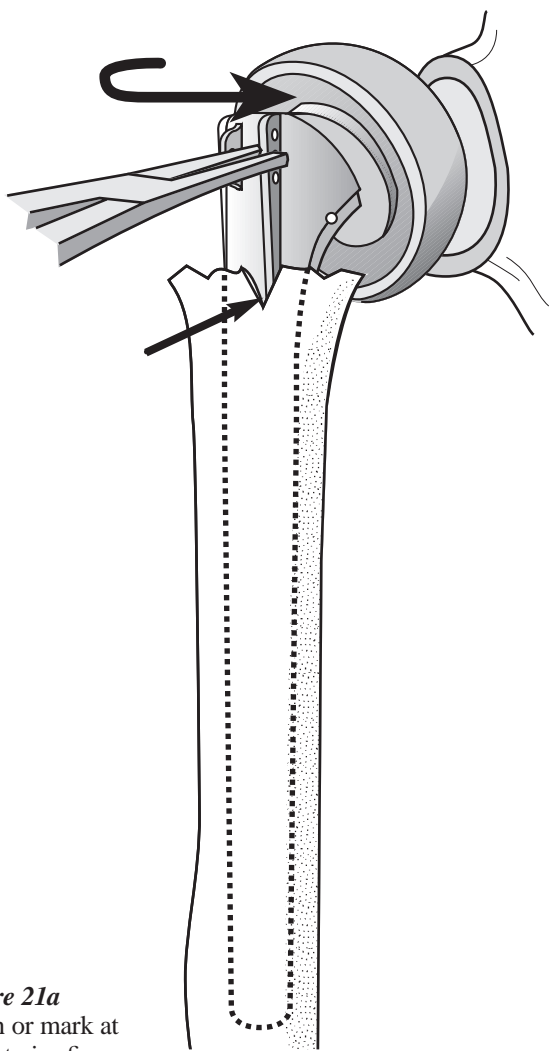
**Figure 20b**  
Placing the prosthesis at the correct height allows for anatomic reconstruction of the tuberosities.

S. Lippitt,  
M.D.

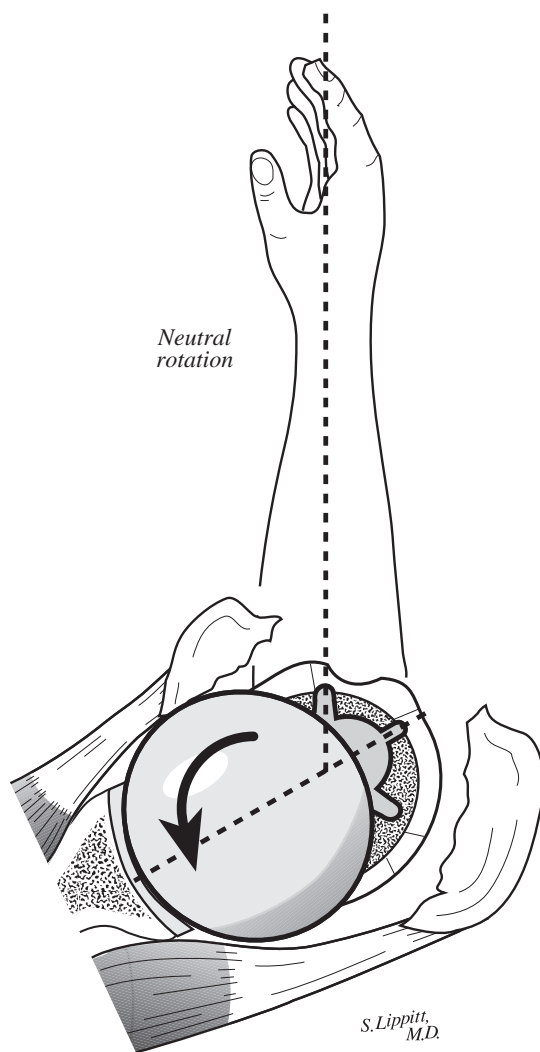
RESTORING PROPER  
RETROVERSION

While maintaining traction to hold the prosthesis at the proper height, internally rotate the prosthesis until the head is directed into the glenoid fossa (Figure 21a). The usual amount of retroversion will vary between 25-30 degrees.

Typically, the anterior fin will be in line or just medial to the old bicipital groove, the biceps tendon and the insertion of the pectoralis tendon on the humeral anterior shaft. Make a notch on the surgical neck of the shaft to mark this anterior fin position when the prosthesis is in the proper retroversion (Figures 21a and b).



**Figure 21a**  
Notch or mark at  
the anterior fin.



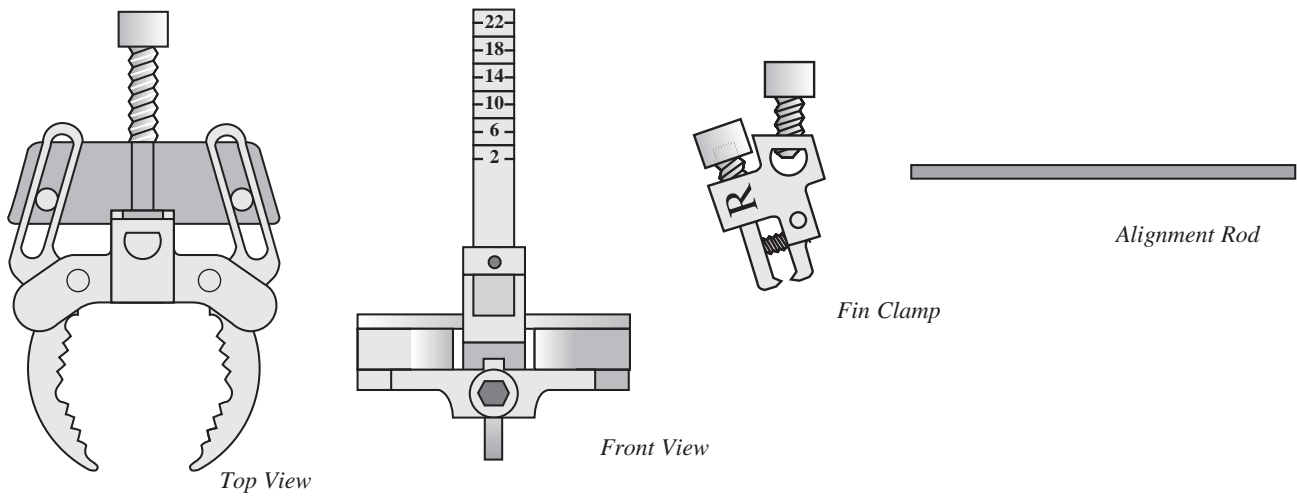
**Figure 21b**  
Rotate the prosthesis  
posteriorly to face the glenoid.

GLOBAL FX POSITIONING JIG

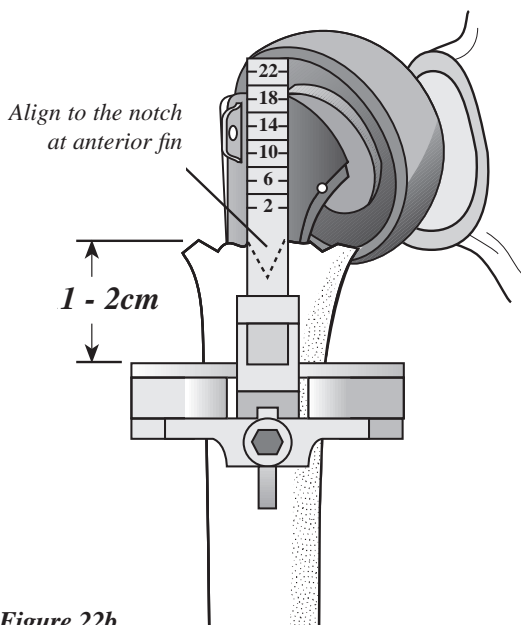
Use the Global Fx Positioning Jig to hold the prosthesis at the selected height and retroversion during trial reduction (Figure 22a). Attach the

humeral shaft clamp approximately 1 to 2cm distal to the surgical neck fracture of the shaft. Align the vertical height gauge to the anterior fin of the trial prosthesis, which was previously marked

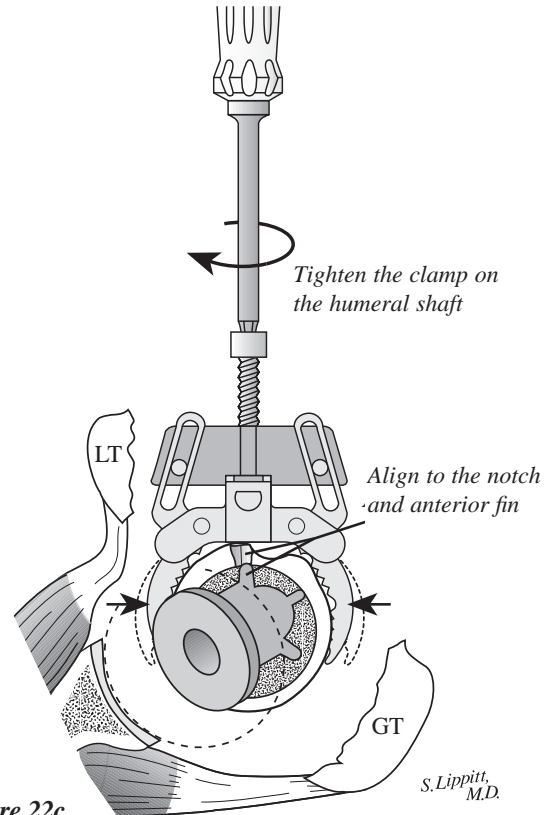
by the notch on the shaft (Figure 22b). Once the trial prosthesis is properly aligned, secure the Positioning Jig to the proximal humerus by tightening the anterior screw (Figure 22c).



**Figure 22a**  
The Global Fx Positioning Jig consists of a humeral shaft clamp and a connecting fin clamp.



**Figure 22b**



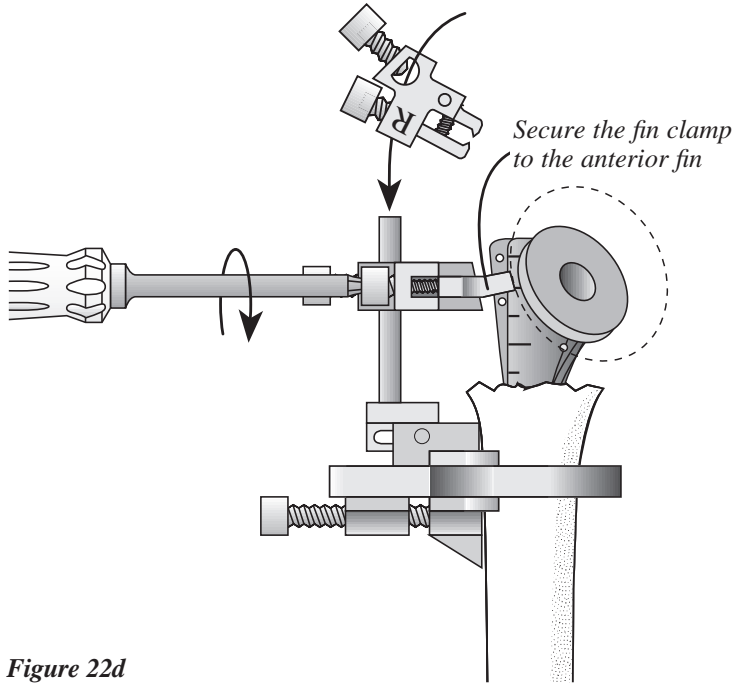
**Figure 22c**

**FIN CLAMP ATTACHMENT**

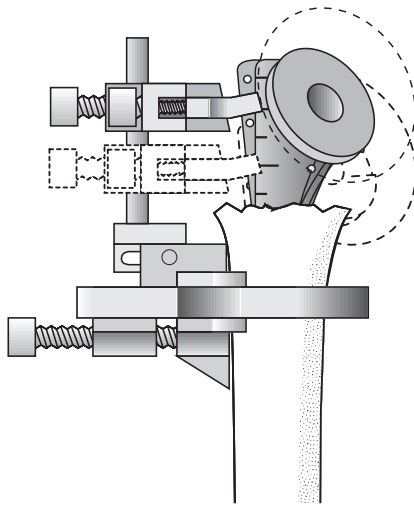
Place the fin clamp (as oriented for the right or left shoulder) over the vertical height gauge of the humeral shaft clamp.

Secure the fin clamp to the center of the three holes in the anterior fin of the prosthesis by tightening the appropriate screw (Figures 22d and e). Place the prosthesis at the appropriate height in

relation to the shaft as previously determined by the 5mm markings on the prosthesis body (Figure 19d, pg. 15). Tighten the fin clamp to the vertical height gauge (Figures 22f and g).

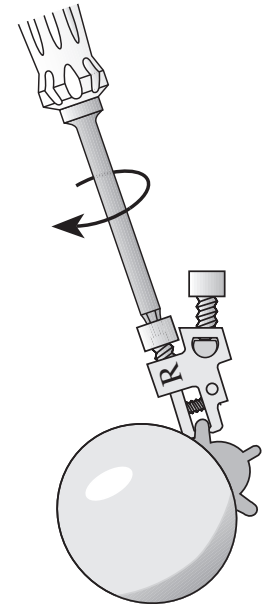


**Figure 22d**  
Slide the fin clamp over the vertical height gauge

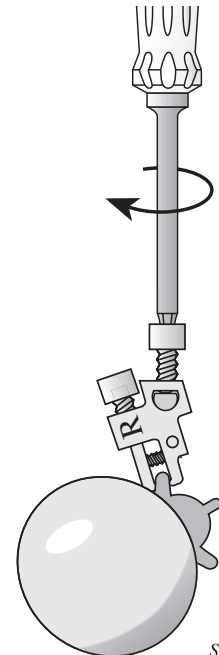


**Figure 22f**

Secure the fin clamp to the anterior fin



**Figure 22e**  
Tighten the fin clamp to the anterior fin.



**Figure 22g**  
Tighten the fin clamp to the vertical height gauge.

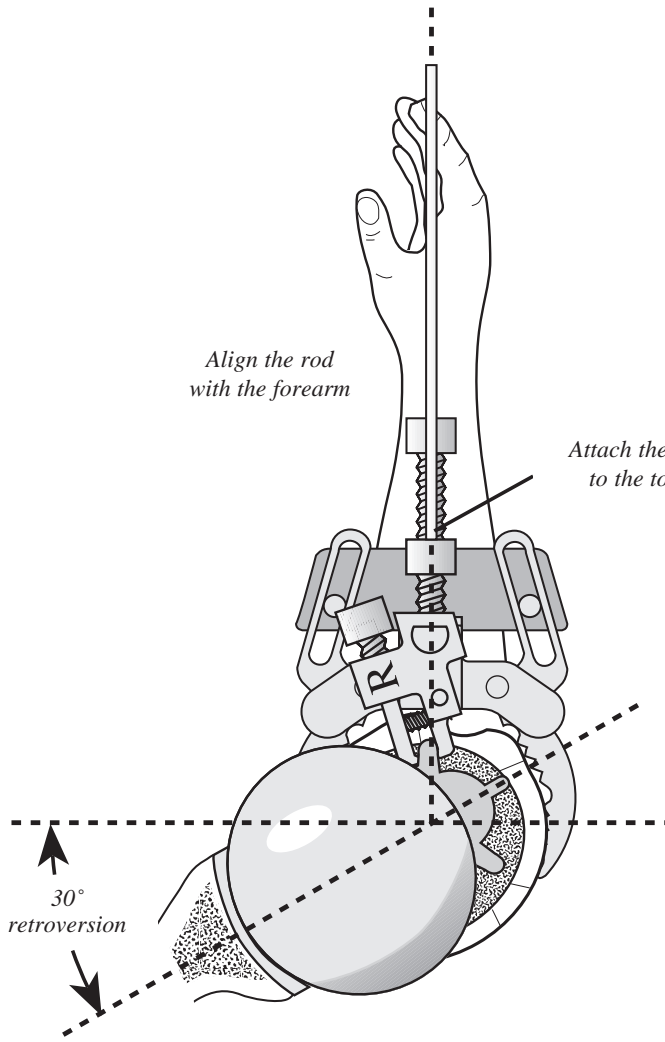
*S. Lippitt, M.D.*

**ADJUSTING HUMERAL RETROVERSION**

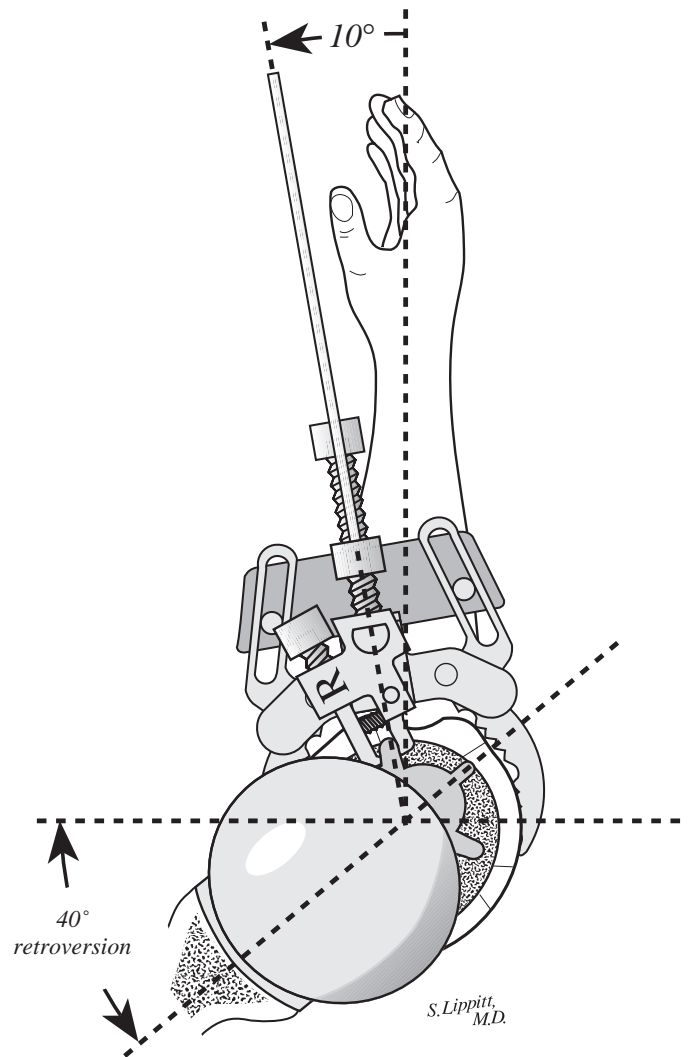
An Alignment Rod may be attached to the Global Fx Positioning Jig. If this rod is aligned with the forearm, the humeral

prosthesis will automatically be in 30 degrees of retroversion (Figure 23a). Loosen the Positioning Jig on the shaft and internally rotate it to increase retroversion or rotate the jig externally to

decrease retroversion. For example, if 40 degrees of humeral retroversion is desired, internally rotate the jig 10 degrees (Figure 23b).



**Figure 23a**



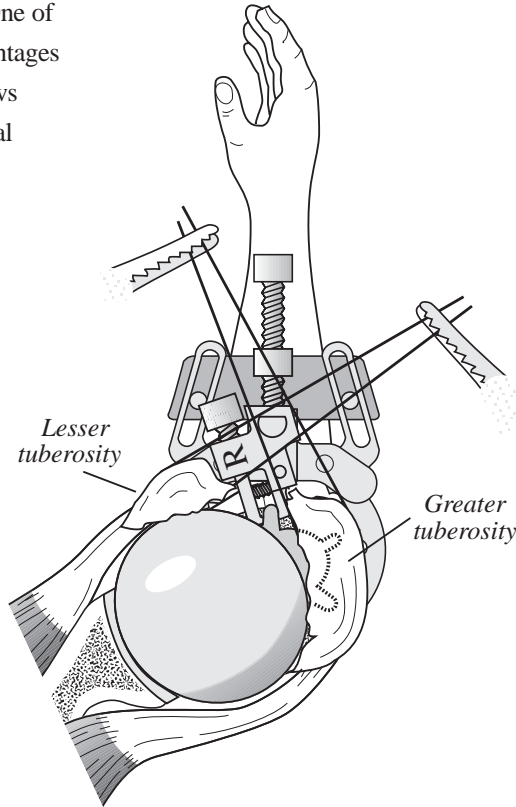
**Figure 23b**  
Ten degrees internal rotation of the jig on the shaft in relation to the forearm results in 40 degrees of retroversion.

*TRIAL REDUCTION*

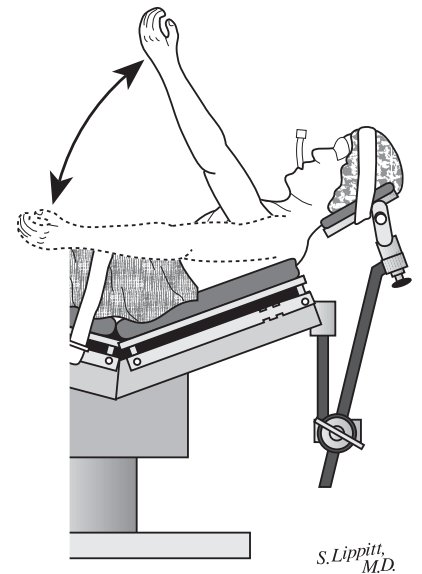
The Positioning Jig holds the prosthesis securely enough to perform trial reduction (Figure 24a) and test the range of motion and stability (Figures 24b and c). One of the most important alignment advantages of the Positioning Jig is that it allows range of motion testing with the trial

prosthesis in place. During range of motion testing, the prosthesis should remain in the glenoid fossa and the head

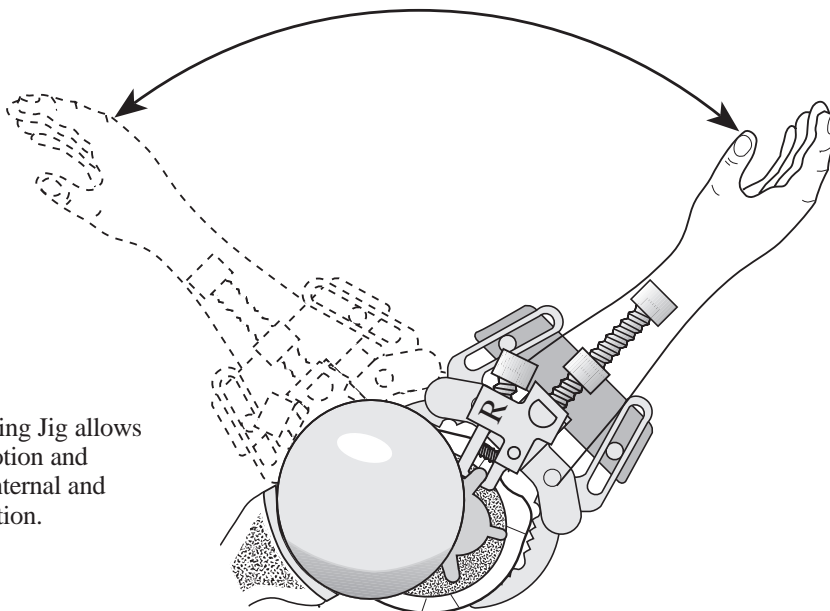
should not ride high in the glenoid. Motion should be free and easy without undue tightness.



**Figure 24a**  
Reduce the tuberosities around the Positioning Jig.



**Figure 24c**  
The Positioning Jig allows testing of motion in forward elevation.



**Figure 24b**  
The Positioning Jig allows testing of motion and stability in internal and external rotation.

TRIAL REDUCTION OF TUBEROSITIES AROUND THE TRIAL PROSTHESIS

After determining and marking the proper height and rotation of the trial prosthesis using the fins and height lines,

remove the jig and check the tuberosities again to see if they can be approximated around the prosthesis to one another and to the shaft (Figure 25a). Use reduction forceps or a towel clip to hold the

tuberosities reduced around the prosthesis (Figure 25b). Check soft tissue tensioning by performing a gentle range of motion exercise.

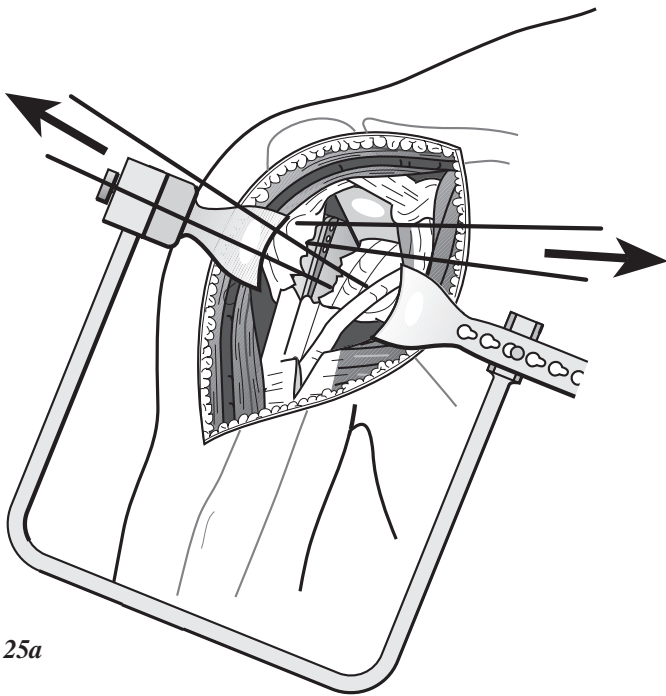


Figure 25a

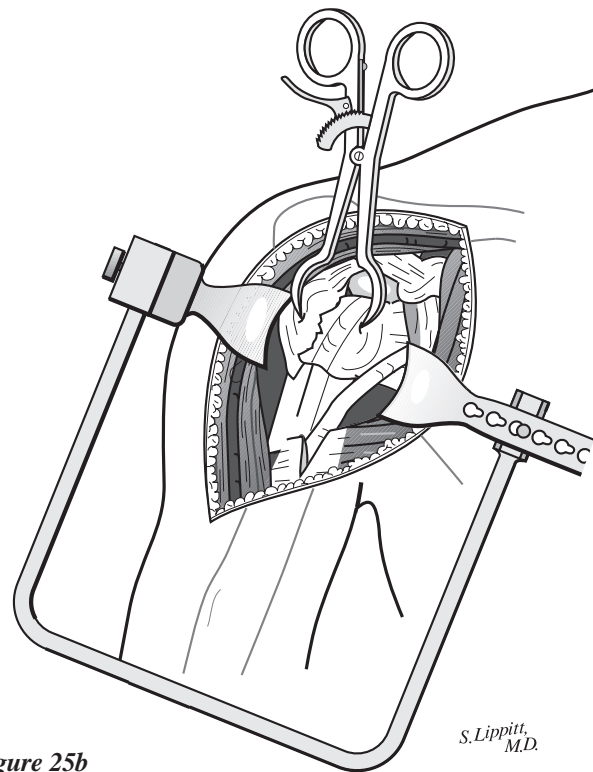


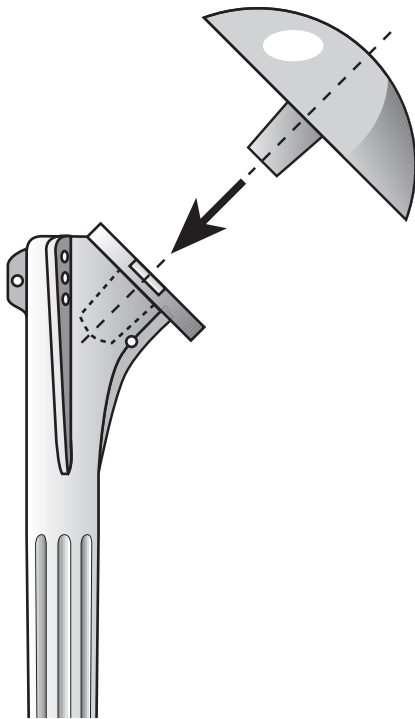
Figure 25b

S. Lippitt, M.D.

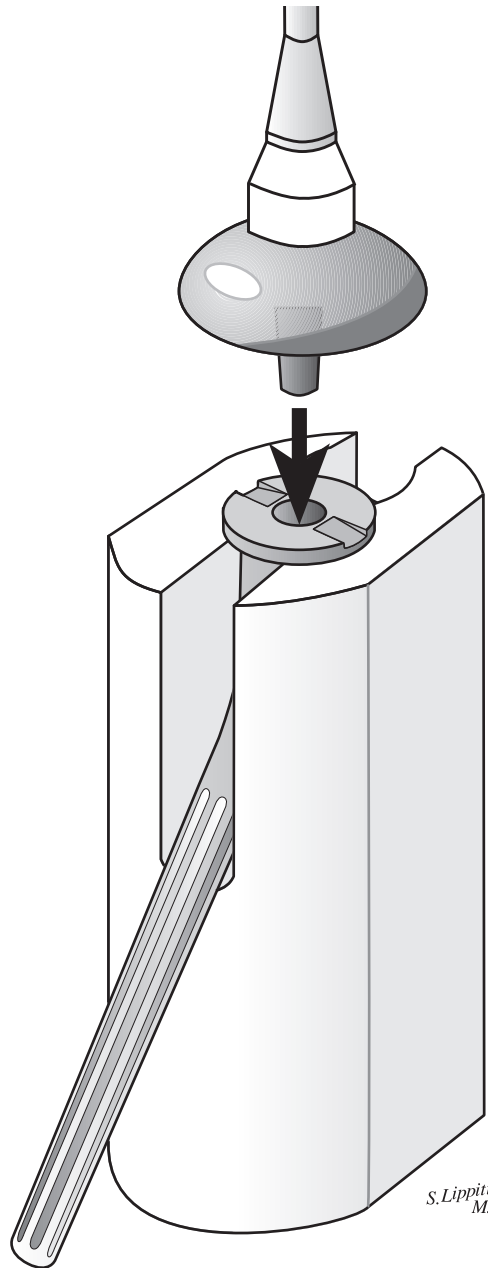
MODULAR PROSTHESIS  
ASSEMBLY

Place the Morse taper of the humeral head component on the humeral stem (Figure 26a). Place the stem in the assembly stand. Impact the humeral

head component coaxial to the Morse taper to help ensure proper stability (Figure 26b). Make three to four blows with a two-pound mallet to secure the Morse taper.



*Figure 26a*



*S. Lippitt,  
M.D.*

*Figure 26b*



SHAFT PREPARATION  
TECHNIQUE FOR TUBEROSITY  
FIXATION

Drill holes in the proximal humeral shaft anterior medial, anterior lateral and direct anterior (Figure 27a). Use one or two heavy nonabsorbable sutures, such as 1mm cotton Dacron tapes, passed in

and out of these holes to anchor the tuberosities back to the humeral shaft (Figure 27b). Use the Dacron suture in the anterior medial holes to secure the lesser tuberosity; the suture in the lateral holes to secure the greater tuberosity and the suture in the anterior holes to secure both tuberosities to the shaft (Figure 27b).

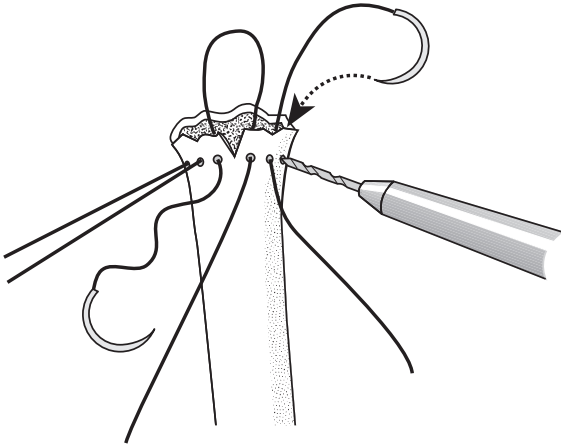


Figure 27a

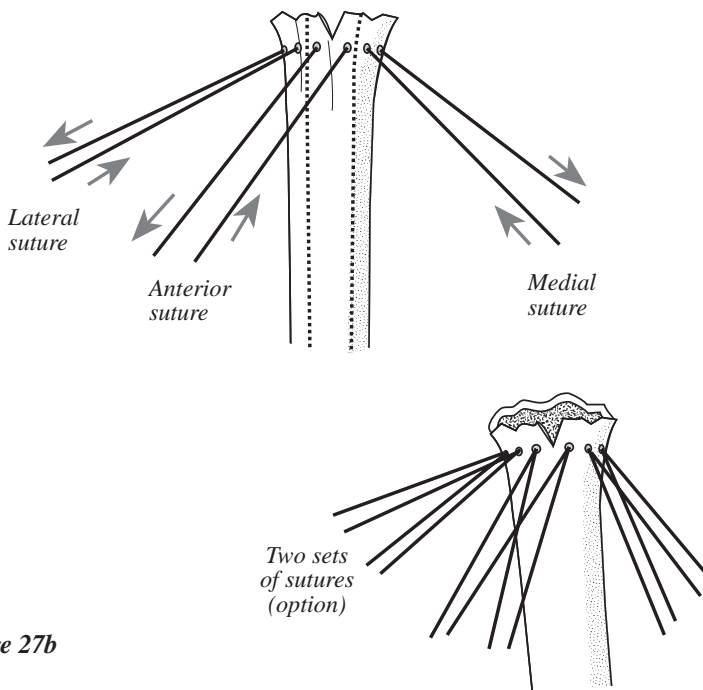


Figure 27b

CEMENTING THE PROSTHESIS

Thoroughly irrigate the medullary canal to remove blood and other debris. Use a small, loose fitting piece of cancellous bone from the humeral head or **BIOSTOP® G Resorbable Cement Restrictor** to help prevent excess cement from extending down to the elbow.

Insert a vent tube down the medullary canal and push either a medium or high viscosity DePuy bone cement down into the upper humerus with finger pressure. The use of pressurized cement is not necessary and its use may produce a shaft fracture when the prosthesis is inserted (Figure 27c).

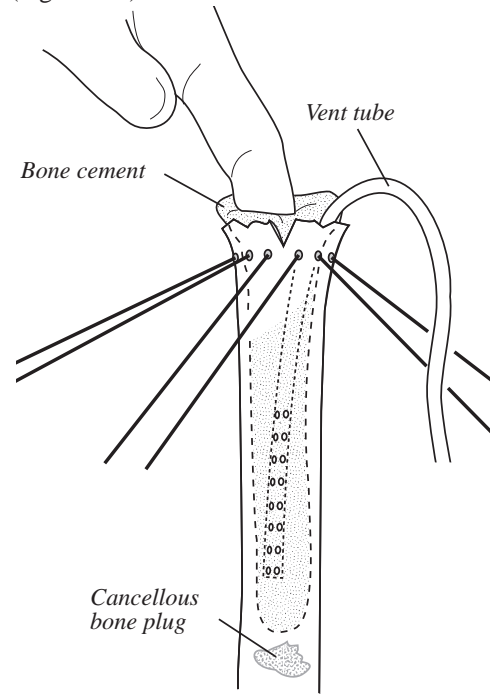


Figure 27c

S. Lippitt,  
M.D.

REMOVING EXCESS CEMENT

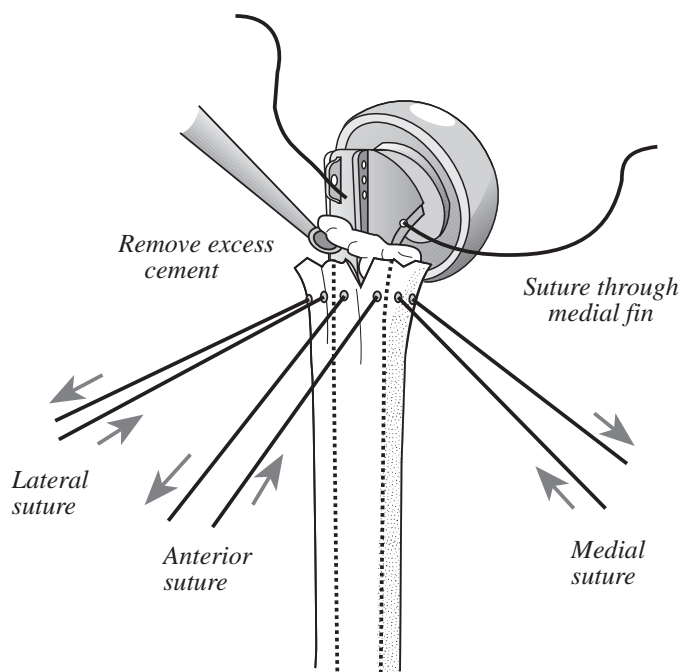
Insert the final stem by hand pressure and hold it at the proper height and version previously determined. Before the PMMA cement is set, remove the excess cement to just below the humeral shaft to allow room for placement of the cancellous bone graft (Figure 27d). Pull the sutures back and forth to keep them mobile. Pass a strand or two of 1mm

Dacron tape through the hole in the medial fin. It will be used to pass around both tuberosities to help fixate them to the shaft and to each other.

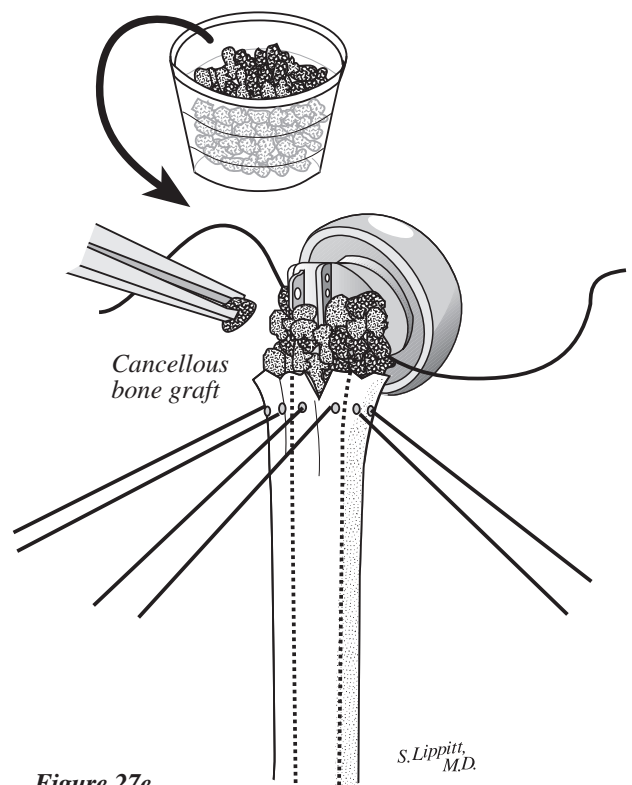
When seating the final prosthesis into cement, make sure it is at the same height out of the canal as in the trial and that the anterior fin is lined up with the humeral notch. If the trial measured 25mm out of the shaft, then the final prosthesis must be at the same position.

BONE GRAFT BETWEEN THE PROSTHESIS COLLAR AND THE HUMERAL SHAFT

When the cement is set, place the autologous cancellous bone graft from the humeral head in the interval anteriorly and posteriorly between the humeral upper shaft and the prosthesis collar (Figure 27e). This additional graft helps ensure the healing of the tuberosities to the shaft and to each other. Note that the anterior fin is lined up with the notch in the upper shaft.



**Figure 27d**  
Remove the excess bone cement at the shaft.



**Figure 27e**  
Place the cancellous bone graft around the prosthetic collar and the humeral shaft.

REATTACHING THE GREATER AND LESSER TUBEROSITIES TO THE PROXIMAL HUMERAL SHAFT

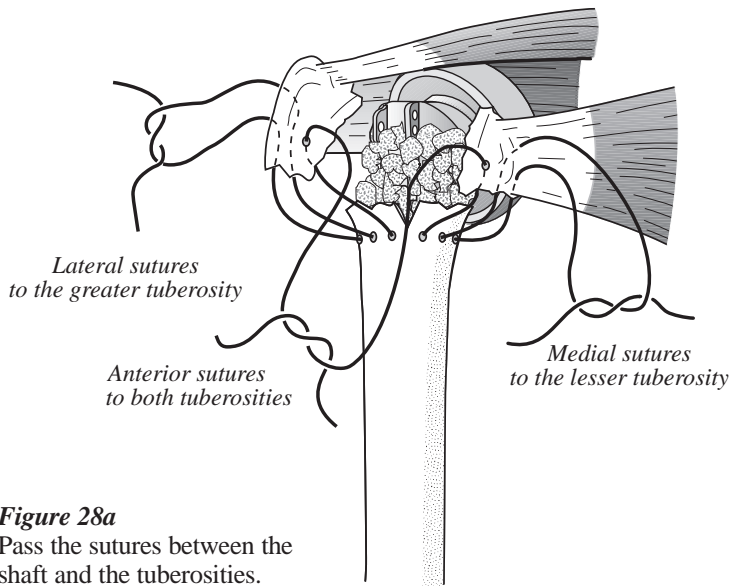
*SUTURES FROM THE SHAFT TO THE TUBEROSITIES*

Pass the lateral two sutures of the shaft through or around the greater tuberosity. Pass the medial two sutures through or

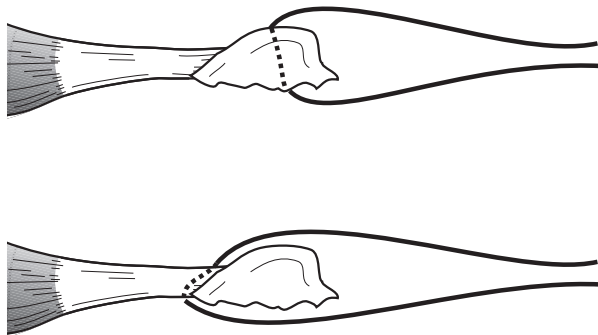
around the lesser tuberosity and the anterior two sutures through or around both the greater and lesser tuberosities respectively (Figure 28a). Since the sutures may pull through the tuberosity fragment in osteoporotic bone, place sutures around the tuberosity fragment and through the cuff tendons (Figure 28b).

*SUTURES BETWEEN THE TUBEROSITIES AND THROUGH THE ANTERIOR FIN*

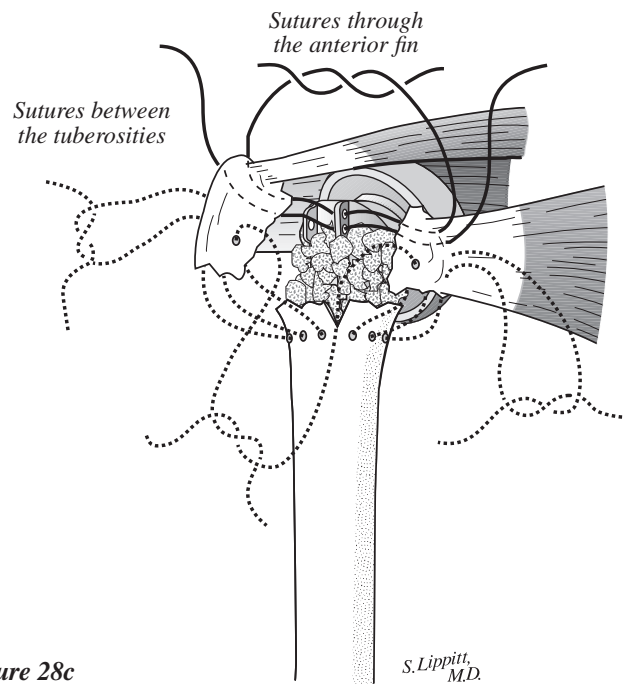
For additional fixation, pass sutures between the greater and lesser tuberosities (Figure 28c). These sutures may be anchored to the anterior fin through the fin holes. **It is important to repair the tuberosities to the shaft and to each other in their normal anatomical position, which is anterior—in line with the anterior fin of the prosthesis.**



**Figure 28a**  
Pass the sutures between the shaft and the tuberosities.



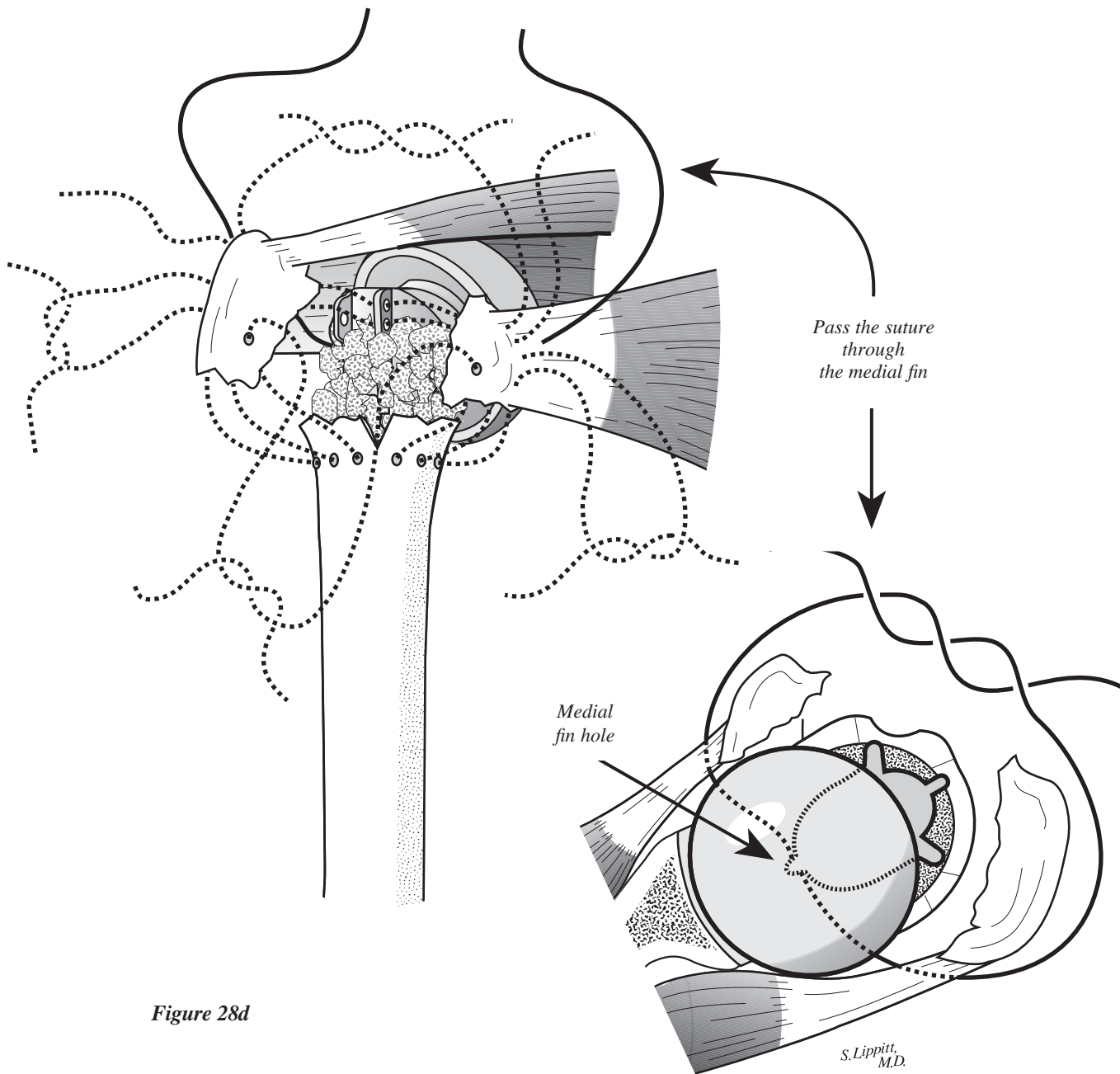
**Figure 28b**  
For better fixation, pass the sutures around the tuberosity and through the tendon instead of through bone only.



**Figure 28c**  
Pass the sutures between the greater and lesser tuberosities and the anterior fin.

*SUTURES FROM THE MEDIAL  
FIN AROUND BOTH  
TUBEROSITIES*

For additional stability, pass one or two of the heavy, nonabsorbable 1mm tapes through the medial fin around both the greater and lesser tuberosities (Figure 28d).



*Figure 28d*

TYING THE SUTURE FIXATION

To help repair the tuberosities to each other, use a towel clip to hold them together while tying the sutures (Figure 29a). It is important to place sufficiently heavy sutures between the tuberosities

and the shaft and between the tuberosities to obtain firm fixation. Arm rotation and simultaneous movement of the tuberosities with the shaft should be possible, allowing early postoperative rehabilitation.

ROTATOR INTERVAL CLOSURE AND LONG HEAD BICEPS TENODESIS

Close the rotator interval between the subscapularis and the supraspinatus tendons. If tenodesis of the biceps is anticipated, release the proximal segment from the glenoid and excise it (Figure 29b). Otherwise, a decrease in the shoulder's range of motion should be noted.

Stabilize the tendon in the interval between the repaired lesser and greater tuberosities and incorporate it into the closure of the interval between the subscapularis and supraspinatus tendons.

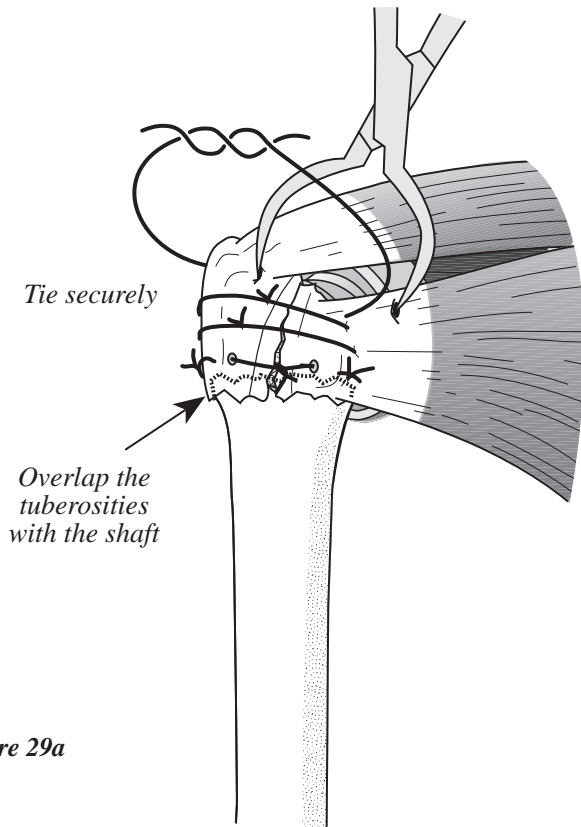


Figure 29a

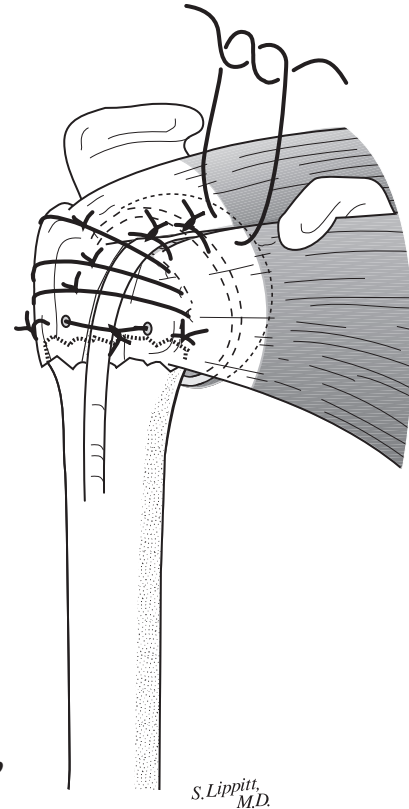


Figure 29b

IMPORTANCE OF REPAIRING THE TUBEROSITIES IN RELATIONSHIP TO THE ANTERIOR FIN

The Global Fx prosthesis has an anterior fin, which should be lined up with the old bicipital groove (Figure 30a). The repair of the two tuberosities together at this anterior fin landmark assures the proper restoration of the tuberosities to

the humerus (Figure 30b). Anatomically repair the lesser tuberosity medial to the groove and the greater tuberosity lateral to this groove. This anatomical repair of the tuberosities allows for normal external rotation without restriction (Figure 30c).

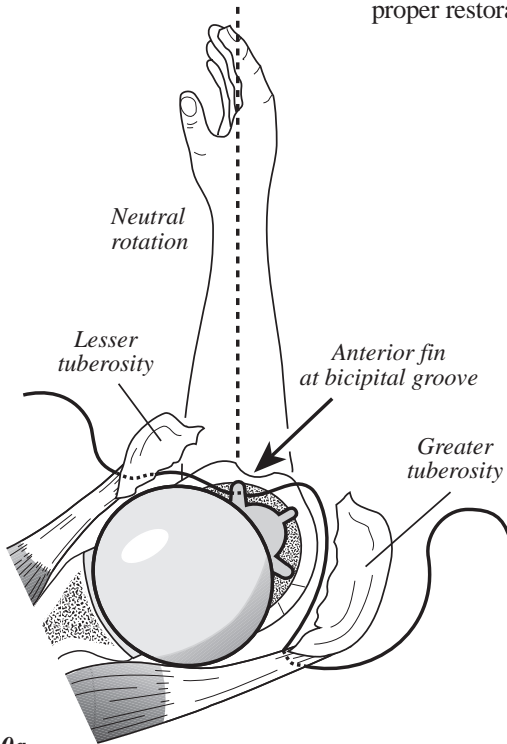


Figure 30a

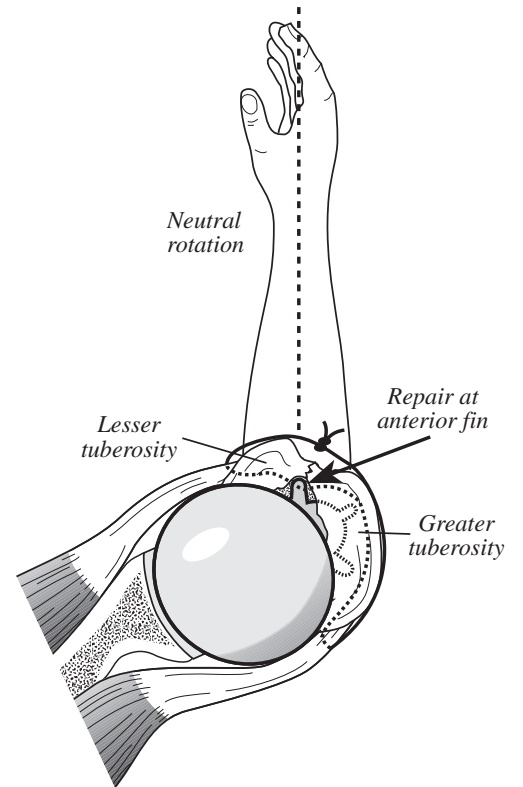


Figure 30b

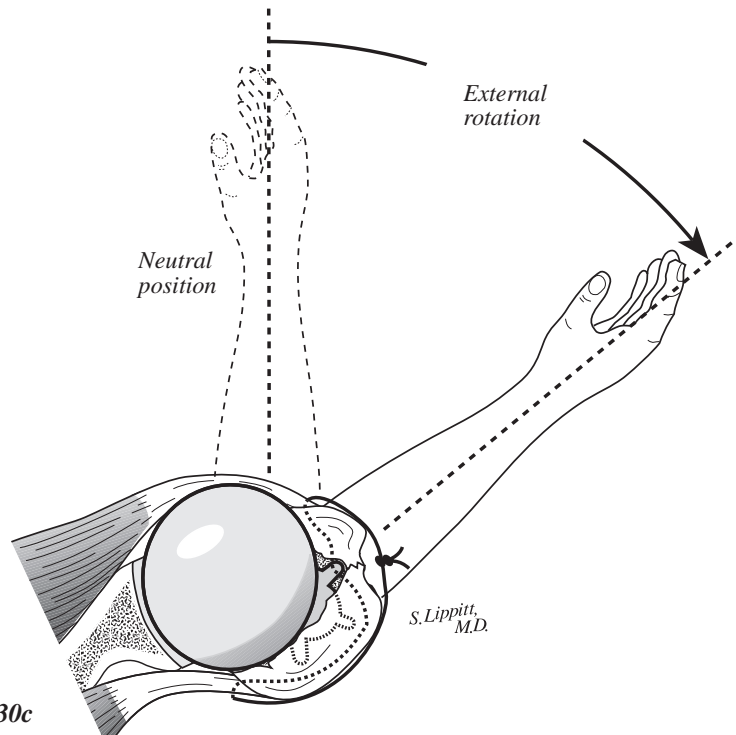


Figure 30c

EXTERNAL ROTATION PROBLEM WHEN REPAIRING TUBEROSITIES TO THE LATERAL FIN

The lateral fin of the prosthesis is often advocated as the reference for repairing the tuberosities (Figures 31a), which means that the arm must be internally

rotated to repair the lesser tuberosity (Figure 31b). Repairing the tuberosities to the lateral fin causes the lesser tuberosity and the subscapularis tendon to be under excessive tension, which restricts external rotation (Figure 31c).

Similarly, the greater tuberosity and rotator cuff are not under enough tension, which results in nonanatomical restoration of the tuberosities and the overall loss of shoulder motion.

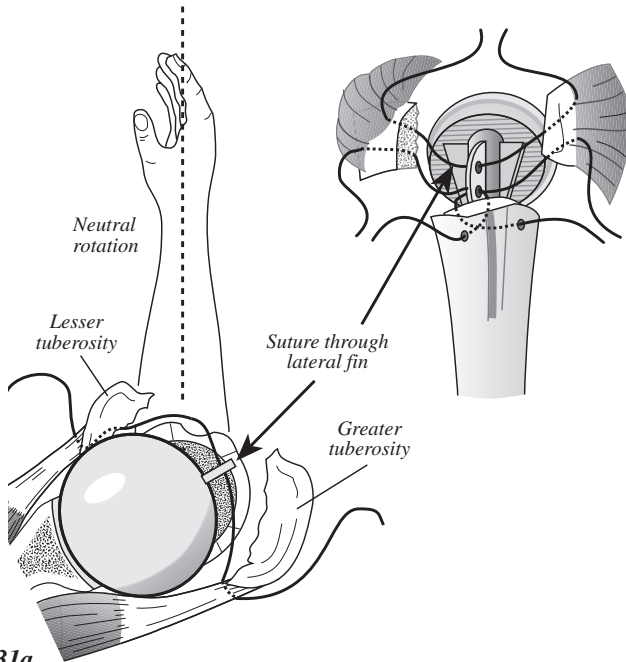


Figure 31a

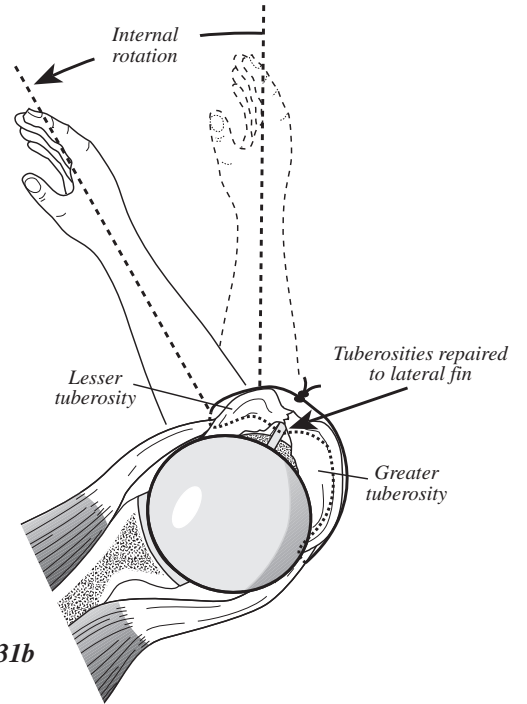


Figure 31b

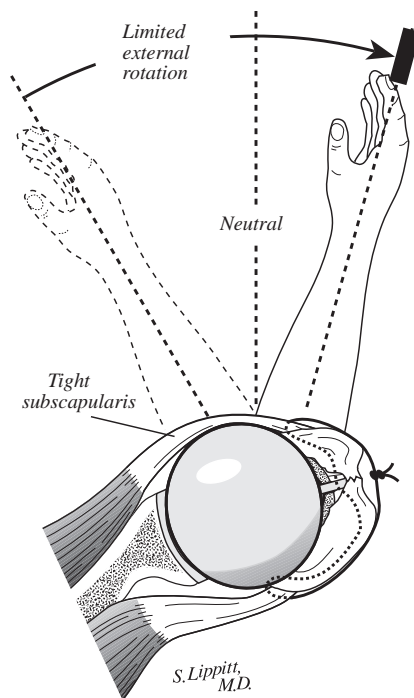


Figure 31c

S. Lippitt, M.D.

WOUND CLOSURE

Thoroughly irrigate the wound with an antibiotic solution. Use a portable wound evacuation unit, such as the Seprer® Closed Wound Drainage System, to prevent formation of a postoperative hematoma. Infiltrate the soft tissues with 0.25 percent Marcaine solution, which helps reduce immediate postoperative pain and facilitates passive shoulder motion on the same day as surgery (Figure 32).

One option for wound closure is using a 2.0 Vicryl in the deep subcutaneous layer, closing the skin with a running subcuticular nylon suture (Figure 33). If the post-traumatic skin is swollen and ecchymotic, interrupted skin sutures or skin clips may be preferred.

After the dressing and shoulder immobilizer are in place, use a shoulder ice wrap, such as the Dura\*Kold® Compression Ice Wrap System. Place the prefrozen ice wrap on the shoulder in the operating room and replace it with another unit every three hours. The combination of local anesthetic infiltration with Marcaine and immediate cooling from the ice wrap markedly helps reduce postoperative pain.

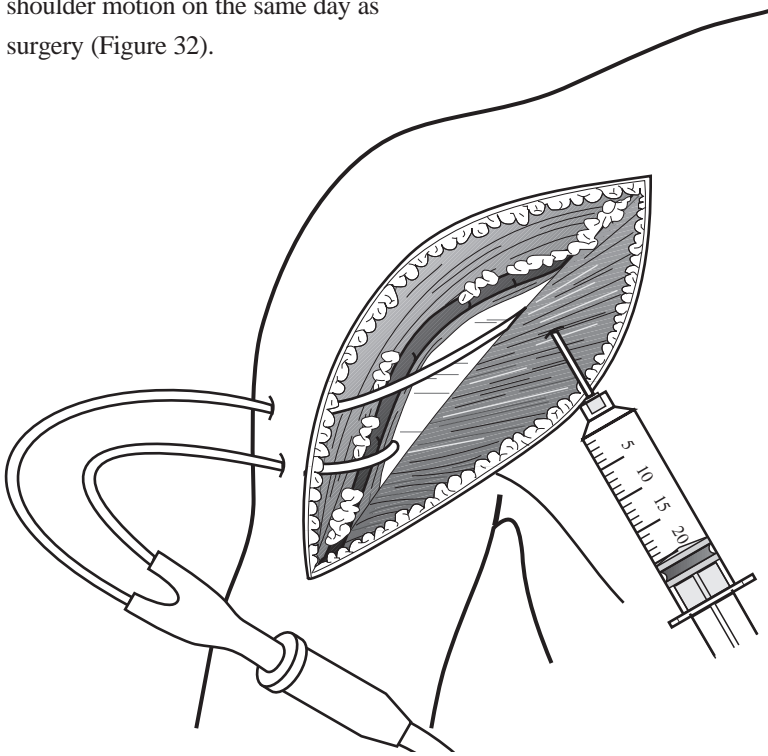


Figure 32

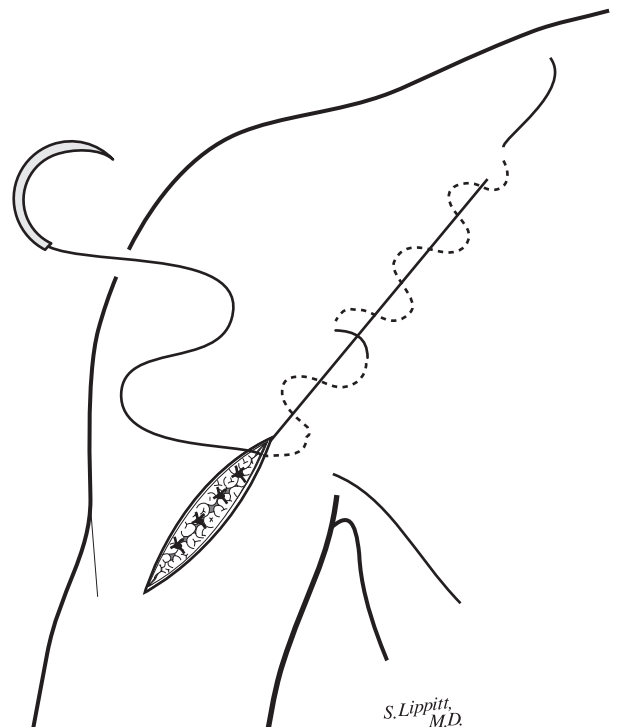


Figure 33

S. Lippitt, M.D.

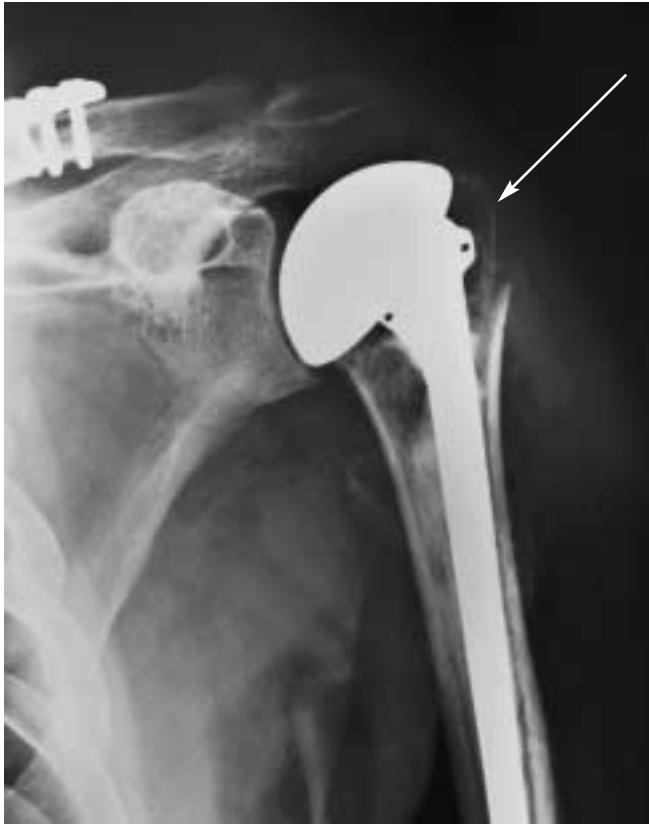



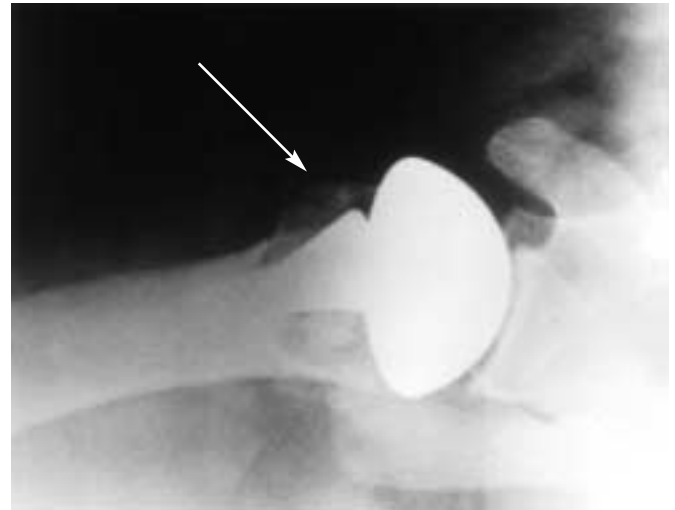




# Global Fx - *THE* Shoulder Fracture System



Postoperative Anterior/Posterior View  
Note the position of the greater tuberosity.



Postoperative Axillary/Lateral View  
Note the position of the lesser tuberosity.

Caution: Federal Law (USA) restricts this device to sale by or on the order of a physician.

Dura\*Kold® is a trademark of Dura\*Kold Corporation.



**DePuy Orthopaedics, Inc.**  
700 Orthopaedic Drive  
Warsaw, IN 46580  
USA  
Tel: +1 (800) 366 8143  
Fax: +1 (219) 267 7196

**DePuy International Ltd**  
St Anthony's Road  
Leeds LS11 8DT  
England  
Tel: +44 (113) 270 0461  
Fax: +44 (113) 272 4101

9M300  
0601-39-050

Printed in USA.  
© 1999 DePuy Orthopaedics, Inc. All rights reserved.