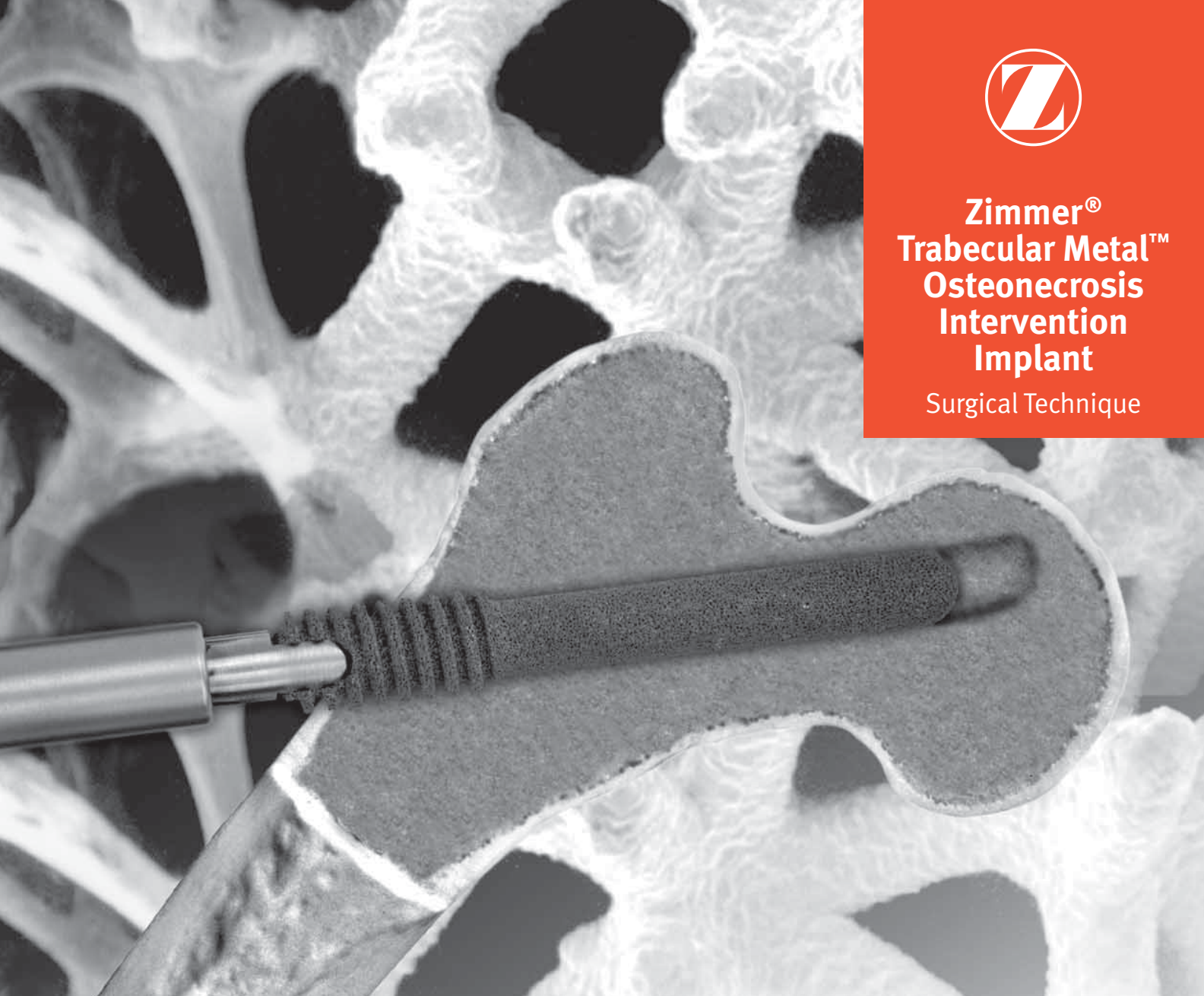




**Zimmer®
Trabecular Metal™
Osteonecrosis
Intervention
Implant**

Surgical Technique



The Best Thing Next To Bone™



Preoperative Planning

Using radiographic techniques, ensure there is no collapse of the femoral head articulating surface and reconfirm Stage I or II osteonecrosis (MRI or CT is suggested for confirmation of the stage and size of the lesion). The surgical templates should be used to plan location of the core tract and estimate length of the implant.

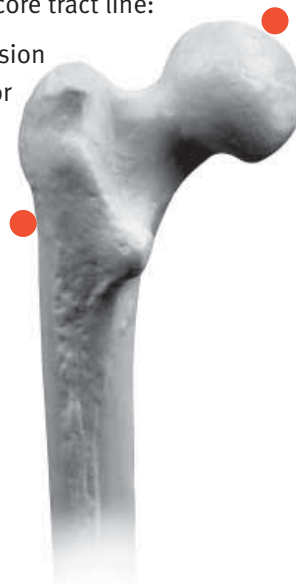To assure proper location of the core tract, placement of the guide pin, and position of the implant, biplane image intensification or a C-arm image intensifier should be used at each step of the procedure. The position of the guide wire should be checked frequently using an image intensifier (fluoroscopy) to prevent unintended guide wire advancement and penetration into the surrounding tissues. Do not re-use guide wires.

1 Identify Core Tract

Expose the lateral femoral cortex in the normal manner. Two points define the core tract line:

- The center of the necrotic lesion
- A point immediately superior to the lesser trochanter

The point corresponding to the lesser trochanter defines the thick-to-thin cortical bone transition. The final core tract diameter will be 10mm for acceptance of the implant.



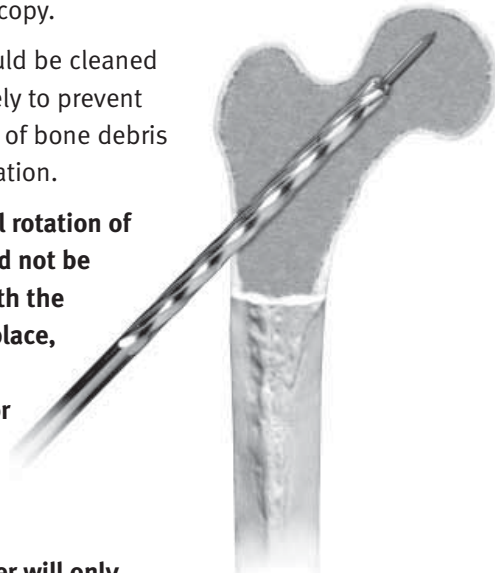
3 Ream

With the guide pin in place, use the cannulated reamers to progressively ream the core to 8mm and then 9mm under fluoroscopy.

Reamers should be cleaned intraoperatively to prevent accumulation of bone debris in the cannulation.

Note: External rotation of the hip should not be performed with the guide pin in place, as this may deform and/or bend the guide pin.

Note: 8mm Starter Reamer will only ream to a depth of 50mm.



4 Obtain Biopsy (optional)

If desired, obtain the biopsy when reaming has progressed to the region of necrotic bone, before penetration or removal of the necrotic region.

Obtain the biopsy using a standard coring/ biopsy instrument (typically 6mm or 7mm).

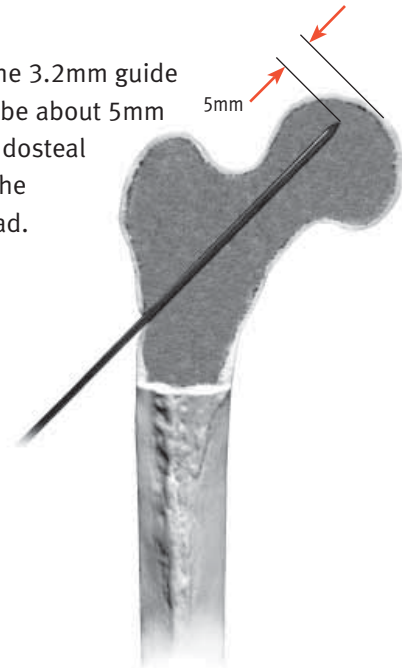
2 Insert Guide Pin

Hold the hip in 10-15° of internal rotation to neutralize the normal anteversion of the neck. Identify the midcoronal plane of the lateral femur. Use the 3.2mm guide pin to mark the entry point. (A Guide Pin Punch is also available.)

Note: Because of the anteversion of the femoral neck, the entry point in the lateral metaphysis must not be anterior to the midcoronal plane. The guide pin should be centered within the femoral neck in both planes and relative to the subchondral plate and necrotic lesion.

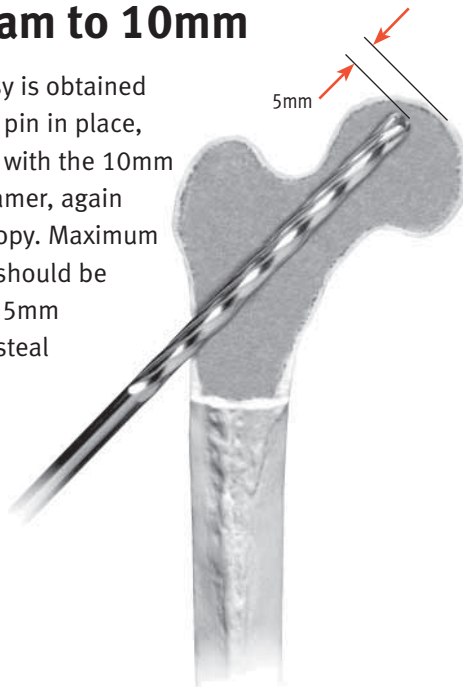
Note: An initial depth measurement may be obtained at this point.

The tip of the 3.2mm guide pin should be about 5mm from the endosteal surface of the femoral head.



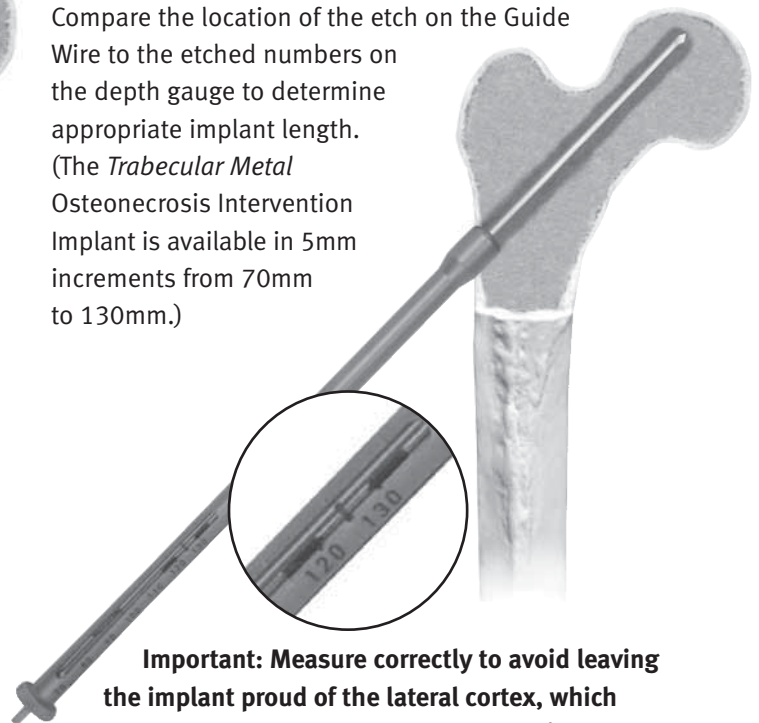
5 Ream to 10mm

After the biopsy is obtained with the guide pin in place, finish reaming with the 10mm cannulated reamer, again using fluoroscopy. Maximum reamer depth should be approximately 5mm from the endosteal surface of the femoral head.



6 Measure

Slide the Cannulated Depth Gauge over the Guide Pin until the bulbous end rests in the reamed hole. Compare the location of the etch on the Guide Wire to the etched numbers on the depth gauge to determine appropriate implant length. (The *Trabecular Metal Osteonecrosis Intervention Implant* is available in 5mm increments from 70mm to 130mm.)



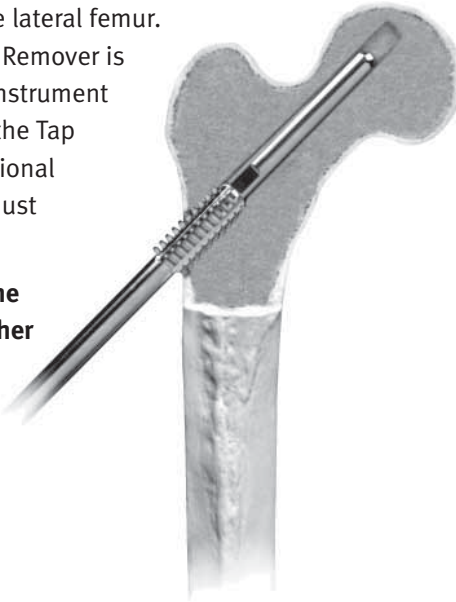
Important: Measure correctly to avoid leaving the implant proud of the lateral cortex, which could result in abrasion of soft tissue and/or pain.

7 Tap

Fully thread the corresponding length Tap Extension/ Provisional into the end of the Tap. Attach the ratchet T-handle. Insert the assembly into the lateral cortex, turning it clockwise to form the threads. All threads of the appropriate length Tap should be completely seated within the lateral femur.

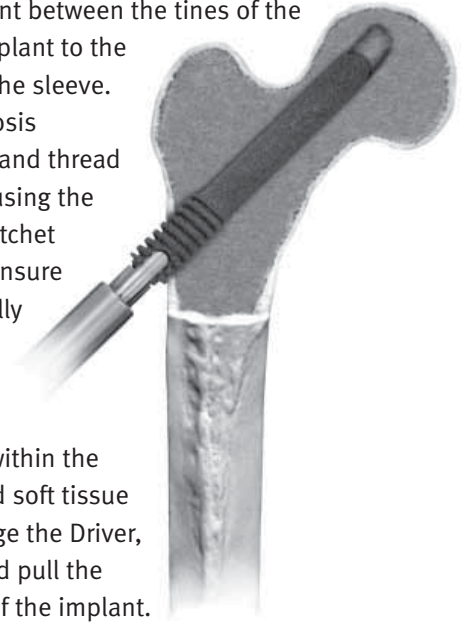
(A Tap Extension Remover is included in the Instrument Set in the event the Tap Extension/Provisional unthreads and must be removed.)

Note: Use only the Tap provided. Other taps do not have the same thread geometry as the implant.



8 Insert Implant

Attach the implant to the Driver by sliding the flat sections of the implant between the tines of the Driver. Secure the implant to the Driver by tightening the sleeve. Insert the Osteonecrosis Intervention Implant and thread it into final position using the Implant Driver and ratchet T-handle assembly. Ensure that the implant is fully seated. The lateral end of the implant should be flush or slightly recessed within the lateral cortex to avoid soft tissue irritation. To disengage the Driver, loosen the sleeve and pull the Driver from the end of the implant.



Important: If excessive resistance is encountered in seating the implant, remove the implant. Assure the bone threads are tapped to the proper depth and the core tract is free of bone debris. Verify proper alignment of the driver to the axis of the implant. Reinsert implant. Excessive torquing of the implant can lead to damage or breakage of the implant.

Please refer to package insert for complete product information, including contraindications, warnings, precautions and adverse effects.

Contact your Zimmer representative or visit us at www.zimmer.com