



# CLS<sup>®</sup> Spotorno<sup>®</sup> Hip Stem

Surgical Technique



Nature as Model

**Disclaimer**

This document is intended exclusively for experts in the field, i.e. physicians in particular, and is expressly not for the information of laypersons.

The information on the products and/or procedures contained in this document is of a general nature and does not represent medical advice or recommendations. Since this information does not constitute any diagnostic or therapeutic statement with regard to any individual medical case, individual examination and advising of the respective patient are absolutely necessary and are not replaced by this document in whole or in part.

The information contained in this document was gathered and compiled by medical experts and qualified Zimmer employees to the best of their knowledge. The greatest care was taken to ensure the accuracy and ease of understanding of the information used and presented. Zimmer does not assume any liability, however, for the up-to-dateness, accuracy, completeness or quality of the information and excludes any liability for tangible or intangible losses that may be caused by the use of this information.

In the event that this document could be construed as an offer at any time, such offer shall not be binding in any event and shall require subsequent confirmation in writing.

## **Surgical Technique CLS Spotorno Stem**

Developed in cooperation with  
**Prof. Lorenzo Spotorno**  
Finale Ligure, It

## **Table of Contents**

<b>CLS Spotorno Stem</b>	<b>4</b>
<b>Indications for the CLS Spotorno Stem</b>	<b>5</b>
<b>Preoperative Planning</b>	<b>10</b>
<b>Surgical Technique</b>	<b>12</b>
<b>Case Study</b>	<b>21</b>
<b>Ordering Information</b>	<b>22</b>

## CLS Spotorno Stem

### The Press-Fit Principle

With the *CLS* stem, the primary stability is obtained through the press-fit principle. The precondition for the functioning of this principle is the way in which the two components oppose one another.

In order to guarantee the stability of the interaction between them, the opposing surfaces of the bone and the prosthesis must be highly congruent, which is only possible with a linear design. The *CLS* stem, with its three-dimensional taper, is pressed into the tough-elastic implant space in the cortico-cancellous bone of the metaphysis, which has been prepared with slightly smaller dimensions. For this reason, the author has carefully developed a rasp system that makes the surgical procedure reproducible.

The tapered shape of the stem guarantees remarkable primary stability and ensures that this stability is maintained thanks to the self-stabilizing properties of the implant. In addition, the structure of the bone surrounding the prosthesis shows that the tapered shape of the implant favours a largely proximal transfer of load.

### The Offset Versions

As the CCD angle is not a constant value, and shows broad variability in individuals, the *CLS* stem now offers three different CCD angles. This provides a wide range of offset options, which allows an adequate restoration of the biomechanical parameters, such as the center of rotation, the CCD angle as well as leg length and soft tissue balancing.

For implantation of the *CLS* 145°, the *CLS* 135° and the *CLS* 125°, the same instruments and the same surgical technique are used. The modular rasps and trial necks serve the intraoperative trial reduction.



## Indications for the CLS Spotorno Stem

### A Guideline by Prof. Lorenzo Spotorno

#### The Question: Cemented or Uncemented?

The decision between a cemented and an uncemented hip stem is a choice that must be made by the surgeon. Based on the personal experience by the designing surgeon implanting over 9,000 *CLS* stems, it was possible to carry out extensive research into the indications for this stem as well as to define its limitations.

The results obtained with the *CLS* stem since 1984 are extremely encouraging. For a number of years, we have seen a broadening of the range of indications in favour of uncemented stems, both in primary and revision surgery. Even though excellent results have been achieved (even under critical conditions), it is still recommended that surgeons use a set of standard, reliable criteria to help make the decision between cemented and uncemented stems.



## Reliable Decision-Making Through Methodology

In 1985, an indication protocol was established that is based on the assessment of four clinical and radiological parameters in the patient investigated. Each parameter is given a point score. The final value obtained from the sum of the points establishes the indication and thus, provides a valuable guideline for the surgeon. The parameters are age, gender, severity of the osteoporosis and the anatomical characteristics of the femur.

### Parameter No. 1: Age

As far as skeletal changes are concerned, it is generally known that age cannot be considered as a purely chronological parameter, but has to be assessed from a biological point of view. In simple terms, it can be said that for patients under the age of 50 years, a cementless stem is the routine solution, while after the age of 70, a cemented stem is generally preferred.

#### Points Allocated

>70 years:	<b>4</b> points
61–70 years:	<b>2</b> points
51–60 years:	<b>1</b> point
<50 years:	<b>0</b> points

### Parameter No. 2: Gender

Due to the increasing osteoporosis resulting from the hormonal changes occurring during menopause, older women generally have poorer bone quality.

#### Points Allocated

Women:	<b>1</b> point
Men:	<b>0</b> points

### Parameter No. 3: Osteoporosis

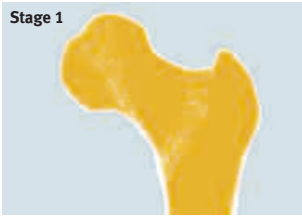Severe osteoporosis represents a major disadvantage in regard to the primary stability of the implant, or requires the use of an over-dimensioned stem with anchorage in the lower metaphyseal and diaphyseal region. This, in turn, has a negative effect on the blood supply to the bone. Radiological methods such as computer tomography and densitometry are available for the assessment of the severity of the osteoporosis. A suitable method for a conclusive assessment is the modified analysis of the trabeculae in the neck of the femur according to Singh – a process that is easy to carry out.

#### Femoral Neck Index

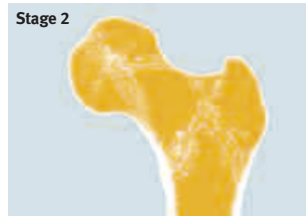On the basis of these assessments, four degrees of severity of osteoporosis can be defined:

Severe (Singh 1–2):	<b>4</b> points
Moderate (Singh 3–4):	<b>2</b> points
Slight (Singh 5–6):	<b>1</b> point
Physiological (Singh 7):	<b>0</b> points

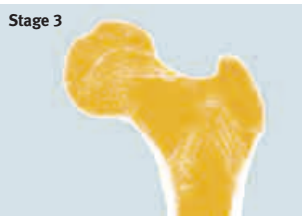(Singh M. et al. *Changes in Trabecular Pattern of the Upper End of the Femur as an Index of Osteoporosis. Journal of Bone and Joint Surgery 52A: 456, 1970*).



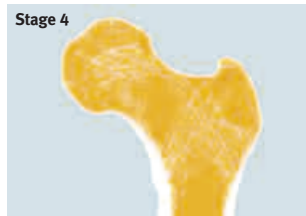**Stage 1**  
The bundle of bow-shaped trabeculae is missing. The pressure trajectories in the head of the femur have partly disappeared.



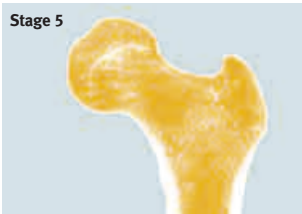**Stage 2**  
The bow-shaped trajectories have almost completely disappeared.



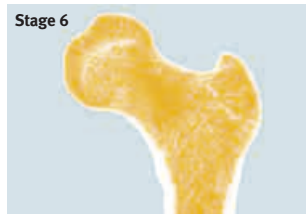**Stage 3**  
Partial disappearance of the bow-shaped trabecular system.



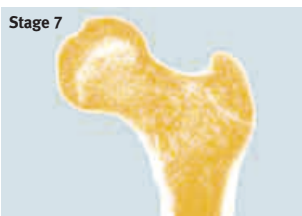**Stage 4**  
The accessory trabecular systems have completely disappeared.



**Stage 5**  
Empty Ward's triangle. The accessory trabecular systems have partly disappeared.



**Stage 6**  
The picture of the upper triangle of the femoral neck appears to be bound by the bow-shaped bundle of trajectories of the head of the femur and the trochanter.



**Stage 7**  
Normal small, dense trabeculae fill the neck of the femur. Trajectories are not visible.

## Parameter No. 4: The Anatomy of the Femur

### Morpho-Cortical Index

Experience shows that this index provides more information parameters. It comprises two variables, which do not always correlate with one another, in one single value:

- The morphology of the femur
- The thickness of the cortex

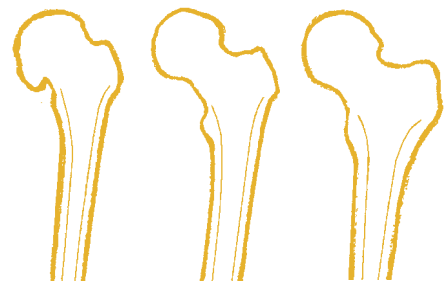
In regard to morphology, it is possible to differentiate between three types of femurs:

- Trumpet shape
- Cylinder shape
- Dysplastic femur

Because of its morphology, the trumpet-shaped femur provides the ideal conditions for an uncemented implant.

The cylindrical femur requires an adequate cut in the subtrochanteric region and the removal of metaphyseal bone during the rasping process. The mechanically supportive cancellous bone and the cortex of the isthmus of the calcar, which forms the basis for the anchorage of the stem, have to be partly removed.

The morpho-cortical index (MCI), is defined on a standard X ray picture. It is calculated from the correlation of the extracortical diameter of the femur, measured at the medial tip of the lesser trochanter, to the intracortical diameter, measured 7 cm further in the distal direction.



dysplastic

cylindrical

trumpet-shaped

(Singh M. et al. Changes in Trabecular Pattern of the Upper End of the Femur as an Index of Osteoporosis. Journal of Bone and Joint Surgery 52A:456, 1970).

The MCI is calculated using the following formula:

$$\text{MCI} = \frac{\text{CD}}{\text{AB}}$$

**CD** = Distance between the outer boundaries of the lateral and the medial cortex. The measurement is made at the level of the tip of the trochanter, vertical to the axis of the femur.

**AB** = Diameter of the medullary cavity. The measurement is made 7 cm distal from the CD line, vertical to the axis of the femur.

The MCI in this absolute form can only be used if it was calculated in a standard X ray picture with the legs in the normal 0 position and with rectilinear a-p irradiation.

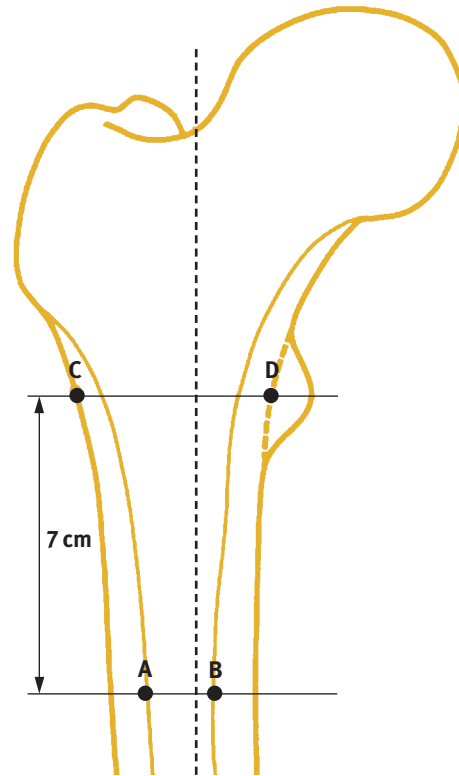
The pointscores of the MCI

MCI ≤ 2.2: 4 points

MCI > 2.3: 2 points

MCI > 2.7: 1 point

MCI ≥ 3.0: 0 points



$$\text{Calculation MCI} = \frac{\text{CD}}{\text{AB}}$$

### Final Assessment

In cases where long-term cortisone therapy is envisioned, for example in rheumatoid arthritis, one point must be added as an additional risk factor.

0–4 points: cementless stem

5 points: questionable indication

≥6 points: cemented stem



## Conclusion: There is a Broad Indication for Uncemented Anchorage

The uncemented stem in general, and the *CLS* stem in particular, have definitively proven their worth. In comparison with the cemented stem, the uncemented solution is far more bone conserving. This becomes an important factor if revision surgery is necessary.

The insertion of the uncemented stem is less invasive and takes the biomechanics of the femur into account. The bone and the prosthesis combine to form a unit. As a result, the blood supply and vitality of the bone are maintained.

In principle, the uncemented stem is preferably used in younger patients. It is, however, not contraindicated in the elderly – especially for patients in poor general health. It can be implanted more rapidly and there is no thermal damage to the tissue due to the cement.

The use of a cemented stem is nevertheless justified in elderly patients for a number of reasons:

The life expectancy of the patient is often shorter than the average survival time of a cemented stem. In the presence of poor bone quality, the cement allows unproblematic correction of defects. With cementing, faster restoration of the ability to walk is also to be expected, since – at least within certain limits – it does not involve the reparative phase, which, in the case of the cementless stem, leads to the definitive anchorage of the bone. Finally, the economic factor plays a role that is not to be underestimated.

It can generally be said that if one adheres to the classical indications – while still allowing the possibility of further indications in the future – good and very good results can be obtained. In this respect, the use of the MCI is of fundamental importance because it follows the basic biomechanical ideas used in the design of the *CLS* prosthesis. It has been proven that the *CLS* can be readily combined with the trumpet-shaped femur. In contrast, with a cylindrical medullary cavity, it is normally necessary to use a more invasive prosthesis, which has an unfavourable bone-prosthesis interaction.

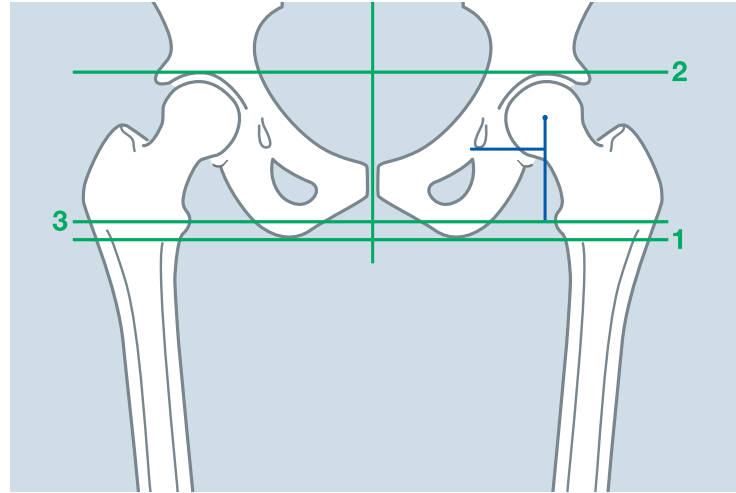
Comparison has shown that the MCI and the cortical index (CI) after Gruen are good indicators for the quality of the bone. There seems to be a connection both between the CI and the MCI and between the MCI and the measurement of the mineral content of the bone by the DEXA method.

## Preoperative Planning

### Systematic Preparation with Suitable Methods of Measurement and Practical Planning Benefit Correct Implantation

Within the framework of the preoperative planning, the stem size, the optimal anchorage of the stem in the medullary cavity and the correct position of the acetabular and femoral components are determined in order to ensure equal leg length.

At the start of the preoperative planning, three lines are drawn on the X ray picture: The tangent of the two ischia forms the base line. A second line is drawn through the floors of the two acetabulae, and a third between the lesser trochanters. On the side that is not to be operated on, the center of rotation of the joint is determined. Then the distances between the joint, baseline and “teardrop” are drawn. In addition, the longitudinal axis of the pelvis is also drawn.



Equal leg length: all lines are parallel

## The Planning Steps, with an Example of Unilateral Coxarthrosis

### Determination of the Size and Position of the Cup

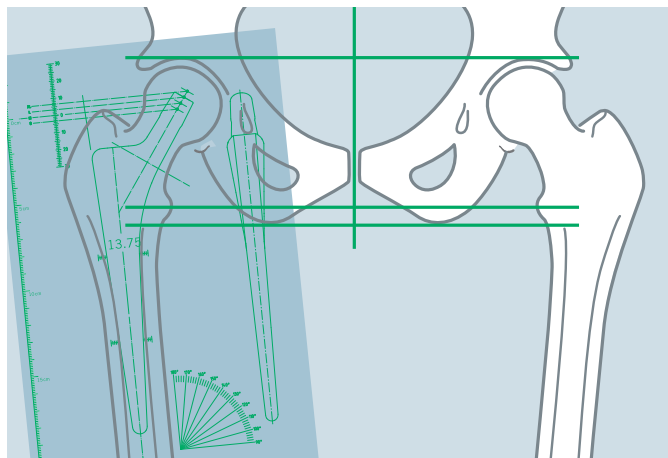
The center of rotation of the joint to be operated on is determined by transposing the two lines that have been drawn on the opposite side. The cup template is then placed on the side that is to be operated on. The position of the acetabular components is determined by the outline of the cup, the center of rotation that was determined, the level of the “teardrop” and the required abduction angle of 40°–45°.

### Drawing in of Pelvis and Cup

The tracing paper is placed on the X ray picture and the template. The longitudinal edge must run parallel to the vertical axis of the pelvis. The pelvis and the cup are drawn in and then the tracing paper removed from the X ray.

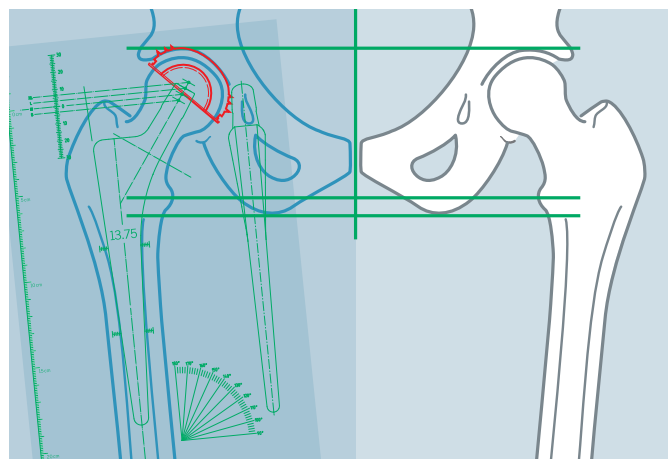
### Determination of the CCD Angle, the Size and Position of the Stem

First, the most adapted CCD angle of the CLS stem (125°, 135° or 145°) to fit into the proximal part of the femur is selected. The selected stem template is placed on the femur so that the stem fits into the medullary canal displaying the correct type of anchorage. The size of the stem must be selected so that at least  $\frac{3}{4}$  of the proximal ribbed structure is anchored in the cancellous bone. Ideally, one of the four lines from the rotation centers touches the tip of the greater trochanter.



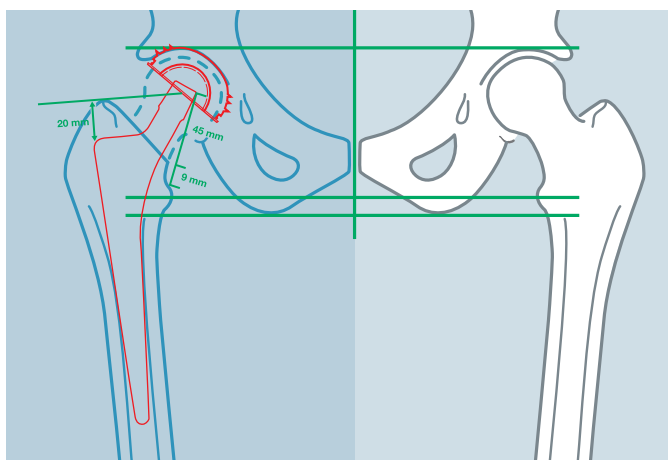
### Height of the Pelvis

The femoral template is to be left in place. The drawing of the pelvis is placed with the acetabular components on the X ray picture. If lengthening of a leg is necessary, the drawing of the pelvis lies higher than the pelvis on the X ray picture, by the difference in the length to be corrected. In the case of planned shortening of a leg, the drawing must be correspondingly lower by the distance to be corrected. Stem size and length must be selected so that the differences correspond to the measurements that are to be corrected.



### Final Result

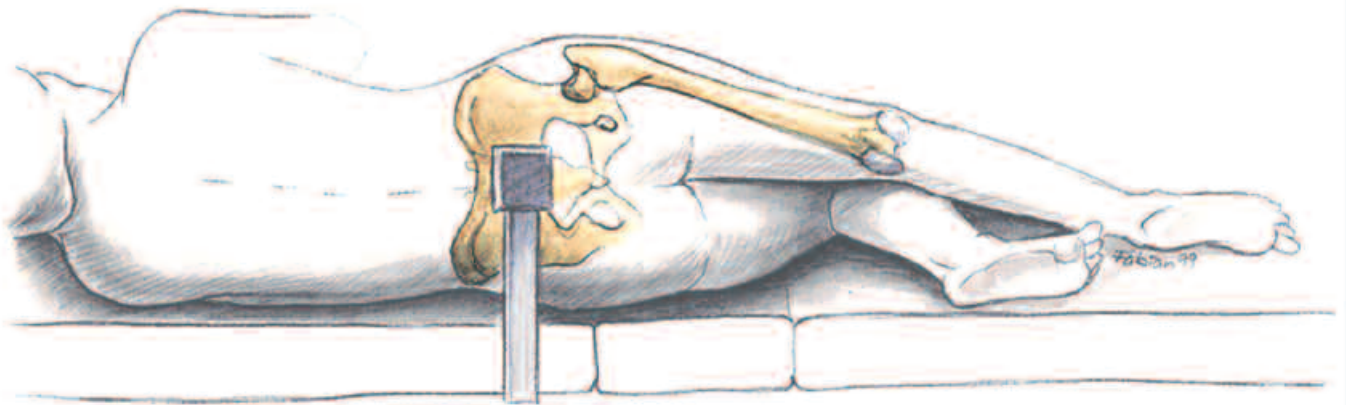
The outlines of the femur and the cortex and the selected implant/femoral head combination are drawn on the transparent paper. The distance between the proximal end of the taper of the stem and the lesser trochanter is measured and entered. The line from the shoulder of the stem to the greater trochanter is extended and measured. The line between the tip of the greater trochanter and the center of rotation is drawn in.



## Surgical Technique

### Positioning of the Patient: Placement in the Lateral Position\*

The patient is positioned on the operating table with one pressure pad on the pubic bone and one on the sacrum. In the subsequent positioning, it is important that the pelvis is not lowered, either sideways or in the caudal direction, and that it is fixed securely. The leg on the opposite side is bent 45° at the hip and 90° at the knee, which helps to stabilize the position of the patient.



\* Different surgical approaches are possible. The following describes the author's recommended approach.

### Surgical Approach to the Hip: Incision

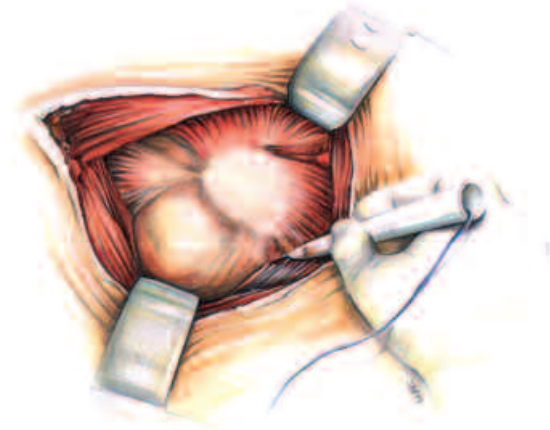
The posterolateral approach is recommended. The joint is bent at an angle between 30° and 40°. A rectilinear incision is made to the tip of the greater trochanter and is then continued for about 6 cm on the diaphysis. After transection of the subcutis, the fascia lata is exposed.



### The Approach to the Deeper Layers

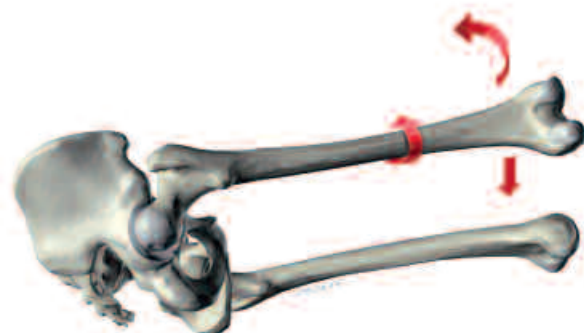
The fascia lata is incised and dissociated of the fibers of the *M. gluteus maximus* and the Charnley wound retractor is placed directly on the fascia.

In this way, the plane of the external rotator muscles and the tendon attachment of the *M. gluteus maximus* are exposed on the linea aspera of the femur. The tendon attachment is partly released in order to relax the soft parts. This favours the displacement of the femur in the ventral direction and also its internal rotation.



### Transection of the External Rotator Muscles and Dislocation of the Hip

After inserting a bent Hohmann retractor under the *M. gluteus medius*, the tendon of the *M. piriformis* is located and transected, as are some of the tendons of the external rotator muscles. The joint capsule is then opened from the dorsocranial direction. With a combined flexion, adduction and internal rotation movement, the head of the femur can now be dislocated from the acetabulum.



### Osteotomy of the Neck of the Femur

The lesser trochanter serves as reference point for the osteotomy plane on the neck of the femur, which was already included in the preoperative planning. The level of the osteotomy is influenced by the ante-torsion of the neck of the femur: the greater the ante-torsion, the lower the level of the osteotomy. Normally, it proves an advantage to retain 1 to 1.5 cm of the neck of the femur. This creates a sheath into which the proximal, ribbed part of the stem can fit.

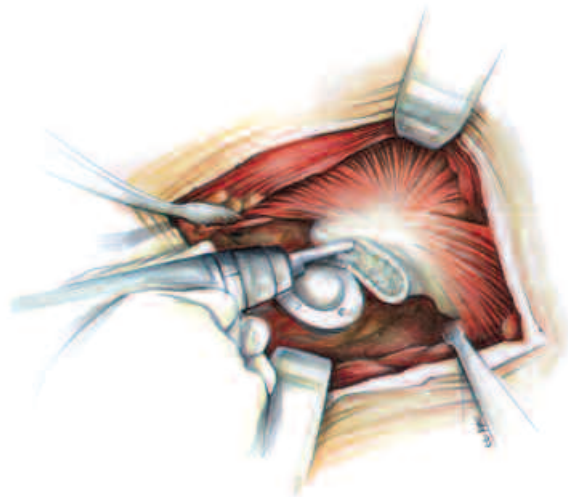
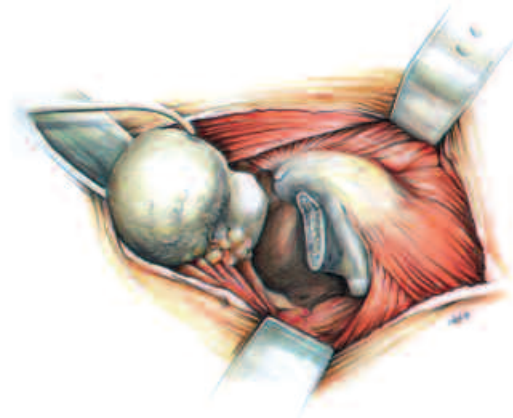
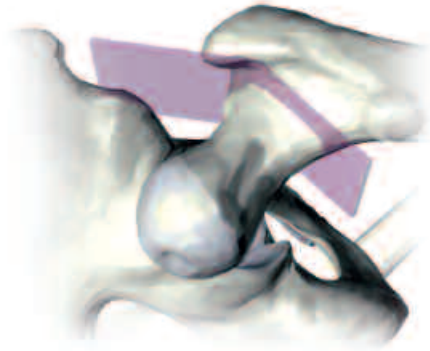
The next step is the osteotomy with the reciprocating saw. Starting from the medial mark, the upper edge of the neck of the femur is reached at the point where it rises from the mass of the trochanter. It may be necessary to continue the osteotomy with a cut continued further upwards, parallel to the axis of the femur.

### Preparation of the Medullary Cavity of the Femur

The leg is turned inwards, by internal rotation of up to 90°, which is combined with bending and adduction of the hip. The lower leg is bent at 90° to the thigh. This provides a spatial reference point, in order to be able to establish the ante-torsion of the femoral component of the prosthesis and its position parallel to the cortex.

In order to facilitate the exposure of the mass of the trochanter, a Hohmann retractor is placed under the lesser trochanter as a lever, taking care to ensure that the iliopsoas tendon is not injured. A second lever is placed at the tip of the greater trochanter in order to move the muscle to the side of the diaphysis and to expose the remaining lateral portion of the neck of the femur. This has to be removed for the correct alignment of the stem.

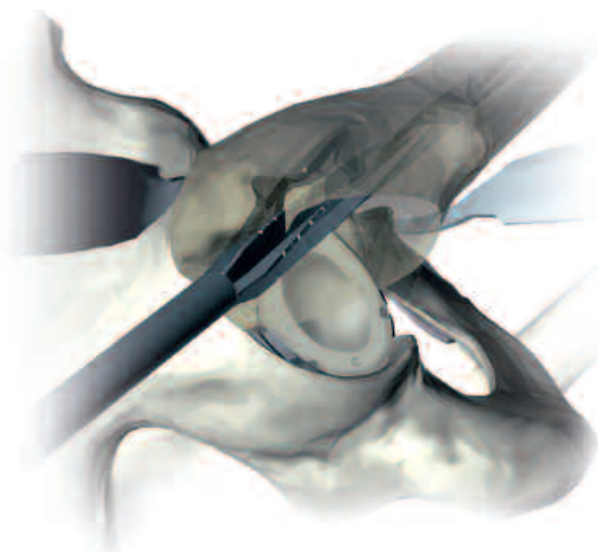
The remaining portion of the neck of the femur and a small part of the greater trochanter can be removed with the instrument provided for this purpose, or directly with the saw.



### Use of the Awl and Rasping Technique

The proximal notches on the awl mark the height of the shoulder of the implant. The awl has to be inserted laterally and slightly dorsal. The attachment of the M. piriformis provides a reference point for this. As a rule, this corresponds to the point at which, in the preoperative planning, the tangent of the endosteal edge of the outer cortex meets the greater trochanter. It provides an accurate, measurable conception of the obstacle to the prosthesis.

After the medullary space has been prepared in this way, the awl is inserted deep, for centering in the canal, taking care to ensure that it is pressed in the direction of the greater trochanter. The aim is to follow the predetermined line towards the lateral cortex, parallel to the axis of the femur and to avoid a varus deformity. The bed for the stem is now prepared, using rasps of increasing size, until the highest possible degree of stability is obtained. The preoperatively measured distance between the proximal shoulder of the prosthesis and the greater trochanter serves as orientation.



The desired stability is based on the concept of a press-fit in the cortex and cancellous bone. This is why the rasps have smooth zones for compression of the cancellous bone and cutting zones for rasping of parts of the cortex.\*

After the surgeon has established the size of the prosthesis during the planning, the definite size is determined by progressive, stepwise rasping, starting with 3 to 4 smaller rasp sizes. In this way, using the increasing dimensions, the cancellous bone is compressed. Where necessary, the cortex has to be reamed. The rasps are inserted with small, precise hammer blows, and then withdrawn.

**The final, definitive reaming must be carried out only with the rasp planned for this. The last rasp should be operated manually.**



\* The rasp is designed to lead to a defined smaller dimension in relation to the bony structure of the femur. Generally, it is underdimensioned in the proximal portion of the rasp – that is, the portion with which cancellous bone is to be compressed.

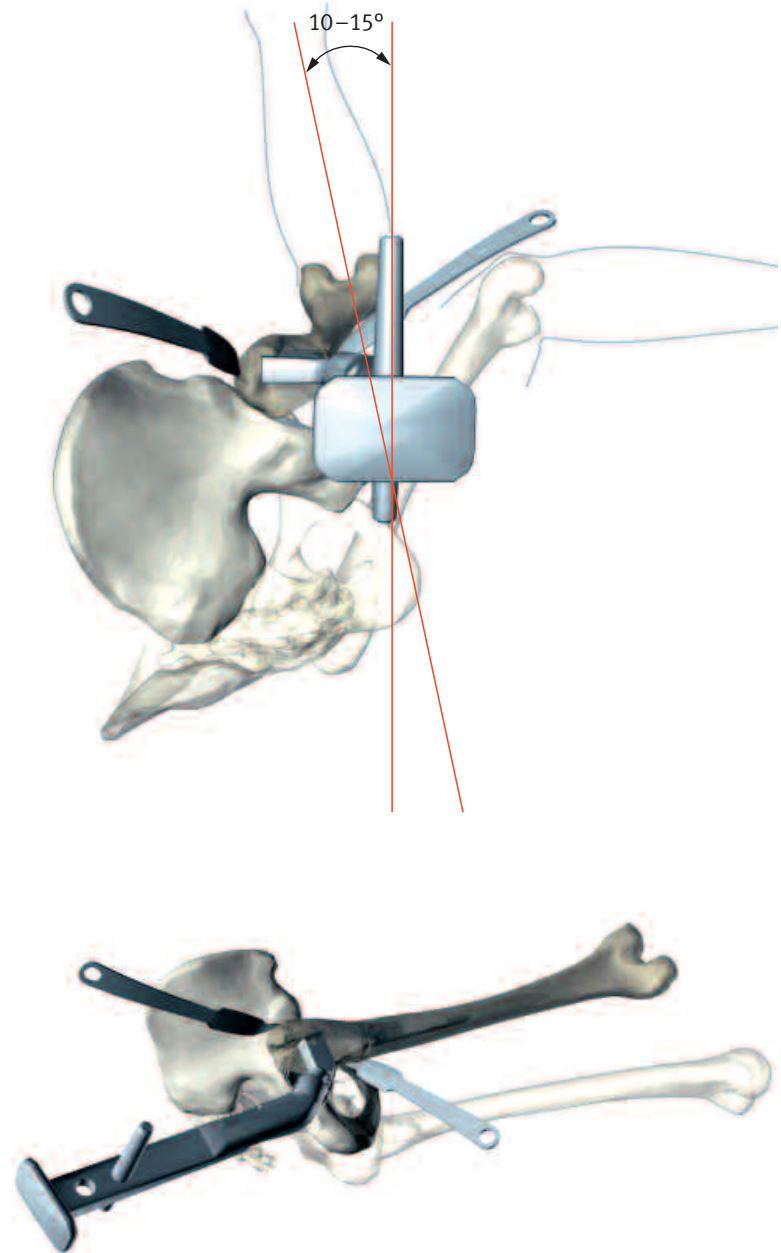
At the distal end, the rasp is slightly oversized, in order to prevent stress peaks on the end of the prosthesis.



### Rasping Technique

With the first rasp, care must be taken to ensure a correct antetorsion (10–15°). This can be monitored by means of the handle of the rasp. The neck of the femur may display a pathological antetorsion, which the surgeon has to take into account and possibly rectify. This can be done, for example, by a lower osteotomy of the neck of the femur or by controlled splitting. According to the safety margin concept, the sum of the antetorsion of the femur and the anteversion of the acetabulum must be  $25 \pm 7^\circ$ . One should, however, try to keep the angle between the two components of the prosthesis as close as possible to the physiological angle.

The reference parameter for the correct alignment of the rasp is the plane running through the axis of the diaphysis and parallel to the condyles of the femur. Keeping the angle of the bend of the lower leg at  $90^\circ$ , vertical to the floor, the rasp is turned  $15^\circ$  downwards. The ideal angle, which is formed from the lower leg and the long bar of the rasp, can be checked visually.



### Trial Repositioning with Trial Neck

Trial reduction of the *CLS* stem may be accomplished with the rasp.

This is done by removing the rasp handle and leaving the rasp in the femoral canal. A trial neck is then inserted into the rasp hole. Once the trial neck is selected, any of the trial heads may be used in conjunction with the trial neck.

For the *CLS* stem, different trial necks have to be used in order to correctly reproduce the different offset options.

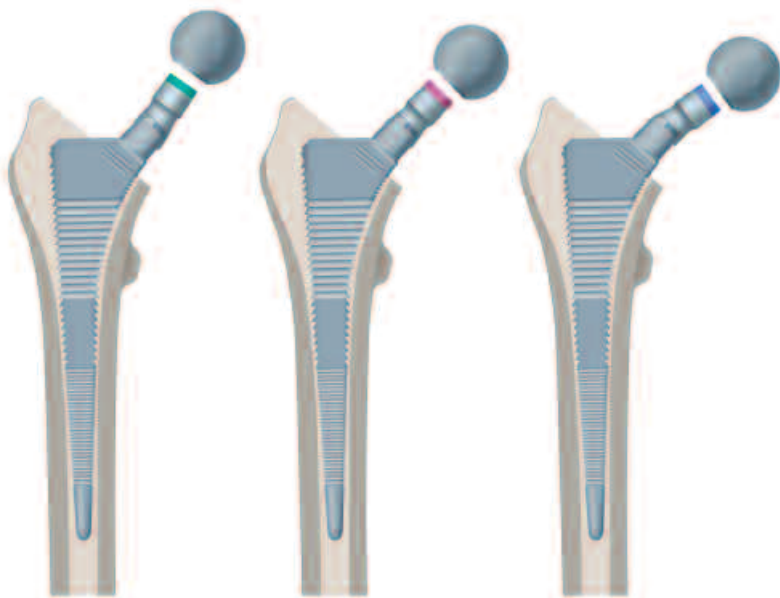
Once the trial neck and the appropriate trial head are selected, the hip is reduced. Leg length and offset are checked. This procedure is repeated as necessary, using trial heads of different lengths, until optimal offset, leg length and stability are established. A trial reduction should not allow significant push-pull or “shuck” of the joint in full extension. The range of motion is checked to avoid bony impingement and instability.

### Insertion of the Stem

After removal of the rasp, a prosthesis of the appropriate size is inserted and driven in until it is completely stable.

In this process, it is important to proceed with the necessary light touch. This is learned with experience. It should be remembered that because of the wedge mechanism, an excessive load may be exerted that can bear on the trochanter to the point that it might cause a fracture.

It is important to adjust the force of the hammer blows, according to the quality of the bone and to stop the hammer blows immediately if a change in the sound of the blows, from dull (cancellous bone) to sharp (cortex) is perceived.



### Assembly of the Femoral Head and Repositioning

After insertion of the prosthesis, the definitive femoral head is established on the basis of the measurements laid down in the preoperative planning and by trial repositioning using trial heads. The last step in the assembly is the fitting of the previously defined head onto the stem. After thoroughly cleaning and drying the taper, the femoral head is mounted with a light rotational movement and rotated further with axial force until it is firmly seated. The femoral head is seated with one light hammer blow on the head impactor in axial direction.

Upon reducing the joint, the surgeon checks the range of motion and stability of the joint. This should be checked with both internal and external rotation.

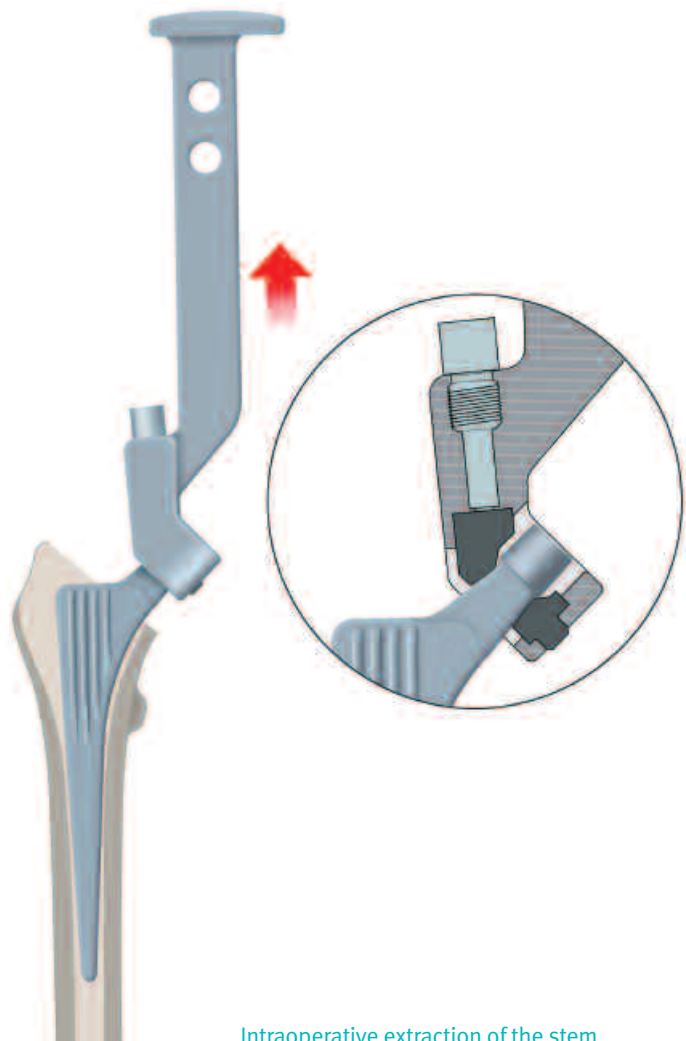
With the placing of drains and suturing of the different layers, the operation is now complete.

### Intraoperative Extraction of the Stem

If the stem needs to be removed intraoperatively only the specific extraction instrument has to be used, which protects the neck and the cone of the stem. Slide the extraction instrument over the stem taper, until the plastic jaws reach the neck of the stem. It is very important that the plastic jaws touch only the neck and not the taper. Afterwards tighten the plastic jaws with the ball hex screwdriver, until the extraction instrument is firmly fixed on the stem. Remove the stem by hammering on the extraction instrument.

**Important:** The extraction instrument can be used only for intraoperative stem extraction. It is not suitable for revision cases.

The plastic jaws can be exchanged if necessary.



Intraoperative extraction of the stem

### Disassembly of the Extraction Instrument

For cleaning and sterilization as well as for the exchange of the plastic jaws

Unlock screw with screwdriver for extraction instrument



Remove screw from plastic jaw



Extract fixed plastic jaw with the impactor according to the illustration



The disassembled instrument can now be cleaned and sterilized

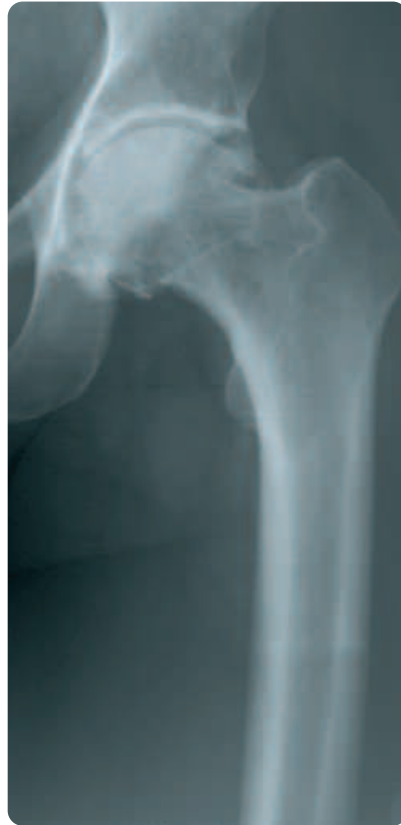**Note:**

Damaged plastic jaws have to be replaced!

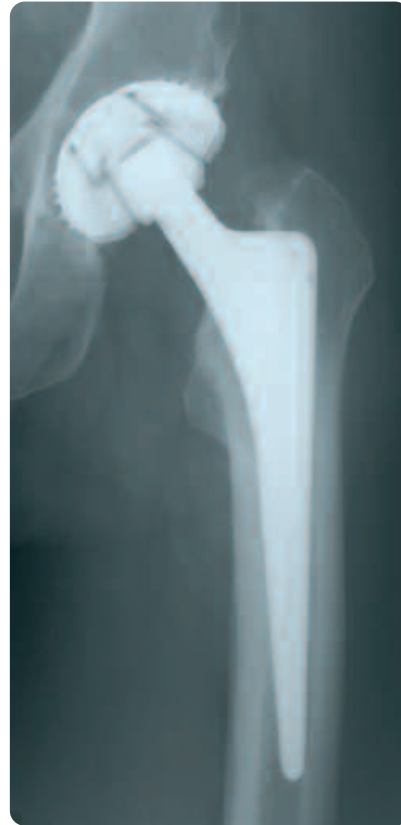

## Case Study

CLS Spotorno stem 145° and CLS Spotorno expansion cup



preoperative



postoperative 15.8 years

## Implants



CLS® Spotorno® 145° Stem



CLS® Spotorno® 135° Stem

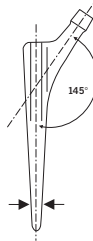


CLS® Spotorno® 125° Stem



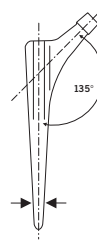
CLS® Spotorno® 145° HAC Stem

Details  
Protasul®-100  
Uncemented  
L. Spotorno



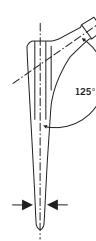
STERILE R

Details  
Protasul®-100  
Uncemented  
L. Spotorno



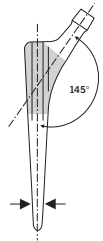
STERILE R

Details  
Protasul®-100  
Uncemented  
L. Spotorno



STERILE R

Details  
Protasul®-100/HAC  
Uncemented  
L. Spotorno



STERILE R


size in mm	REF
5.00	29.00.09-050
6.00	29.00.09-060
7.00	29.00.09-070
8.00	29.00.09-080
9.00	29.00.09-090
10.00	29.00.09-100
11.25	29.00.09-112
12.50	29.00.09-125
13.75	29.00.09-137
15.00	29.00.09-150
16.25	29.00.09-162
17.50	29.00.09-175
20.00	29.00.09-200

size in mm	REF
5.00	29.00.39-050
6.00	29.00.39-060
7.00	29.00.39-070
8.00	29.00.39-080
9.00	29.00.39-090
10.00	29.00.39-100
11.25	29.00.39-112
12.50	29.00.39-125
13.75	29.00.39-137
15.00	29.00.39-150
16.25	29.00.39-162
17.50	29.00.39-175
20.00	29.00.39-200

size in mm	REF
5.00	01.00295.005
6.00	01.00295.006
7.00	01.00295.007
8.00	01.00295.008
9.00	01.00295.009
10.00	01.00295.010
11.25	01.00295.011
12.50	01.00295.012
13.75	01.00295.013
15.00	01.00295.015
16.25	01.00295.016
17.50	01.00295.017
20.00	01.00295.020

size in mm	REF
5.00	29.00.59-050
6.00	29.00.59-060
7.00	29.00.59-070
8.00	29.00.59-080
9.00	29.00.59-090
10.00	29.00.59-100
11.25	29.00.59-112
12.50	29.00.59-125
13.75	29.00.59-137
15.00	29.00.59-150
16.25	29.00.59-162
17.50	29.00.59-175
20.00	29.00.59-200

## Instruments




Handle for modular rasp

REF  
01.00299.100



Long bar

REF  
70.00.01



Rasp modular

size in mm	REF
5.00	01.00299.105
6.00	01.00299.106
7.00	01.00299.107
8.00	01.00299.108
9.00	01.00299.109
10.00	01.00299.110
11.25	01.00299.111
12.50	01.00299.112
13.75	01.00299.113
15.00	01.00299.115
16.25	01.00299.116
17.50	01.00299.117
20.00	01.00299.120

Tray (complete)

REF  
ZS 01.00298.110

Standard container cover

REF  
01.00029.031

Tray (empty)

REF  
01.00298.110

Insert for tray (empty)

REF  
01.00298.102



Trial neck

CLS	REF
125°	01.00299.125
135°	01.00299.135
145°	01.00299.145



Repositioning tops

mm	REF
28	78.00.38-28
32	78.00.38-32



Impactor

REF
75.00.36



Trial heads

∅ 28	REF
12/14 S	01.01559.128
12/14 M	01.01559.228
12/14 L	01.01559.328
12/14 XL	01.01559.428

∅ 32	REF
12/14 S	01.01559.132
12/14 M	01.01559.232
12/14 L	01.01559.332
12/14 XL	01.01559.432



Double-curved gauge

mm	REF
9	75.09.15



Ruler

mm	REF
20	95.00.03



Boxed chisel

REF
75.13.02-10



Extraction instrument for stem

REF
01.00529.102



Repositioning lever

REF
75.11.00-02



Awl

REF
70.08.89



Screwdriver for extraction instrument

REF
01.00529.101



### Upon Request



Handle for modular rasp with IMT

REF  
01.00299.101



Plastic jaws for 01.00529.102

REF  
01.00529.103



Trial heads

Ø 36	REF
12/14 S	01.01559.136
12/14 M	01.01559.236
12/14 L	01.01559.336
12/14 XL	01.01559.436



Repositioning tops

mm	REF
36	78.00.38-36



Contact your Zimmer representative or visit us at [www.zimmer.com](http://www.zimmer.com)



Lit. No. 06.01297.012 – Ed. 12/2006 ZHUB



+H84406012970121/\$061201L064