



Original
M. E. Müller™
Ring



The Acetabular Roof Reinforcement Ring

The Acetabular Roof Reinforcement Ring, designed by M. E. Müller, has been in clinical use since 1977.

More than 183,000 Original M. E. Müller Rings have been implanted worldwide.

Its success may be attributed to the fact that it is an integral part of the MEM prosthesis concept and translates the orthopaedic principles of Maurice E. Müller into practice.

Original M. E. Müller Ring

Philosophy

The *Müller Ring* is modelled to be like the anatomical roof of the acetabulum and mainly reinforces the stress region in the hip joint. The implant can be optimally adapted to the shape of the acetabulum since the polyethylene cup is anchored using cement and, thus, may be freely positioned.

Anchorage

The *Müller Ring* is anchored without cement. It is inserted with a slight press-fit into the acetabulum and secured using 3 to 5 cancellous bone screws. It is crucial for the primary stability of the ring that it sits well medio-caudally with direct bone contact and that its rim supports the cranio-dorsal cup rim. The *Original M. E. Müller Low Profile Cup* made of polyethylene is then secured with cement in the desired position. Thus, optimum anteversion and inclination is possible, regardless of the position of the *Müller Ring*. In revision cases or in extensive bone defects, implantation of the *Müller Ring* is advisable in combination with bone grafting.

Indications

The *Müller Ring* is, in principle, indicated for cases with insufficient bone substance or partial acetabular defects and, thus, has a very broad range of indications. It is recommended in:

- primary cases with insufficient bone stock
- revision cases with partial acetabular defects
- extensive osteoporosis
- acetabular roof cysts
- femoral head necrosis dysplastic or small acetabula
- rheumatic coxitis

Design

- Cup fixation using screws achieves high primary stability in the stressed zone
- Blasted pure titanium surface favours osseointegration

- Independent positioning of the PE insert in the ring enables optimum cup orientation
- Numerous screw holes give many screw options
- The recess at the pole and the hole pattern enable comprehensive checking of bone contact

Range

- Outstanding choice of implant sizes
- No implant-specific instruments required
- Insert made of either *Sulene*®, *Durasul*® or with *Metasul*® inlay
- Reasonably priced implant, interesting for a wide range of indications



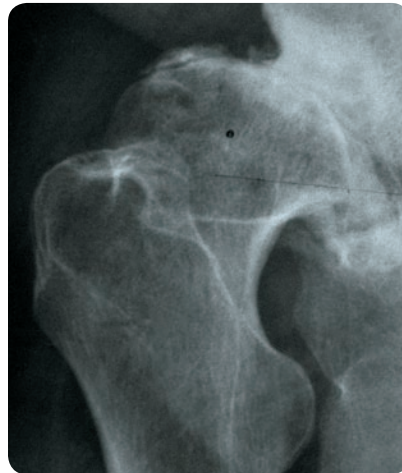Case Studies

The 37-year-old nursery school teacher complained of stress-dependent hip pain, clearly reduced ability to walk, leg shortening of 3 cm and activity reduced by half.

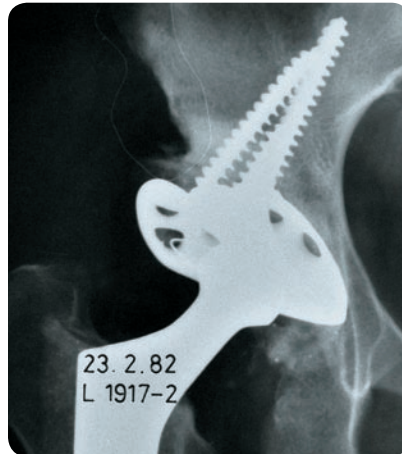
Implantation of a CDH prosthesis and a *Müller Ring*.

The postoperative course showed no complications. After only a few months, the patient could fully resume her work and daily activities.

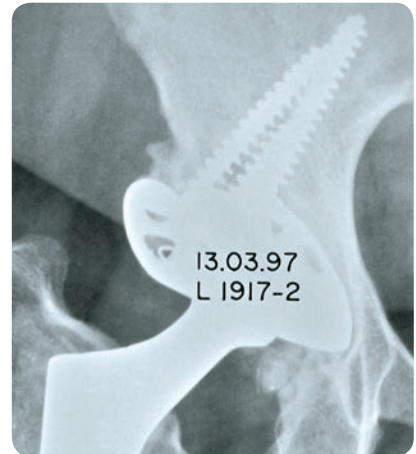
At the follow-up after 15 years, the patient had no complaints regarding the right hip and regarded the outcome of the operation as excellent. The X ray showed unchanged and stable seating of the *Müller Ring*.



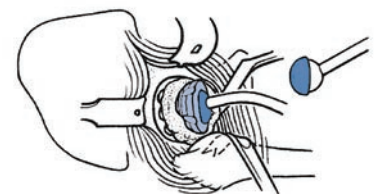
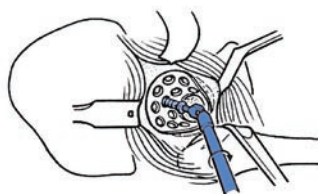
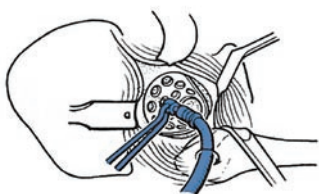
Osteoarthritis of the hip joint with congenital hip dysplasia



Postoperative



After 15 years



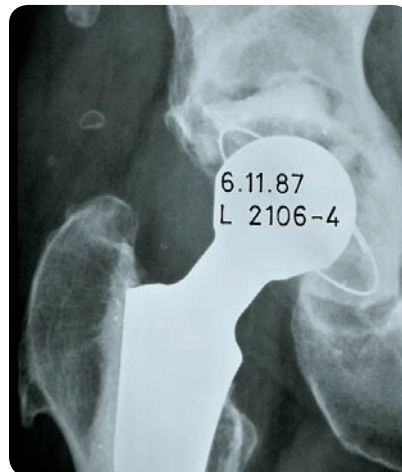Excerpt from the surgical technique

The 61-year-old housewife complained of severe pain in the groin and trochanter region and had clearly impaired ability to walk.

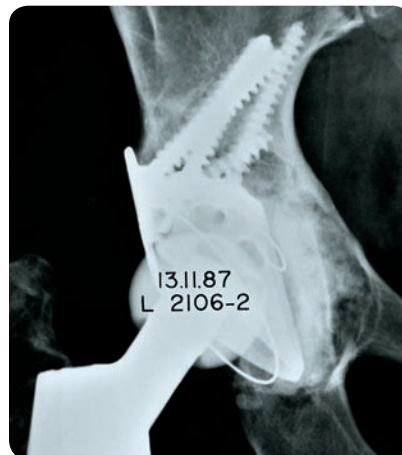
Revision of the prosthesis with a *Müller Ring* and bone grafting.

The postoperative course showed no problems with respect to the hip. Daily activity was quickly resumed.

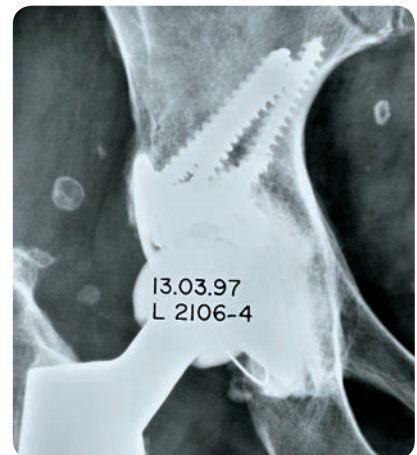
At the follow-up after 10 years the patient indicated no complaints or limitations and was very satisfied with the outcome of the operation. The X ray showed no signs of instability of the *Müller Ring*.



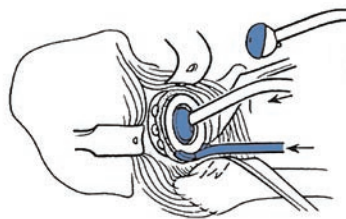
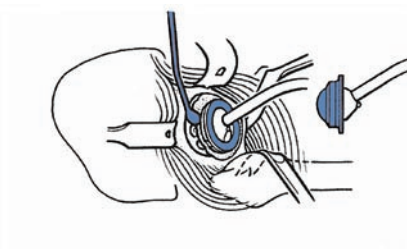
Aseptic prosthetic loosening



Postoperative



After 10 years

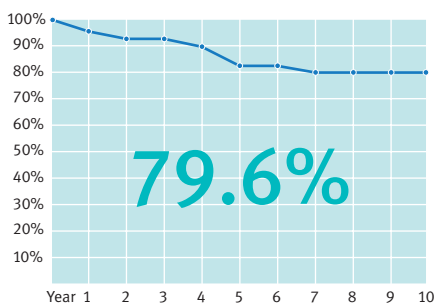


Publications

Midterm Results (5.5–10 Years) of Acetabular Allograft Reconstruction with the Acetabular Reinforcement Ring during Total Hip Revision

(M. K. Zehntner, R. Ganz; The Journal of Arthroplasty Vol. 9, No. 5, 1994)

Acetabular reconstructions using frozen femoral head allografts and the Acetabular Reinforcement Ring of M.E. Müller have been analyzed after an average follow-up period of 7.2 years (range, 5.5–10 years) in 27 patients/hips. [...] The incidence of migration in adequate reconstructions for segmental only and combined cavitory and segmental defects was 6 of 12 (50%), whereas it was 1 of 10 in reconstructions of cavitory deficiencies. Kaplan-Meier survivorship analysis revealed a 79.6% probability of survival at 10 years with revision as the endpoint for failure. It is concluded that durability of the reconstruction can be expected if support of the metallic reinforcement device is provided by hostbone. Segmental and combined deficiencies may require additional internal fixation by plates and screws.

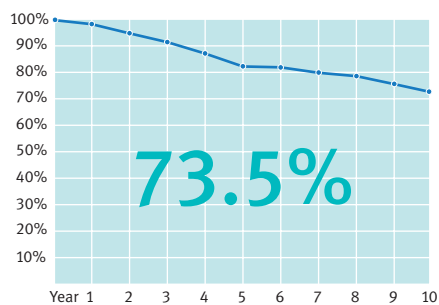


Survivorship Analysis

The M. E. Müller Acetabular Roof Reinforcement Ring in Revision Arthroplasty of the Hip

(P. Gurtner, M. Aebi, R. Ganz; Zeitschrift für Orthopädie Band 131, 1993)

The efficiency of the M. E. Müller Acetabular Roof Reinforcement Ring is documented on 141 patients with 150 operated hips since 1976 with a minimal clinical and radiological follow-up of 6 years. The metal-backing of the cup prevented cranial migration and protrusion almost completely. After 1982, when a bone bank with frozen femoral heads was established, the loss of bone stock was replaced with allograft, which can be fixed sufficiently with the Reinforcement Ring. In revision arthroplasty with bone stock of poor quality and quantity, the Acetabular Roof Reinforcement Ring is a good method to reconstruct the acetabulum.



Survivorship Analysis

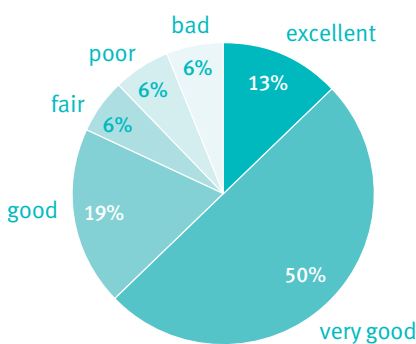
Cemented Acetabular Reconstruction with the Müller Support Ring – A Minimum Five-Year Clinical and Roentgenographic Follow-Up Study

(P. Haentjens, H. de Boeck et al.; Clinical Orthopaedics and Related Research, Vol. 290, May 1993)

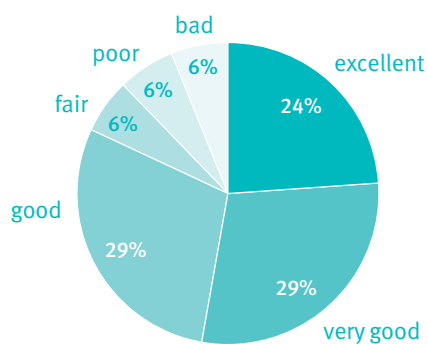
In a previous study, the results of cemented acetabular reconstruction with a Müller Support Ring were reported after a mean follow-up period of 40 months. The current report concerns a minimum five-year follow-up study of the same 43 patients. Two early failures at four months and at 17 months were related to poor surgical technique. The latest overall functional results, according to the Merle d'Aubigné rating scale, were excellent, very good or good in 81.82% of the hips: a drop from 86.67% since the previous report. Sequential roentgenographic analysis demonstrated a high incidence of nonprogressive

radiolucencies at the cement-bone interface. These non-progressive radiolucencies did not correlate with the overall functional results. The progression of a radiolucency at the cement-bone interface, however, or the appearance of radiolucencies around the screw threads, always resulted in clinical failure.

Primary THA (after 7 years 9 months)



Revision Surgery (after 8 years)



Overall Functional Results

Disclaimer

This document is intended exclusively for experts in the field, i. e. physicians in particular, and is expressly not for the information of laypersons.

The information on the products and/or procedures contained in this document is of a general nature and does not represent medical advice or recommendations. Since this information does not constitute any diagnostic or therapeutic statement with regard to any individual medical case, individual examination and advising of the respective patient are absolutely necessary and are not replaced by this document in whole or in part.

The information contained in this document was gathered and compiled by medical experts and qualified Zimmer employees to the best of their knowledge. The greatest care was taken to ensure the accuracy and ease of understanding of the information used and presented. Zimmer does not assume any liability, however, for the up-to-dateness, accuracy, completeness or quality of the information and excludes any liability for tangible or intangible losses that may be caused by the use of this information.

In the event that this document could be construed as an offer at any time, such offer shall not be binding in any event and shall require subsequent confirmation in writing.

Contact your Zimmer representative or visit us at www.zimmer.com



Lit. No. 95.01.131x – Ed. 02/2006 ZHUB



+H8449501131X1/\$060201G06N