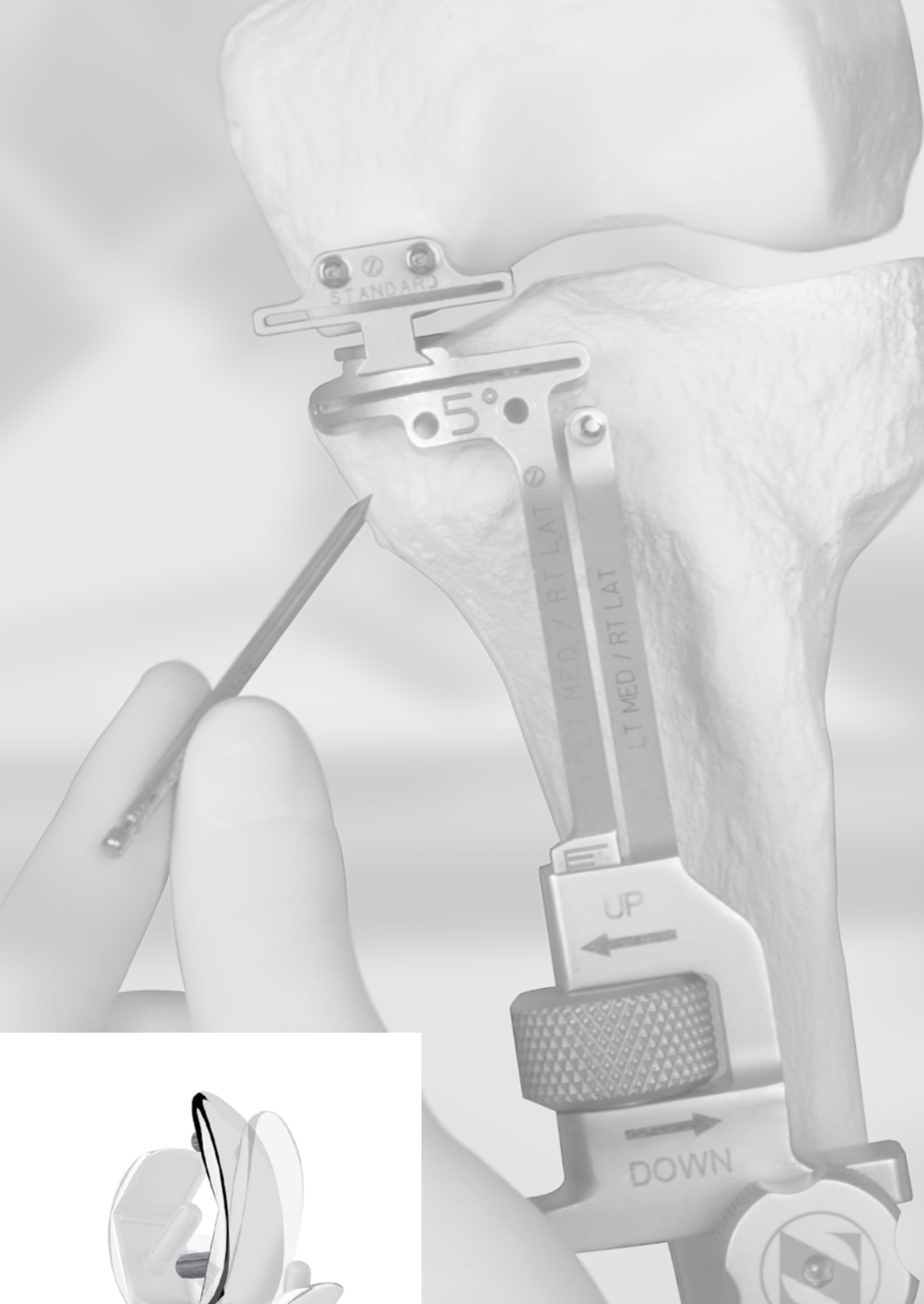



## Zimmer® Unicompartmental High Flex Knee

Intramedullary, Spacer Block  
Option and Extramedullary  
Minimally Invasive  
Surgical Techniques



High-Flex Solutions for the *MIS*™ Era

**ZIMMER  
UNICOMPARTMENTAL  
HIGH FLEX KNEE  
INTRAMEDULLARY,  
SPACER BLOCK OPTION,  
EXTRAMEDULLARY  
MINIMALLY INVASIVE  
SURGICAL TECHNIQUES**

**SURGICAL TECHNIQUES DEVELOPED  
IN CONJUNCTION WITH:**

Paolo Aglietti, M.D.  
*Director, The First Orthopaedic Clinic  
University of Florence  
Florence, Italy*

Shaw Akizuki, M.D., Ph.D.  
*Executive Vice President and Chief  
Surgeon of Orthopedic Surgery  
Nagano Matsushiro General Hospital  
Clinical Professor  
Department of Orthopedic Surgery  
Shinshu University School of Medicine  
Nagano City, Japan*

Fermin Aramburo, M.D.  
*Director Servei de C.O.T.  
Hospital de Sabadell  
Sabadell, Spain*

Jean-Noël A. Argenson, M.D.  
*Professor of Orthopedic Surgery  
The Aix-Marseille University  
Hospital Sainte-Marguerite  
Marseille, France*

Jean-Manuel Aubaniac, M.D.  
*Professor of Orthopedic Surgery  
The Aix-Marseille University  
Hospital Sainte-Marguerite  
Marseille, France*

Jonathan Braslow, M.D.  
*Arthritis Institute - JFK Hospital  
Advanced Orthopaedics  
Indio, California*

Robert L. Diaz, M.D.  
*Palm Beach Orthopaedic Institute  
Palm Beach Gardens, Florida*

Andrew A. Freiberg, M.D.  
*Arthroplasty Service Chief  
Massachusetts General Hospital  
Boston, Massachusetts*

Lindsay Laird, M.D.  
*Newcastle Joint Care Centre  
Broadmeadow 2292  
Australia*

David G. Nazarian, M.D.  
*Clinical Assistant Professor of Orthopaedics  
University of Pennsylvania  
Pennsylvania Hospital  
Philadelphia, Pennsylvania*

Aaron Rosenberg, M.D.  
*Professor of Orthopaedic Surgery  
Arthritis & Orthopaedic Institute  
Rush Medical College  
Rush University Medical Center  
Chicago, Illinois*

Heinz Röttinger, M.D.  
*Orthopädische Chirurgie München  
Munich, Germany*

Alfred J. Tria, Jr., M.D.  
*Clinical Professor of Orthopaedic Surgery  
St. Peter's University Hospital  
Robert Wood Johnson Medical School  
New Brunswick, New Jersey*

Richard V. Williamson, M.D.  
*Skagit Valley Hospital  
Skagit Island Orthopaedic Center  
Mount Vernon, Washington*

Russell E. Windsor, M.D.  
*Professor of Orthopaedic Surgery  
Sanford A. Weill Medical School of  
Cornell University  
Attending Orthopaedic Surgeon and  
Co-chief of the Knee Service  
The Hospital for Special Surgery  
New York, New York*

**CONTENTS**

**INTRAMEDULLARY (IM)  
SURGICAL PROCEDURE**


Introduction ..... 2  
Rationale ..... 3  
Preoperative Planning ..... 4  
Patient Preparation ..... 5  
Exposure ..... 6  
**Step One:** Drill Hole in Distal Femur ..... 7  
**Step Two:** Resect the Distal Femoral Condyle ..... 8  
**Step Three:** Resect the Proximal Tibia ..... 10  
**Step Four:** Check Flexion/Extension Gaps ..... 14  
**Step Five:** Size the Femur ..... 16  
**Step Six:** Finish the Femur ..... 18  
**Step Seven:** Finish the Tibia ..... 21  
**Step Eight:** Perform Trial Reduction ..... 24  
**Step Nine:** Implant Final Components ..... 26  
Closure ..... 27

**SPACER BLOCK OPTION  
SURGICAL PROCEDURE**

Spacer Block Option ..... 28

**EXTRAMEDULLARY (EM)  
SURGICAL PROCEDURE**

Introduction ..... 30  
Rationale ..... 31  
Preoperative Planning ..... 32  
Patient Preparation ..... 33  
Exposure ..... 34  
**Step One:** Assemble/Apply the Instrumentation ..... 36  
**Step Two:** Align the Joint ..... 40  
**Step Three:** Resect the Distal Femoral Condyle ..... 42  
**Step Four:** Resect the Proximal Tibia ..... 43  
**Step Five:** Check Flexion/Extension Gaps ..... 44  
**Step Six:** Size the Femur ..... 46  
**Step Seven:** Finish the Femur ..... 48  
**Step Eight:** Finish the Tibia ..... 51  
**Step Nine:** Perform Trial Reduction ..... 54  
**Step Ten:** Implant Final Components ..... 56  
Closure ..... 57





# INTRAMEDULLARY (IM) SURGICAL PROCEDURE WITH SPACER BLOCK OPTION

## INTRODUCTION

Unicompartmental knee arthroplasty (UKA) has been shown to be an effective treatment for isolated osteoarthritis affecting the medial or lateral compartment. The *M/G*® Unicompartmental Knee System has long-term clinical success with 98% survivorship over a 6 - 10 year period.<sup>1</sup>

The *MIS*™ Instruments for the *Zimmer* Unicompartmental High Flex Knee System are designed to provide accurate, reproducible results using a minimally invasive technique. The goals of a minimally invasive surgical procedure are to:

- Facilitate the patient's recovery
- Provide less pain
- Provide earlier mobilization
- Provide shorter hospital stay
- Provide quicker rehabilitation

This instrumentation allows the surgeon to operate without everting the patella. The system offers three *MIS* instrumentation options:

- Intramedullary Instrumentation System (IM)
- Spacer Block Option
- Extramedullary Instrumentation System (EM)

The same tibial assembly is used for all three options. However, the distal femoral resection instruments are unique to each of the three techniques.

This guide to the surgical technique is a step-by-step procedure written for a medial compartment UKA. Many of the same principles can be applied to the lateral compartment but it may be necessary to extend the incision a few centimeters given the proximity of the patella to the lateral condyle.

Combined with surgeon judgment, proper patient selection, and appropriate use of the device, this guide offers a comprehensive technique that discusses the procedure for component selection, bone preparation, trial reduction, cementing techniques, and component implantation. It is strongly recommended that the surgeon read the complete procedure for details, notes, and technique tips.



## RATIONALE

The basic goals of unicompartmental knee arthroplasty are to improve limb alignment and function, and to reduce pain. Routinely, an effort is made to minimize disruption of the surrounding soft tissue during the procedure. The development of instruments specifically designed to be used through a smaller exposure has had a significant impact on this effort.

Accurate limb alignment is described by the mechanical axis of the lower extremity, which is a straight line running from the center of the femoral head to the center of the ankle. When the center of the knee lies on this mechanical axis, the knee is said to be in neutral alignment. Unicompartmental knee disease typically reduces the joint space in the affected compartment, causing a malalignment of the joint. Full correction of the malalignment would return the knee to neutral alignment. (Fig. 1)

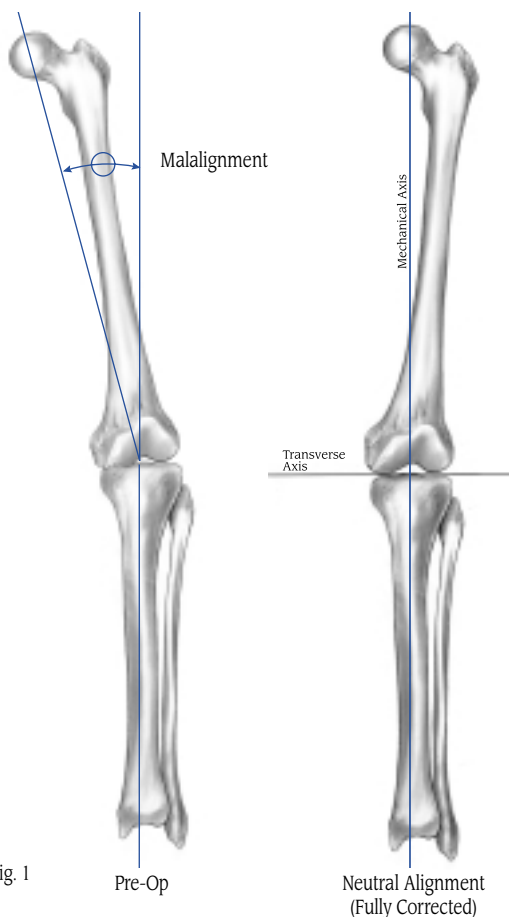


Fig. 1

The alignment goals for unicompartmental arthroplasty differ from those that are customary in high tibial osteotomy (HTO) where over-correction is desirable to displace the weight-bearing forces away from the diseased compartment. In contrast, when adjusting limb alignment in a unicompartmental procedure, **it is particularly important to avoid overcorrection of the limb** as this may increase the stress in the contralateral compartment and heighten the potential for cartilaginous breakdown. Studies of unicompartmental procedures have shown that slight undercorrection of the limb alignment correlates to long-term survivorship.<sup>5</sup>

It is important to recognize that the methods used to adjust alignment in TKA are very different from those used in unicompartmental arthroplasty. In TKA, the angle of the femoral and tibial cuts determine the postoperative varus/valgus alignment. In UKA, the angle of the cuts does not affect varus/valgus alignment. **Instead, post-operative varus/valgus alignment is determined by the composite thickness of the prosthetic unicompartmental components.**

The mechanical axis of the femur is represented by a line between the center of the femoral head and the intercondylar notch at the knee. In the IM technique, the angle between the mechanical axis of the femur and the anatomic axis of the femur is measured, and then used to determine the angle of the distal femoral resection.

The resection guide is inserted into the femoral canal so the distal femoral cut is based off the anatomic axis. The cutting block is then attached to the resection guide and positioned to reproduce the desired angle. This results in a distal femoral cut that is perpendicular to the mechanical axis of the femur, and parallel to the tibial cut.



## SPACER BLOCK OPTION

The Spacer Block option provides an alternate extramedullary method for resecting the distal femoral condyle after the IM technique. After resecting the tibia, the Spacer Block is inserted into the joint space with the chosen tibial thickness, the Distal Femoral Resector is then attached to the Spacer Block, providing a linked cut, and to help ensure that the proximal tibial cut and distal femoral cut are parallel.

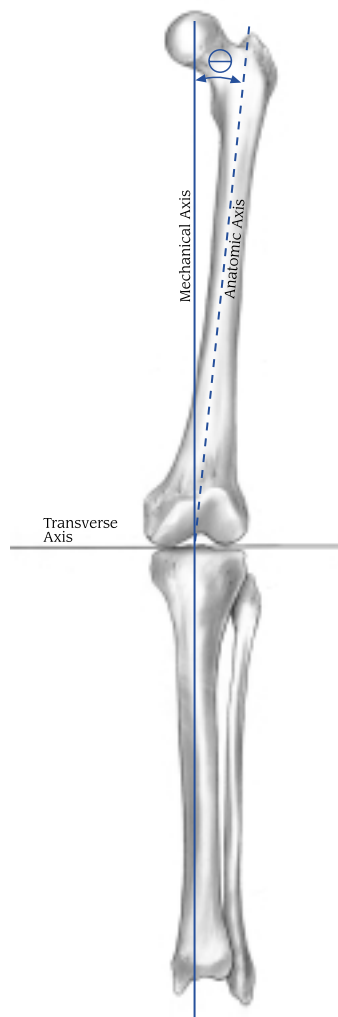


Fig. 2

## PREOPERATIVE PLANNING

This technique is written with the distal femoral resection performed first. However, if preferred, the tibia can be resected first. To resect the tibia first, begin with Step 3, “Resect the Proximal Tibia.” Then continue with Step 1, “Resect the Distal Femur.”

For the Spacer Block technique, the tibia must be resected first as the femoral resection is based off the tibial cut. If the surgeon prefers to use the Spacer Block technique, begin with Step Three, “Resect the Proximal Tibia.” Then go to the Spacer Block procedure on page 28. After completing the Spacer Block procedure, continue with Step Four and complete the remaining steps in this technique.

Take standing weight-bearing A/P and lateral radiographs of the affected knee, and a skyline radiograph of the patella. Then take a long standing A/P radiograph showing the center of the femoral head, the knee, and as much of the tibia as possible (preferably including the ankle). Alternatively, a single A/P radiograph of the entire femur allows correct calculations and can be made on a 35cm x 42cm (14 x 17-inch) film.

The IM Femoral Resection Guide and Distal Femoral Resector Block have been designed to reference the anatomic axis of the femur. On the radiograph, draw a line from the center of the femoral head to the center of the distal femur at the knee. This line represents the mechanical axis of the femur. Draw a second line down the center of the distal femoral shaft (Fig. 2) in the area where the IM Femoral Resection Guide will be used to reproduce the anatomic axis of the femur. The angle between the mechanical and anatomic axes of the femur determines the distal femoral condyle cut, and is usually 6°.





The angle of the distal femoral cut determines the contact point of the femoral component on the tibia (Fig. 3). This angle does not affect varus/valgus limb alignment. The goal is to produce a parallel relationship between the distal femoral cut and the proximal tibial cut. The resection guide allows for a choice of four angles (2°, 4°, 6°, or 8°).

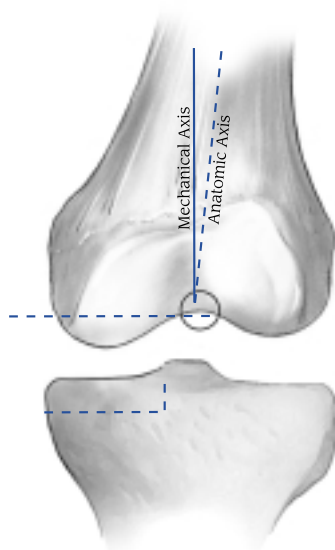


Fig. 3

Occasionally, in patients who have had total hip arthroplasty with a femoral component that has more valgus in the neck/shaft angle than usual, or in the patient with coxa valga, the angle between the mechanical and anatomic axes of the femur may be 4° or even 2°. The rare patient with significant coxa vara or a broad pelvis with long femoral necks may have an angle of 8°.

No calculations for the tibia are necessary. The tibial assembly is aligned visually with the mechanical axis of the tibia, and the cut is made perpendicular to this axis.

It is important to avoid overcorrection. An additional radiograph while stressing the limits of the tissues may be helpful in assessing the appropriate correction.

When evaluating the patient and planning for the procedure, consider TKA if:

- Degenerative changes are present in the contralateral compartment and/or the patellofemoral joint.
- The ACL is deficient.
- A significant flexion contracture exists.
- Slight undercorrection is not attainable.
- There is significant overcorrection with a valgus stress.
- There is an existing valgus or varus deformity  $\geq 15^\circ$ .

## PATIENT PREPARATION

With the patient in the supine position, test the range of hip and knee flexion. If unable to achieve 120° of knee flexion, a larger incision may be necessary to create sufficient exposure. Wrap the ankle area with an elastic wrap. Do not place bulky drapes on the distal tibia, ankle, or foot. A bulky drape in this area will make it difficult to locate the center of the ankle, and will displace the Tibial Resector, which may cause inaccurate cuts.

Be sure that the proximal femur is accessible for assessing the femoral head location. Use anatomic landmarks to identify the location of the femoral head. Alternatively, the surgeon may prefer to reference the anterior-superior iliac spine.

### *Technique Tip*

*Place a marker, such as an EKG electrode, over the center of the femoral head. Then confirm the location with an A/P radiograph.*



## EXPOSURE

The incision can be made with the leg in flexion or extension, according to preference. Make a medial parapatellar skin incision extending from the superior pole of the patella to about 2cm-4cm below the joint line adjacent to the tibial tubercle (Fig. 4).

Incise the joint capsule in line with the skin incision beginning just distal to the vastus medialis muscle and extending to a point distal to the tibial plateau (Fig. 5). Excise the fat pad, as necessary to facilitate visualization, being careful not to cut the anterior horn of the lateral meniscus. Reflect the soft tissue subperiosteally from the tibia along the joint line back towards, but not into, the collateral ligament. Excise the anterior third of the meniscus. The remainder of the meniscus will be removed after bone resection.

A subperiosteal dissection should be carried out towards the midline, ending at the patellar tendon insertion. This will facilitate positioning of the tibial cutting guide.

Debride the joint and inspect it carefully. Remove intercondylar osteophytes to avoid impingement with the tibial spine or cruciate ligament. Also, remove peripheral osteophytes that interfere with the collateral ligaments and capsule. With medial compartment disease, osteophytes are commonly found on the lateral aspect of the medial tibial eminence and anterior to the origin of the ACL. Final debridement will be performed before component implantation. **Careful osteophyte removal may be important in achieving full extension.**

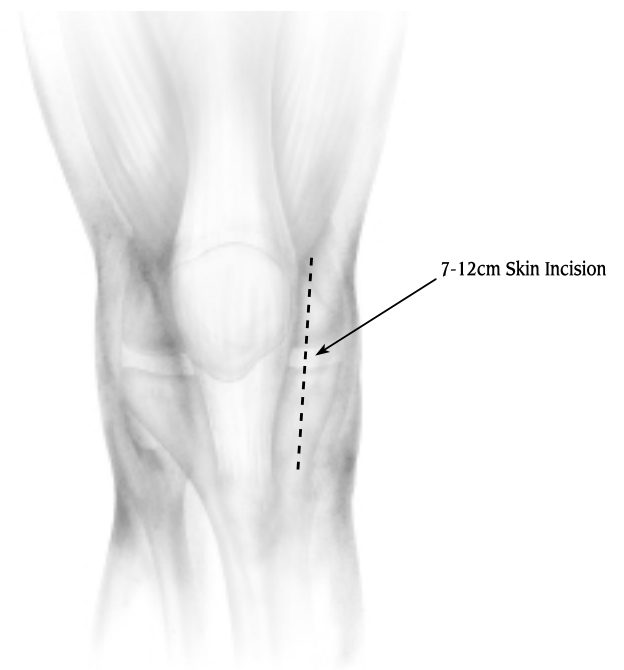

Fig. 4

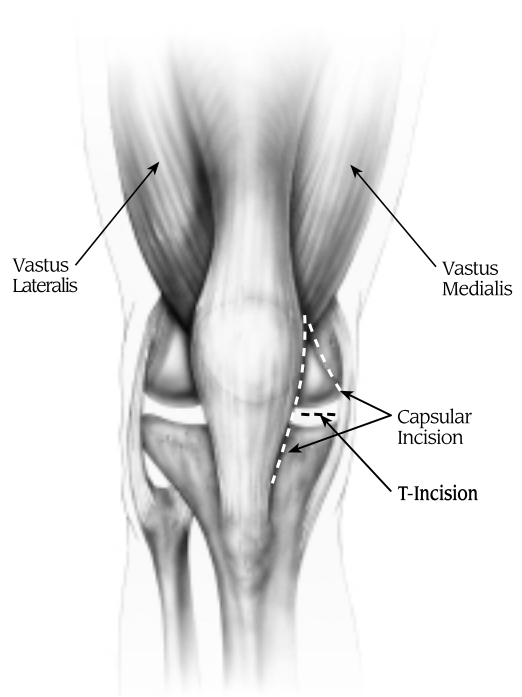


Fig. 5

## STEP ONE: DRILL HOLE IN DISTAL FEMUR

Without everting the patella, flex the knee 20°-30° and move the patella laterally. Choose the site for inserting the IM Femoral Resection Guide approximately 1cm anterior to the origin of the posterior cruciate ligament and just anterior to the intercondylar notch in the distal femur. Use the 8mm Femoral IM Drill or an awl to create the hole for the guide. Hold the drill parallel to the shaft of the femur in both the A/P and lateral projections (Fig. 6). Drill only the cancellous bone of the distal femur. **Suction the canal to remove intramedullary fat. This will help reduce intramedullary pressure during the placement of subsequent guides.**

The hollow diaphysis offers little resistance to the insertion of the intramedullary rod of the resection guide. IM Femoral Resection Guides are available for LT MED/RT LAT or RT MED/LT LAT, with two different rod lengths. The standard length is 23cm (nine inches) long and provides the most accurate reproduction of the anatomical axis. If the femoral anatomy is altered, as in a femur with a long-stem total hip femoral component, or with a femoral fracture malunion, then use the optional resection guide with a 10cm (four-inch) rod.

Using the Universal Handle, insert the appropriate IM Femoral Resection Guide into the femur (Fig. 7). Control the rotation of the guide as it approaches the articular surface of the femur. The posterior edge of the guide should be parallel to the tibial articular surface (perpendicular to the tibial shaft) (Fig. 8). The goal is to be parallel to the cut surface of the tibia after the tibial cut is made. Flex or extend the knee as necessary to properly position the guide. **Make sure that the**

surface of the resection guide is flush with the condyles and no soft tissue is impinged.

Predrill and place a Holding Pin on the posterior flange of the IM Femoral Resection Guide.

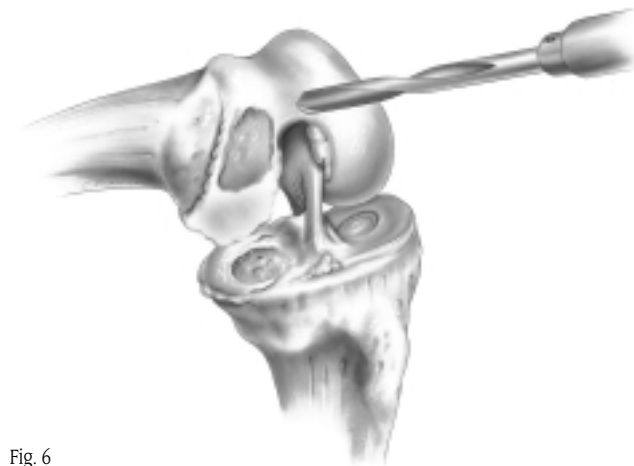


Fig. 6



Fig. 7

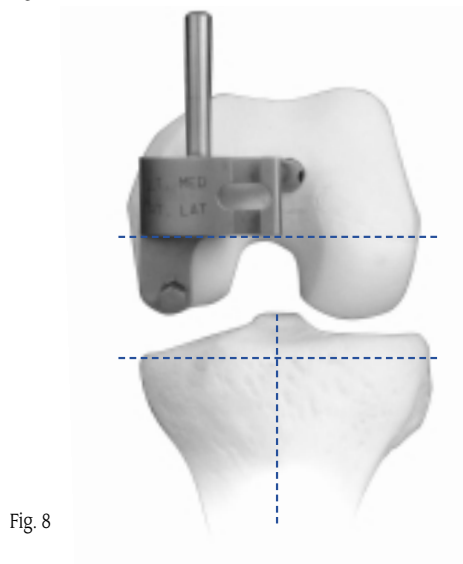


Fig. 8





## STEP TWO: RESECT THE DISTAL FEMORAL CONDYLE

Make sure that the IM Femoral Resection Guide is contacting the distal femur (not osteophytes) and that the soft tissue is protected. **Not fully seating this guide could cause insufficient resection of the distal femur.**

Choose the appropriate Distal Femoral Resector Block. The silver block is for medial compartment resection, and the gold block is for lateral compartment resection.

With the engraving that corresponds to the compartment to be resected facing up (Right MED, Left MED, or Right LAT, Left LAT), slide the correct Distal Femoral Resector Block over the anterior post of the resection guide until the edge of the block contacts the distal femur.

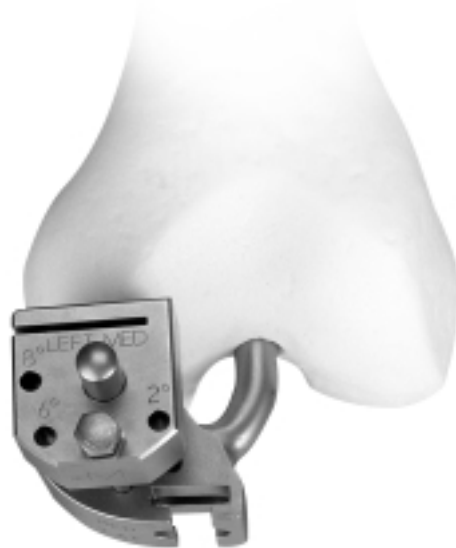

Fig. 9

Observe the angle-setting holes on the anterior surface of the block and select the appropriate angle as determined by preoperative radiographs. Insert a Slotted Holding Pin through the appropriate hole in the Distal Femoral Resector Block (Fig. 9). Mate it with the corresponding angle hole in the IM Femoral Resection Guide. This locks the angle and prevents movement of the resector block.

**Note:** *If a pin is used for fixation of the IM guide to the distal femur, impingement may occur with the saw blade. The distal cut may be started with the pin in place, but the pin should be removed before contact with the blade occurs.*

Use a narrow, 1.27mm (0.050-inch) oscillating or reciprocating blade to cut the distal portion of the condyle through the slot of the Distal Femoral Resector Block (Fig. 10). The amount of articular cartilage and bone removed will be replaced by the femoral component. Having the IM Femoral Resection Guide flush against the femoral condyle will help ensure that the proper amount of bone is resected.



Fig. 10

When performing the cut from the medial side, carefully place a retractor at the superior-medial portion of the skin incision to protect the skin.

After removing the IM Femoral Resection Guide and Distal Femoral Resector Block, check the flatness of the distal femoral condyle cut with a flat surface. If necessary, modify the cut surface of the distal condyle so that it is completely flat. This is extremely important for the placement of subsequent guides and for proper fit of the implant. Smooth any bony prominences that remain and to contour the peripheral edge of the femur to restore anatomic shape.

Insert the IM Patellar Retractor into the medullary canal (Fig.11).

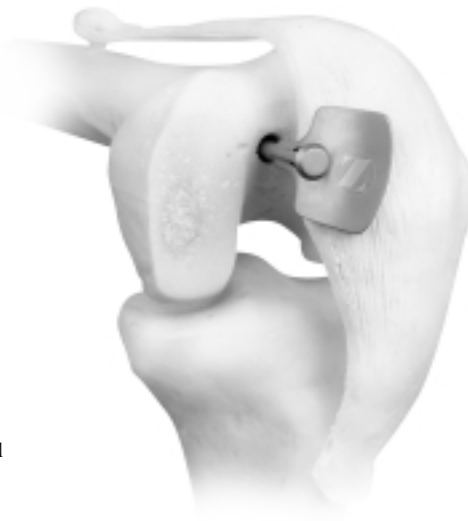

Fig. 11





### STEP THREE: RESECT THE PROXIMAL TIBIA

*Note: This technique is written to cut the tibia after cutting the distal femur. If preferred, the femoral cuts can be finished first (Refer to page 15).*

The Zimmer Unicompartmental Knee System is designed for an anatomic position with a 5° posterior slope. It is important that the proximal tibial cut be made accurately. The tibial assembly consists of a Tibial Resector, a Tibial Resector Base, a Tibial Resector Stem, a Distal Telescoping Rod, and an Ankle Clamp (Fig. 12). **Positioning of the Tibial Resector is crucial.**

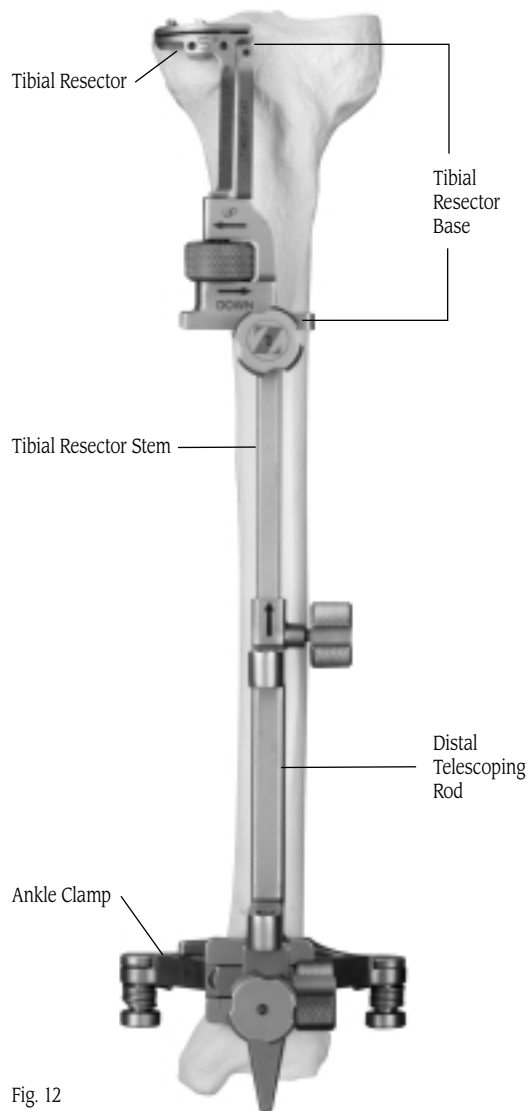


Fig. 12

Slide the Ankle Clamp onto the dovetail at the bottom of the Distal Telescoping Rod, and tighten the knob opposite the dovetail to temporarily hold the clamp in place. Then insert the appropriate length Tibial Resector Stem into the proximal end of the Distal Telescoping Rod and tighten the knob.

Attach the appropriate Tibial Resector to the corresponding Tibial Resector Base. Note that the resector and base are available in two configurations: LT MED/RT LAT and RT MED/LT LAT. Then slide the dovetail on the Tibial Resector Base onto the proximal end of the Tibial Resector Stem and tighten the knob on the stem. The dovetail provides a slide adjustment that allows M/L positioning.

Secure the distal portion of the assembly by placing the spring arms of the Ankle Clamp around the ankle proximal to the malleoli (Fig. 13). Loosen the knob at the top of the Distal Telescoping Rod, position the Tibial Resector proximal to the tibial tubercle with the cutting slot at the approximate desired level of resection, then retighten the knob.



Fig. 13



While holding the proximal portion of the assembly in place, loosen the knob that provides mediolateral adjustment of the Distal Telescoping Rod. Adjust the distal end of the rod so it lies directly over the tibial crest. Then fully tighten the knob to secure it in place. This will help ensure that the proximal portion of the guide is parallel to the mechanical axis of the tibia. Mediolateral adjustments can also be made proximally, but the proximal portion will always remain parallel to the distal portion and, therefore, parallel to the mechanical axis of the tibia.

Use the proximal M/L slide adjustment at the midshaft of the assembly to position the fixation arm of the Tibial Resector Base and Tibial Resector so it lies just medial to the midpoint of the tibial tubercle and is in line with the center of the intercondylar eminence (Fig.14).




Fig. 14

In the sagittal plane, align the assembly so it is parallel to the anterior tibial shaft (Fig.15) by using the A/P slide adjustment at the distal end of the Distal Telescoping Rod. Tighten the knob for the adjustment. If there is a bulky bandage around the ankle, adjust the assembly to accommodate the bandage. This will help with cutting the tibia in the proper slope.

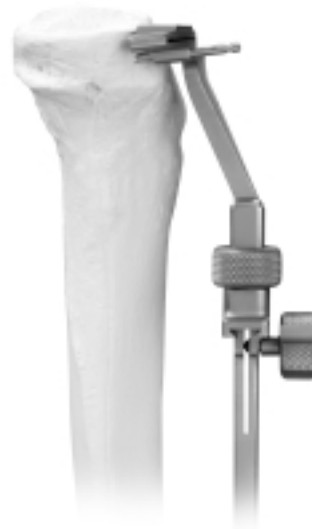

Fig. 15

**Optional Technique:**

*If the patient has a slight flexion contracture, cutting less posterior slope may help as it would result in less bone resection posteriorly than anteriorly, thereby opening the extension gap more relative to the flexion gap. This can be accomplished by moving the assembly closer to the leg distally. Then check the depth and angle of resection with the Resection Guide.*



Secure the assembly to the proximal tibia by inserting a 48mm Headed Screw, or predrilling and inserting a Holding Pin, through the hole in the fixation arm of the Tibial Resector Base (Fig. 16). **Do not completely seat the screw/pin until the final adjustments have been made to the position of the Tibial Resector.**

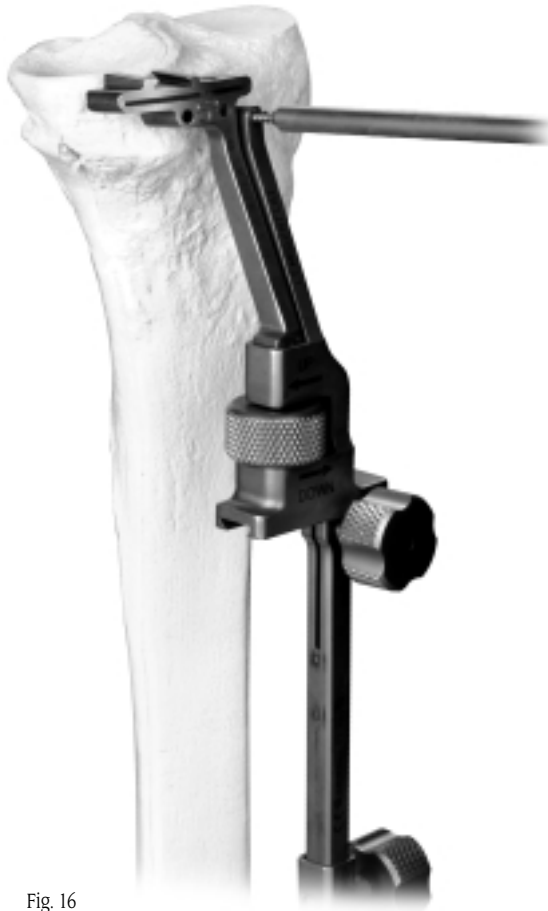

Fig. 16

Use the 2mm tip of the Tibial Depth Resection Stylus to help achieve the desired depth of cut. Insert the stylus into the hole on the top of the Tibial Resector and gently tighten the screw. The tip of the stylus should rest in the deepest defect in the tibia (Fig.17). This indicates a cut that will remove 2mm of bone below the tip of the stylus. If necessary, use the thumb screw on the Tibial Resector Base to adjust the resection level.

**Note:** *The 4mm tip of the Tibial Depth Resection Stylus indicates a cut that will remove 4mm of bone below the tip of the stylus.*

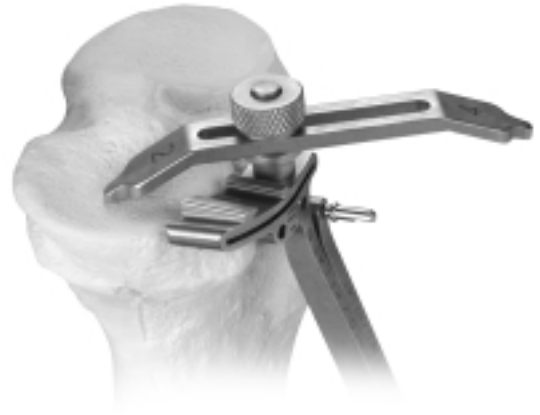

Fig. 17





Seat the screw/pin that was inserted into the Tibial Resector Base. Then secure the Tibial Resector to the proximal tibia by predrilling and inserting Gold Headless Holding Pins, or inserting 48mm Headless Holding Screws, through the two holes. Use electrocautery or the reciprocating saw to score the tibial surface where the sagittal cut will be made. Check this point both in extension and flexion.

If desired, the depth of cut can be verified by inserting the Resection Guide (Fig. 18).



Fig. 18

Insert a retractor medially to protect the medial collateral ligament. Use 1.27mm (0.050-inch) oscillating saw blade through the slot in the cutting guide to make the transverse cut. The Tibial Resector must remain against the bone during resection.

**Note:** Do not use a saw blade with a thickness of less than 1.27mm to avoid inaccurate cuts.

With the knee flexed, use the reciprocating blade at the base of the tibial eminence, and parallel to the eminence in the A/P plane. **Cut along the edge of the ACL down to, but not beyond, the intended level of the transverse cut (Fig. 19). Be careful to avoid the ACL attachment.**

When the tibial preparation is complete, remove the tibial assembly.

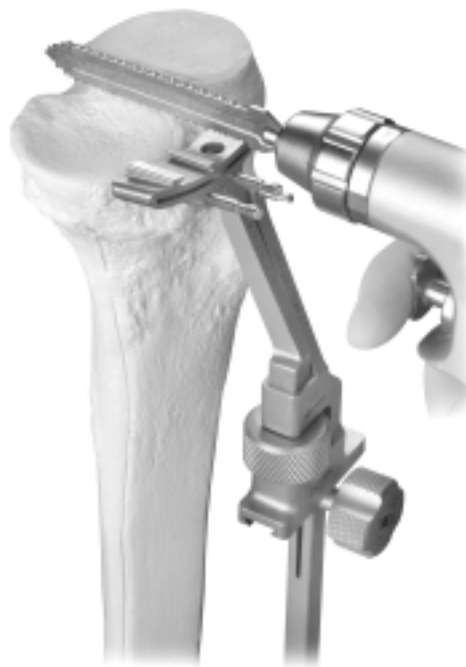

Fig. 19



#### **STEP FOUR: CHECK FLEXION/EXTENSION GAPS**

To assess the flexion and extension gaps, different Flexion/Extension Gap Spacers are available that correspond to the 8mm, 10mm, 12mm, and 14mm tibial articular surface thicknesses. The thick end of each spacer duplicates the combined thickness of the corresponding tibial and femoral components in extension. The thin end of each spacer simulates the thickness of the tibial component in flexion.

Check the extension gap by inserting the thick end of the 8mm Flexion/Extension Gap Spacer into the joint (Fig. 20).

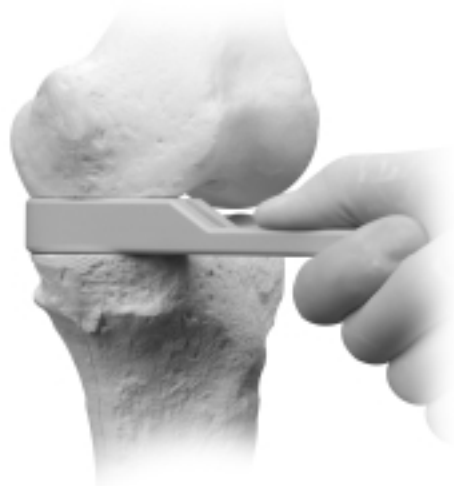


Fig. 20

Remove the Flexion/Extension Gap Spacer and flex the knee. Check the flexion gap by inserting the thin end of the selected Flexion/Extension Gap Spacer into the joint (Fig. 21).

If, in both flexion and extension, the joint space is too tight to insert the 8mm Flexion/Extension Gap Spacer, then more tibial bone must be removed. Then use the Flexion/Extension Gap Spacers to recheck the gaps.

If in both flexion and extension the joint space is too loose, insert progressively thicker Flexion/Extension Gap Spacers and repeat the gap checking.

If tight in extension and acceptable in flexion, two options may be pursued:

- 1) recut proximal tibia with less tibial slope
- 2) recut 1mm - 2mm of distal femur

After any adjustment of the flexion and/or extension gap is made, use the Flexion/Extension Gap Spacers to recheck the gaps.

**Verifying the gaps at this stage of the procedure will reduce the likelihood of a gap imbalance during the trial reduction.**

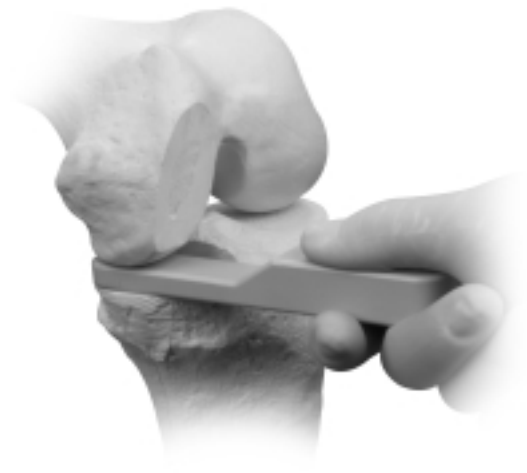

Fig. 21

## STEP FIVE: SIZE THE FEMUR

There are seven sizes of femoral implants and corresponding sizes of Femoral Sizer/Finishing Guides. The outside contour of the Femoral Sizer/Finishing Guides matches the contour of the corresponding implant.

Insert the prongs on the Insertion Handle into the corresponding holes of the appropriate left or right Femoral Sizer/Finishing Guide (Fig. 22). Then thread the handle into the guide and tighten it securely (Fig. 23).



Fig. 22

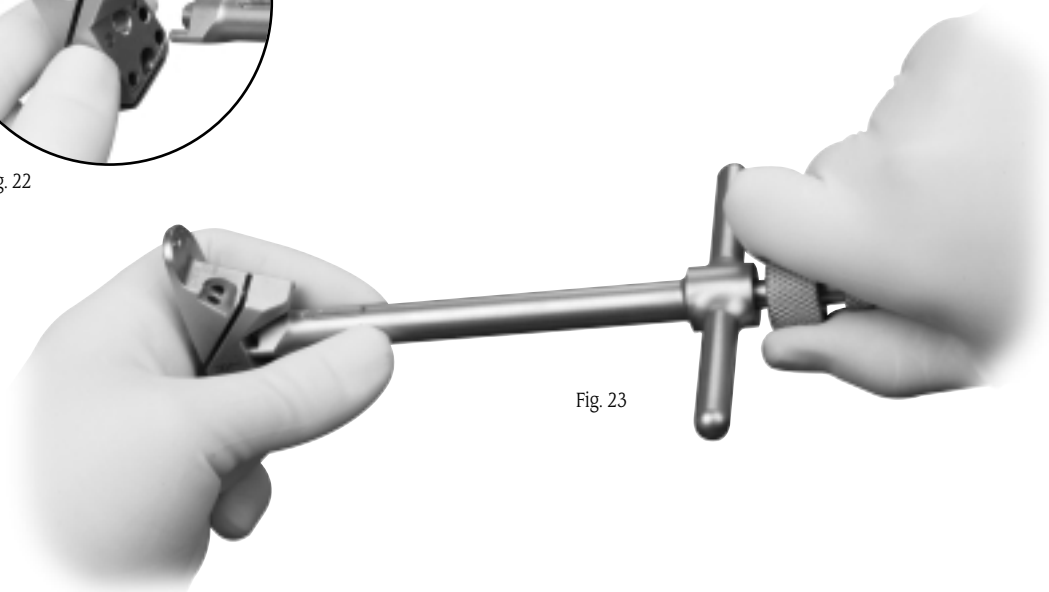


Fig. 23



Insert the foot of the guide into the joint and rest the flat surface against the cut distal condyle. Pull the foot of the guide anteriorly until it contacts the cartilage/bone of the posterior condyle. There should be 2mm-3mm of exposed bone above the anterior edge of the guide (Fig. 24). Repeat with additional guides until the proper size is selected (Fig. 25). If the condyle appears to be between two sizes, choose the smaller size. This helps prevent the patella from impinging on the prosthesis.

**Note:** *Be sure that there is no soft tissue or remaining osteophytes between the Femoral Sizer/Finishing Guide and the cut distal condyle. It is important that the Femoral Sizer/Finishing Guide sits flush against the bone. Any gaps between the guide and the bone will compromise the accuracy of the cuts and, subsequently, component fit may be compromised. Do not allow the patella to cause improper alignment of the guide. The patella may move the finishing guide medially in a medial UKA.*

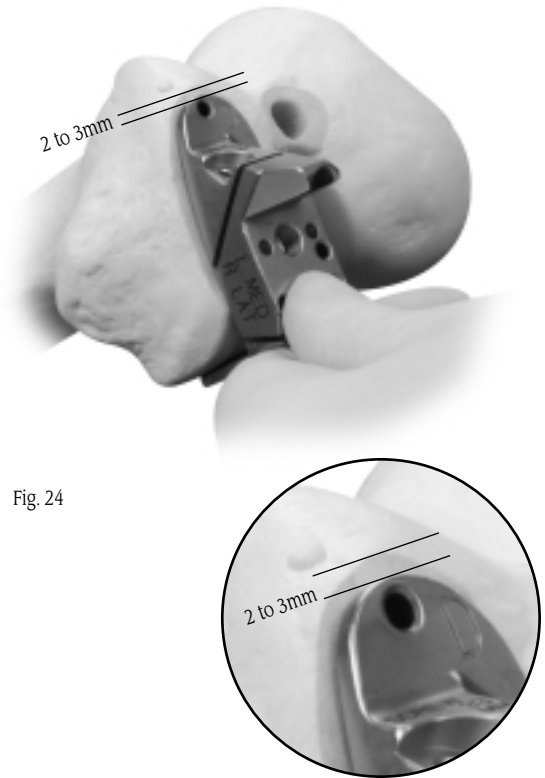
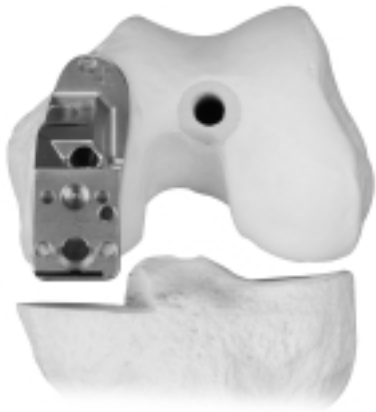
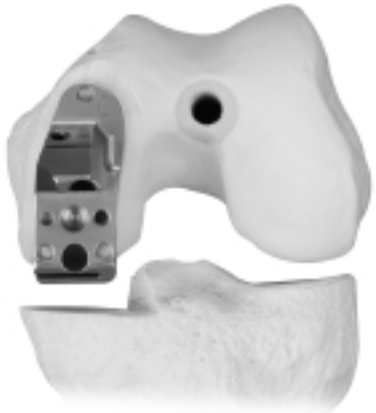
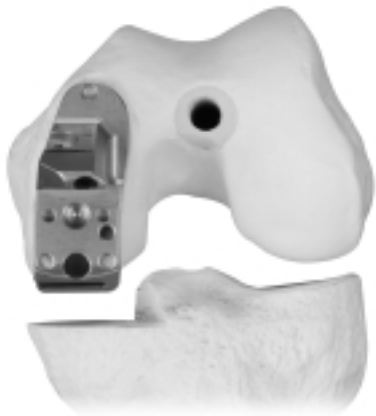Fig. 24



Too Large



Too Small



Just Right

Fig. 25







## STEP SIX: FINISH THE FEMUR

The following order is recommended to maximize the stability and fixation of the Femoral Sizer/Finishing Guide. This will help ensure that the cuts and holes are precise.

1. With the proper size Femoral Sizer/Finishing Guide in position, insert a 48mm Headed Screw into the top pin hole, or predrill and insert a Holding Pin (Fig. 26). Rotate the guide on the screw/pin until the posterior edge of the guide is parallel to the cut surface of the tibia (Fig. 27). Make sure there is exposed bone on both sides of the guide to ensure that the Femoral Sizer/Finishing Guide does not overhang.

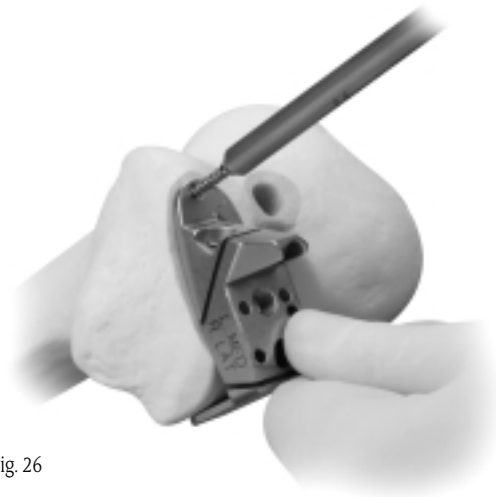


Fig. 26




Fig. 27

2. Insert one 33mm Headed Screw (gold head) into the angled anterior pin hole, which is parallel to the chamfer cut (Fig. 28). For best fixation, seat the screw head slowly. This should stabilize the guide sufficiently to finish the femur. For additional stability, insert a 48mm Headed Screw or predrill and insert a Short Head Holding Pin into the middle hole closest to the intercondylar notch. If this hole is used, it will be necessary to remove the Femoral Sizer/ Finish Guide before finishing the femoral cuts.

**Note:** For Femoral Sizer/Finishing Guide sizes A and B, the angle of the pin hole is different from the larger sizes. This is due to the relative difference in the size of the pegs on the size A and B femoral components, and does not affect the technique.

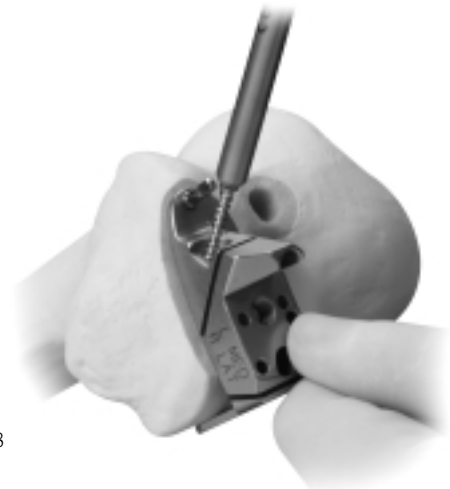


Fig. 28



3. Insert the Femoral Drill w/Stop into the anterior post hole, and orient it to the proper angle (Fig. 29). **Do not attempt to insert or align the drill bit while the drill is in motion.** When the proper alignment is achieved, drill the anterior post hole and, if necessary, insert a Femoral Holding Peg for additional stability.
4. Drill the posterior post hole in the same manner. This hole is angled the same as the anterior post hole (Fig. 30).



Fig. 29



Fig. 30

5. Remove the anterior Femoral Holding Peg and cut the posterior chamfer through the cutting slot in the guide. If a screw/pin was inserted into a middle hole, either remove the screw/pin or cut around it. The remaining island of bone can then be resected after removing the Femoral Sizer/Finishing Guide. If posterior screws/pins were used, cut until the saw blade almost contacts the screws/pins (Fig. 31).

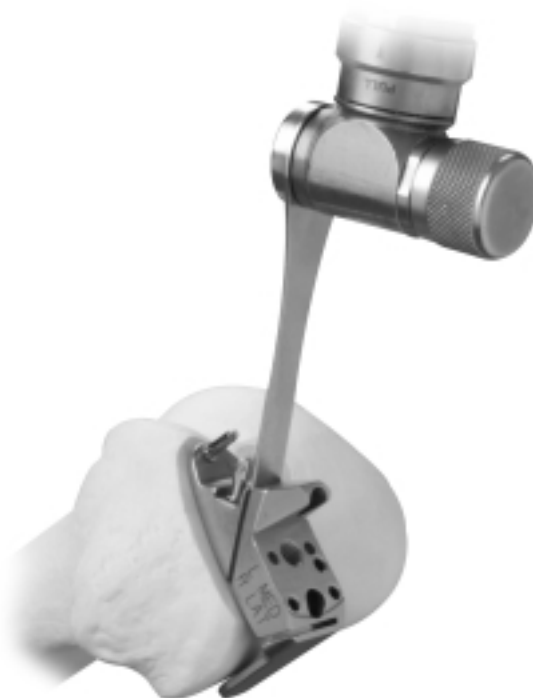

Fig. 31



6. Cut the posterior condyle through the cutting slot in the guide (Fig. 32).
7. Remove the screws/pins and the Femoral Sizer/Finishing Guide, and finish any incomplete bone cuts.
8. Ensure that all surfaces are flat. Remove any prominences or uncut bone.

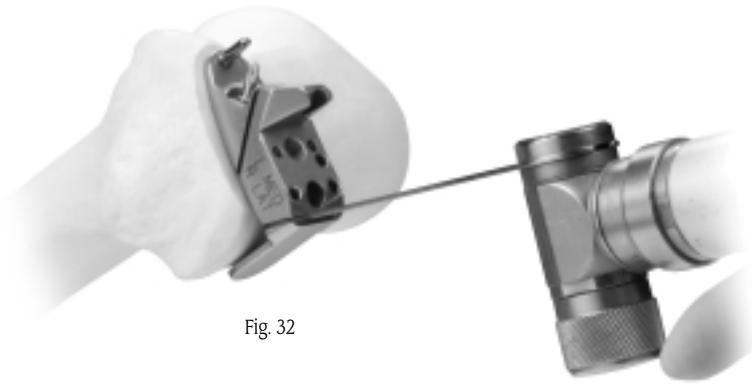


Fig. 32

Debride the joint and inspect the posterior condyle. **If any prominent spurs or osteophytes are present, especially in the area of the superior posterior femoral condyle, remove them with an oscillating saw or an osteotome, as they could inhibit flexion or extension (Fig. 33).**

**Technique Tip**

*The Femoral Provisional may be put in place and the knee flexed. This would aid in identifying and removing any residual posterior condylar bone which could limit flexion.*

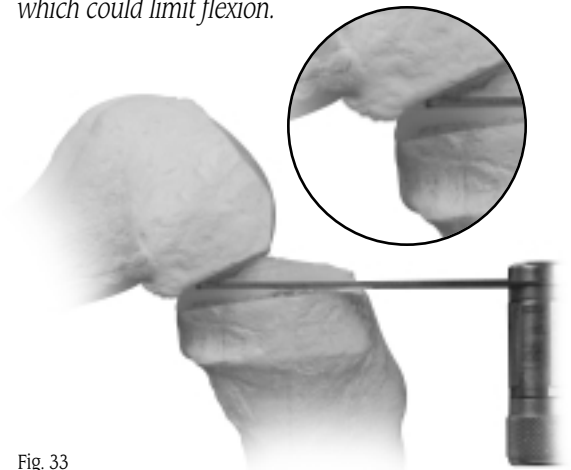


Fig. 33

## STEP SEVEN: FINISH THE TIBIA

Resect the remaining meniscus and remove any osteophytes, especially those interfering with the collateral ligament.

Place the head of the Tibial Sizer on the cut surface of the tibia with the straight edge against the surface created by the sagittal cut. Verify the proper rotation of the sagittal cut in the transverse plane. The rotation is correct when the sizer handle is 90° to the coronal plane (Fig. 34). Select the Tibial Sizer that best covers the resected proximal tibia in both the A/P and M/L dimensions. If desired, use the resected tibial bone fragment as an aid in sizing. If necessary, a second sagittal cut can be made to allow for optimal coverage with the next larger size tibial base plate.

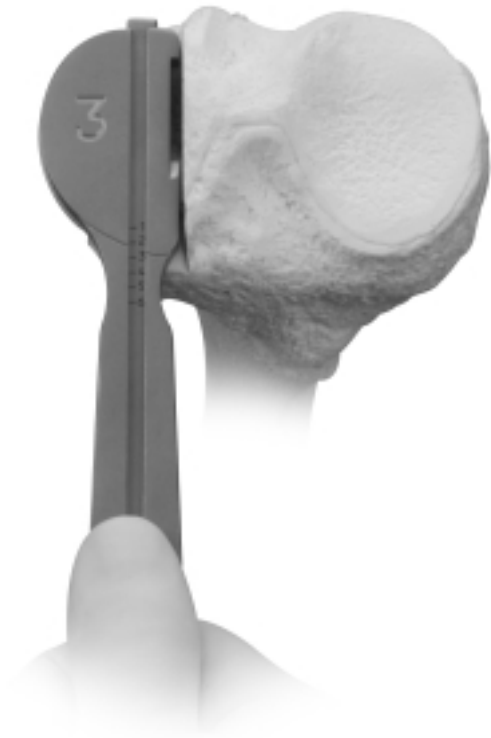

Fig. 34

The Tibial Sizer has a sliding ruler which facilitates measuring in the A/P dimension (Fig. 35). Be sure that the head of the sizer rests on cortical bone near the edge of the cortex around its entire perimeter. **Be sure that it does not overhang.** Pull the Tibial Sizing Slider anteriorly until the hook on the tip of the slider contacts the posterior edge of the tibia (Fig. 36).

### *Technique Tip*

*Clean the edge of the bone cut with a curette so the sizer will fit flush against the cut.*

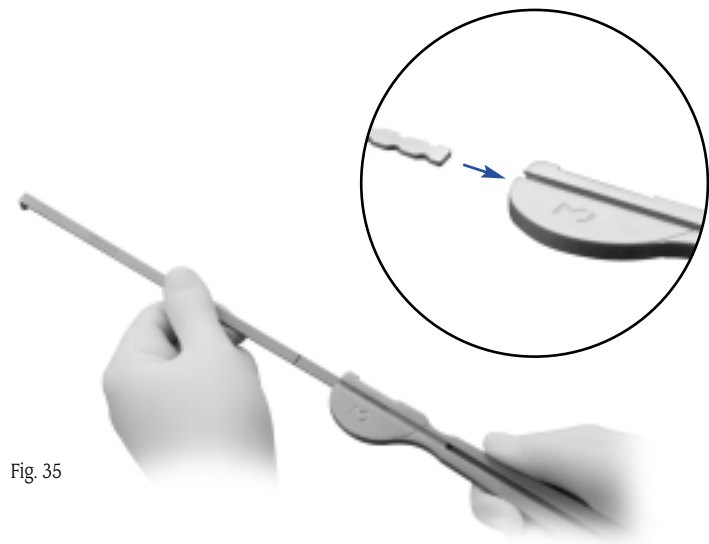


Fig. 35

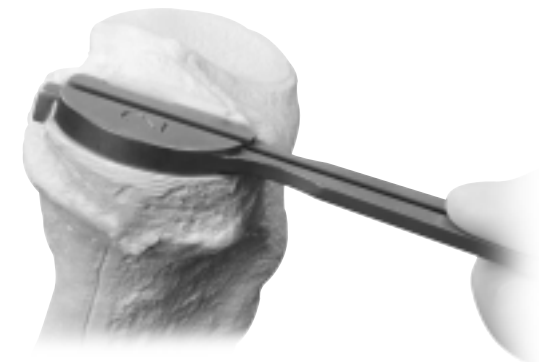


Fig. 36





There are a number of indicators on the Tibial Sizer. If the slider is used without the sizer, the etch marks 1 through 6 on the slider indicate the A/P length of the corresponding implant. If the slider is used with the sizer, the A/P length is indicated on the sizer handle (Fig. 37). An additional measurement on the slider at the tip of the sizer handle indicates the length of exposed bone posteriorly (behind the implant) with the sizer head in this particular position (Fig. 37). Also, the cutout on the straight edge of the sizer head indicates the location of the tibial keel for marking.

Remove the Tibial Sizer. Then remove all soft tissue debris from the popliteal region.

**Technique Tip**

*To facilitate insertion of the Tibial Fixation Plate Provisional, externally rotate the tibia while the knee is flexed.*

Place the corresponding size Tibial Fixation Plate Provisional onto the cut surface of the tibia. Insert the Tibial Plate Impactor into the recess on the provisional and impact it so the central fin engages the bone and the provisional sits flush on the tibial surface (Fig. 38).

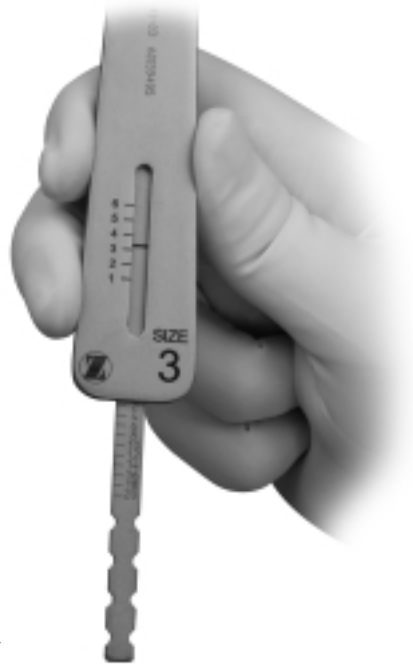

Fig. 37



Fig. 38



Predrill and insert a 17mm Short-head Holding Pin (00-5977-056-02) into the anterior fixation hole (Fig. 39).

Use the Tibial Drill w/Stop to drill the two tibial peg holes (Fig. 40). **Note that these holes are angled 20° posteriorly** to facilitate drilling. Although the pegs on the implant are at 90°, the drill is designed so that the pegs will fit into these angled holes.

Leave the Tibial Fixation Plate Provisional in place on the bone.

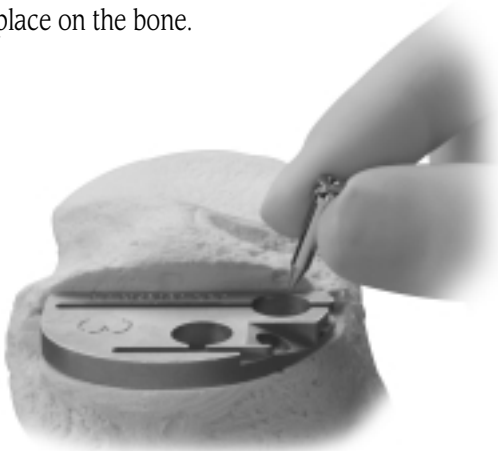


Fig. 39

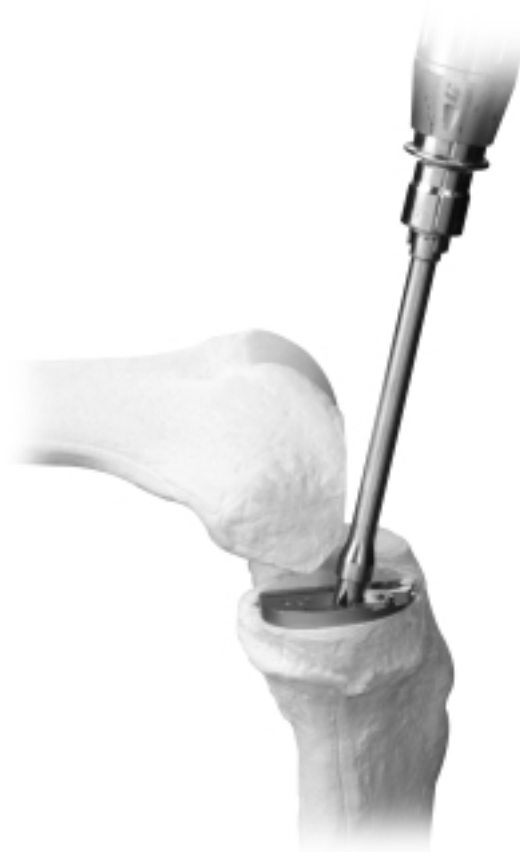

Fig. 40





## STEP EIGHT: PERFORM TRIAL REDUCTION

Remove the IM Patellar Retractor. With all bone surfaces prepared, perform a trial reduction with the appropriate size Femoral Provisional, Tibial Fixation Plate Provisional, and Tibial Articular Surface Provisional. The Concave Tibial Spacer can be used in place of the combined Tibial Fixation Plate Provisional and Tibial Articular Surface Provisional.

Insert the prongs on the Insertion Handle into the corresponding holes on the Femoral Provisional (Fig. 41). Thread the handle into the provisional and tighten it securely.




Fig. 41

To help guide the femoral provisional past the patella, place the leg in deep flexion to begin the insertion. Insert the long post first. Then adjust the leg to a midflexion position, rotating the provisional around and in back of the patella. Reposition the leg in deep flexion to complete the insertion. Impact the provisional onto the femur with a mallet (Fig. 42).

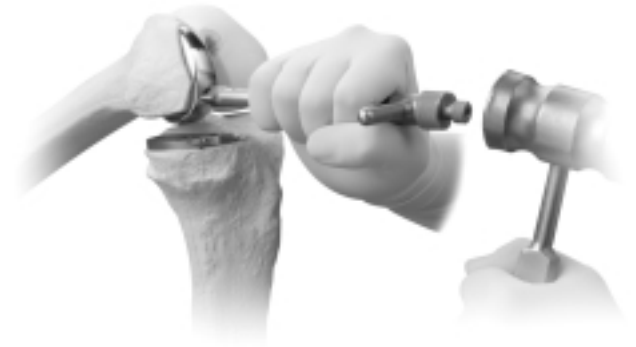

Fig. 42

Slide the rails on the bottom of the Tibial Articular Surface Provisional into the grooves on the Tibial Fixation Plate Provisional (Fig. 43). Check the fit of the provisional components. If necessary, perform minor trimming of bone surfaces.

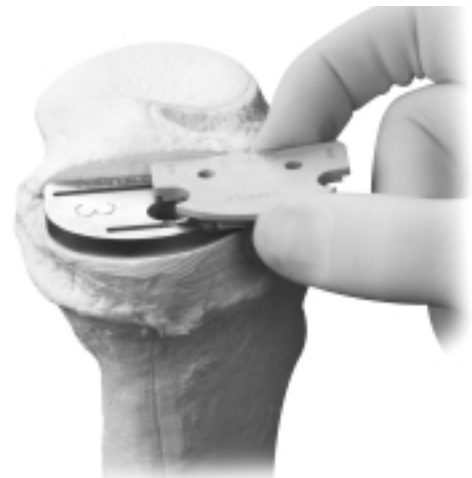


Fig. 43



With all trial components in place, check for proper range of motion and ligament stability. The Tibial Articular Surface Provisional or Concave Tibial Spacer used should permit full flexion and full extension. Overstuffing should be avoided, as this will transfer stress to the contralateral compartment.

Evaluate soft tissue tension in flexion and extension. Use the 2mm end of the Tension Gauge to help ensure that flexion and extension gaps are not too tight (Figs. 44).

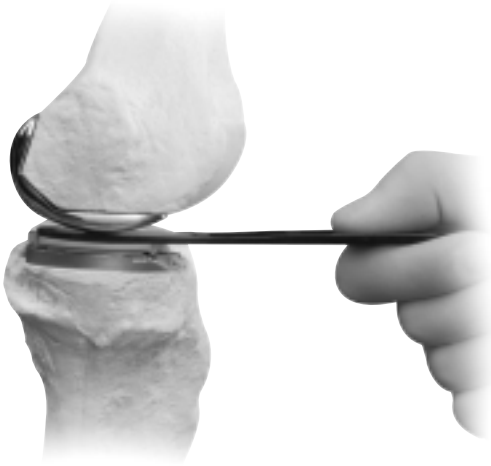

Fig. 44

The correct thickness of the prosthesis is one that produces the desired alignment and does not cause excessive stress on the collateral ligaments. As a rule, the correct prosthesis should allow the joint space to be opened approximately 2mm when a stress is applied, with the knee in full extension and without soft tissue release.

The knee must also be tested in 90° of flexion to allow a 2mm flexion gap. Excessive flexion tightness will prevent postoperative flexion and may cause the tibial prosthesis to lift up anteriorly as the femoral component rolls posteriorly on the tibial component. If the joint is too tight in flexion, try using a thinner tibial articular surface component or increasing the posterior slope of the tibial resection.

**Technique Tip**

*Use the 2mm end of the Tension Gauge to help balance the knee in both flexion and extension. With the knee flexed 90°, position the 2mm end of the Tension Gauge between the Femoral Provisional and the Concave Tibial Spacer. This should be a snug, but not an overly tight fit. Then use the same test with the knee in full extension.*



## STEP NINE IMPLANT FINAL COMPONENTS

Obtain the final components and implant the tibial component first.

### *Technique Tip*

*With the modest amount of bone removed, particularly from the tibia, there may be a sclerotic cut surface. If the resected surfaces of the tibia and/or femur are sclerotic, drill multiple holes with a small drill (2.0mm-3.2mm) to improve cement intrusion.*

### **Tibial Component**

To facilitate insertion, flex the knee and externally rotate the tibia. If desired, place an opened and slightly moist sterile gauze sponge behind the tibia before implanting the components to help collect excess cement behind the tibia.

Apply cement and press the tibial base plate or the all-polyethylene tibial component onto the tibia. Position and press down the posterior portion of the component first. Then press the anterior portion of the component, expressing excess cement anteriorly.

Use the Tibial Plate Impactor to impact the tibial base plate (Fig. 45).

**Note:** Do not use the Tibial Plate Impactor to impact an all-polyethylene tibial component.

Remove the sterile gauze sponge slowly from behind the joint, and use the Cement Removal Tool to remove any excess cement.



Fig. 45



## Femoral Component

Apply cement and begin the femoral component insertion with the leg in deep flexion. Insert the long post first. Adjust the leg to a midflexion position, rotating the implant around and in back of the patella. Then reposition the leg in deep flexion and seat the component with the Femoral Impactor (Fig. 46).



Fig. 46

If using a modular tibial component, confirm the correct size and thickness of the final tibial articular surface by testing with the Tibial Articular Surface Provisionals in maximum flexion and extension. Use the Tension Gauge to assess the flexion and extension gaps. Then recheck alignment to verify that the joint has not been overcorrected.

## Tibial Articular Surface

After the cement has cured, remove any remaining excess cement before the final placement of the tibial articular surface. **Do not proceed with locking the final articular surface component until cement has fully cured.**

With the engraved side down, slide the edge of the polyethylene component under the posterior lip of the base plate. Then insert the tab on the lower jaw of the Tibial Articular Surface Inserter into the notch on the front of the tibial base plate. Bring the polyethylene tip on the upper jaw of the inserter down until it contacts the articular surface implant. Squeeze the handles of the inserter together until the articular surface implant snaps into place (Fig. 47).

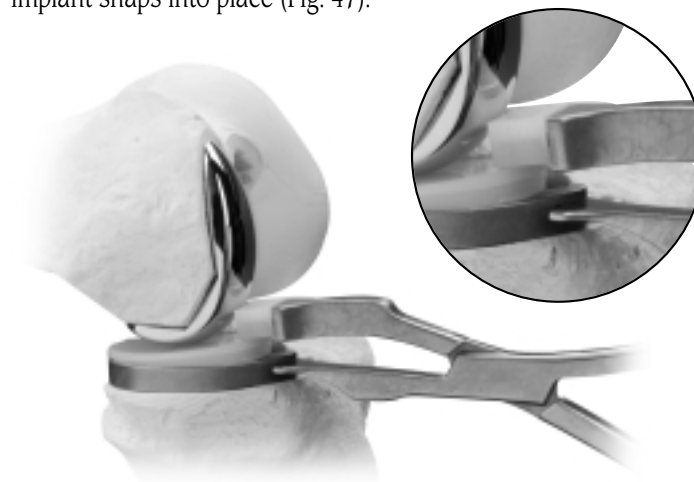


Fig. 47

## CLOSURE

Irrigate the knee for the final time and close. Cover the incision with a sterile dressing and wrap the leg with an elastic bandage from the toes to the groin.

# SPACER BLOCK

## SPACER BLOCK OPTION

After resecting the proximal tibia, bring the knee to full extension. Insert the 8mm Spacer Block into the joint space until the anterior stop contacts the anterior tibia (Fig. 1). The Spacer Block must be fully inserted and sit flat on the resected tibial surface to ensure that the proper amount of femoral bone will be resected.

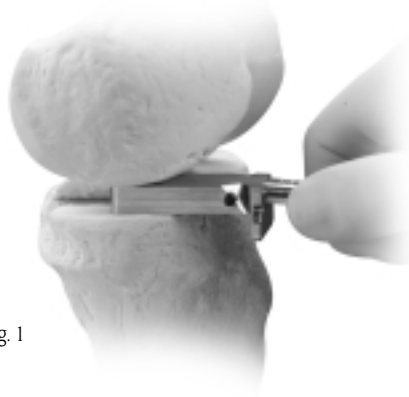


Fig. 1

If the 8mm Spacer Block will not fit into the joint, remove an additional 2mm from the proximal tibia. If the 8mm Spacer Block is too loose, use a thicker Spacer Block.

Insert a 48mm Headed Screw or predrill and insert a Short-head Holding Pin into the anteromedial angled hole in the Spacer Block (Fig. 2).

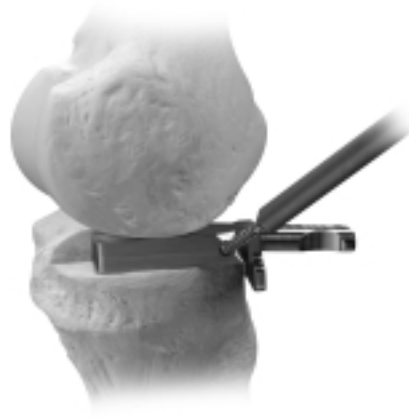

Fig. 2

Attach the Alignment Tower to the Spacer Block (Fig. 3) and insert the Alignment Rod through the Alignment Tower. Then insert the Targeting Guide onto the Alignment Rod, and position the guide relative to the femoral head to check alignment (Fig. 4).

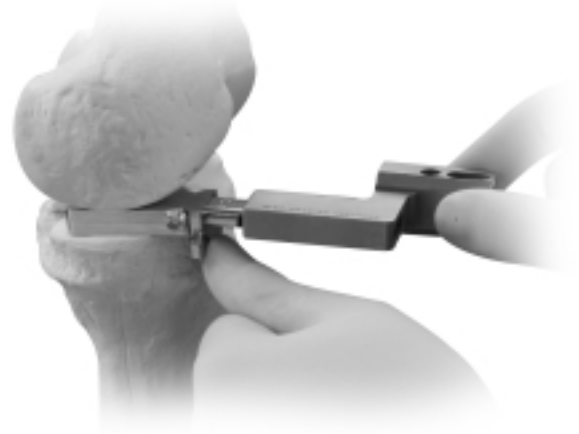

Fig. 3

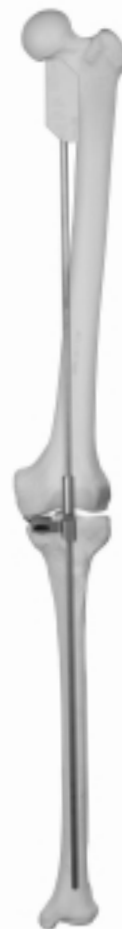

Fig. 4

The *Zimmer Unicompartmental High Flex Knee System* has been designed for 5° of posterior tibial slope. The angle on the handle of the Spacer Block is angled 5° relative to the Spacer Block. This ensures that the distal femoral resection is made perpendicular to the long axis of the femur.

Place the Distal Femoral Resector over the handle of the Spacer Block (Fig. 5). Then secure the guide by inserting a 48mm Headed Screw or predrill and insert a Holding Pin through the hole (Fig. 6).

Use a 1.27mm (0.050-inch) oscillating saw blade to resect the distal femur (Fig. 7). Do not extend the saw blade posteriorly past the distal femur to avoid damaging the posterior popliteal area. If desired, the femoral cut can be started in extension and finished in flexion. Before flexing the knee, remove the Distal Femoral Resector and Spacer Block. Then return to Check Flexion/Extension Gaps (Step 4) in the IM surgical technique.

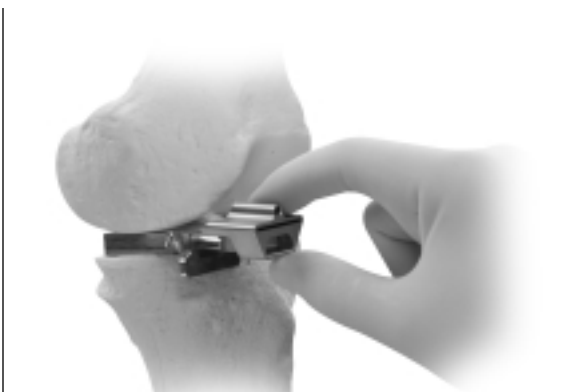

Fig. 5

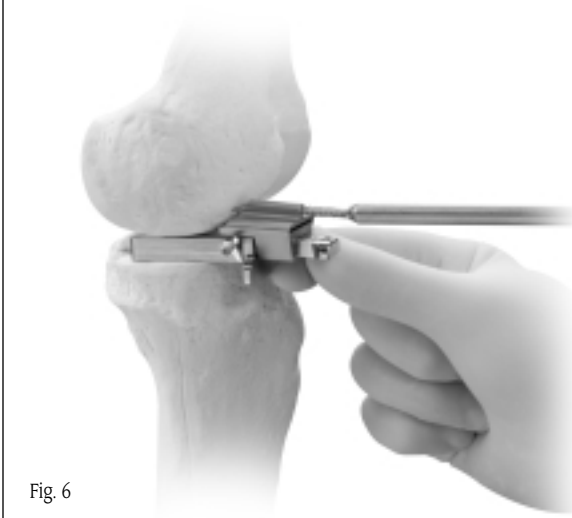

Fig. 6

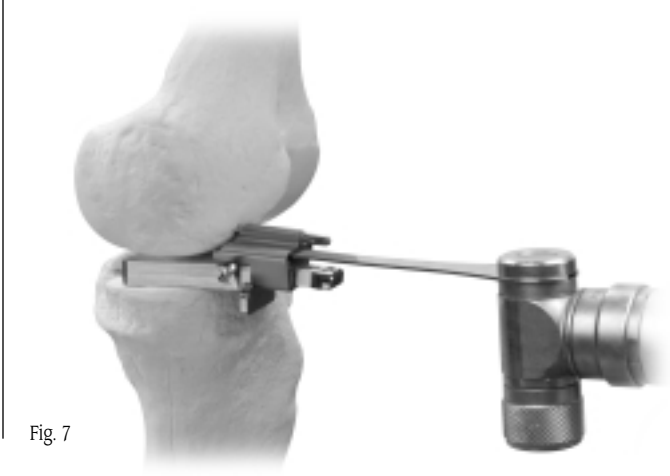

Fig. 7





# EXTRAMEDULLARY (EM) SURGICAL PROCEDURE

## INTRODUCTION

Unicompartmental knee arthroplasty (UKA) has been shown to be an effective treatment for isolated osteoarthritis affecting the medial or lateral compartment. The *M/G* Unicompartmental Knee System has long-term clinical success with 98% survivorship over a 6 to 10 year period.<sup>1</sup>

The *MIS* Instruments for the *Zimmer* Unicompartmental High Flex Knee System are designed to provide accurate, reproducible results using a minimally invasive technique. The goals of a minimally invasive surgical procedure are to:

- Facilitate the patient's recovery
- Provide less pain
- Provide earlier mobilization
- Provide shorter hospital stay
- Provide quicker rehabilitation

This instrumentation allows the surgeon to operate without everting the patella.

The system offers three *MIS* instrumentation options:

- Intramedullary Instrumentation System (IM)
- Spacer Block Option
- Extramedullary Instrumentation System (EM)

The same tibial assembly is used for all three options. However, the distal femoral resection instruments are unique to each of the three techniques.

This guide to the surgical technique is a step-by-step procedure written for a medial compartment UKA. Many of the same principles can be applied to the lateral compartment but it may be necessary to extend the incision a few centimeters given the proximity of the patella to the lateral condyle.

Combined with surgeon judgment, proper patient selection, and appropriate use of the device, this guide offers a comprehensive technique that discusses the procedure for component selection, bone preparation, trial reduction, cementing techniques, and component implantation. It is strongly recommended that the surgeon read the complete procedure for details, notes, and technique tips.



## RATIONALE

The basic goals of unicompartmental knee arthroplasty are to improve limb alignment and function, and to reduce pain. Routinely, an effort is made to minimize disruption of the surrounding soft tissue during the procedure. The development of instruments specifically designed to be used through a smaller exposure has had a significant impact on this effort.

Accurate limb alignment is described by the mechanical axis of the lower extremity, which is a straight line running from the center of the femoral head to the center of the ankle. When the center of the knee lies on this mechanical axis, the knee is said to be in neutral alignment. Unicompartmental knee disease typically reduces the joint space in the affected compartment, causing a malalignment of the joint. Full correction of the malalignment would return the knee to neutral alignment. (Fig. 1)

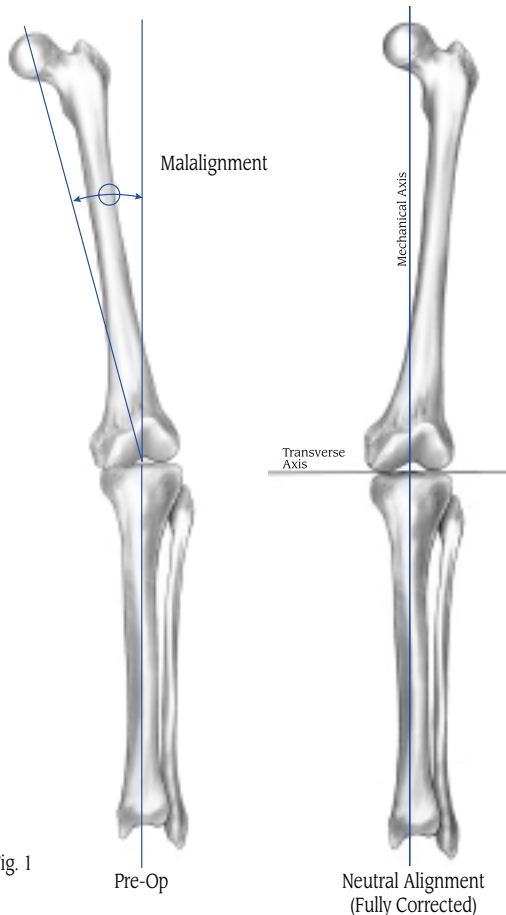


Fig. 1

The alignment goals for unicompartmental arthroplasty differ from those that are customary in high tibial osteotomy (HTO) where overcorrection is desirable to displace the weight-bearing forces away from the diseased compartment. In contrast, when adjusting limb alignment in a unicompartmental procedure, **it is particularly important to avoid overcorrection of the limb** as this may increase the stress in the contralateral compartment and heighten the potential for cartilaginous breakdown. Studies of unicompartmental procedures have shown that slight undercorrection of the limb alignment correlates to long-term survivorship.<sup>2</sup>

It is important to recognize that the methods used to adjust alignment in TKA are very different from those used in unicompartmental arthroplasty. In TKA, the angle of the femoral and tibial cuts determine the postoperative varus/valgus alignment. In UKA, the angle of the cuts does not affect varus/valgus alignment. **Instead, postoperative varus/valgus alignment is determined by the composite thickness of the prosthetic unicompartmental components.**

When using the extramedullary instruments, the angle between the anatomic and mechanical axes of the femur does not need to be measured. In the EM technique, the leg is manually aligned in extension, allowing the surgeon to visualize and adjust the alignment to the desired slight degree of undercorrection. The desired soft tissue tension is determined by the surgeon during this passive correction of limb alignment. As the distal femoral cut and proximal tibial cut are linked in extension, limb alignment is determined and set before committing to any cuts. Thus, **alignment is achieved first**, and the instruments will adjust to accommodate the appropriate implant sizing and positioning.



Once the alignment has been set, the instrumentation allows reproducible bone resection of the articular surfaces. The distal femoral and proximal tibial cuts are achieved by linked resection guides. The cuts are therefore parallel and result in a preset space that is calculated to match the thickness of the implants and reproduce the selected alignment. These linked, precise cuts reduce the potential need for recutting and may help to preserve tibial bone stock. Because the tibial resection level corresponds to the selected polyethylene thickness, the likelihood of needing a tibial articular surface that is between available component thicknesses is reduced.

Also, the EM instruments eliminate the need for intrusion into the medullary canal. By not drilling the canal, the associated blood loss and possibility of fat embolism are reduced.

## PREOPERATIVE PLANNING

This technique is written with the distal femoral resection performed first. However, if preferred, the tibia can be resected first. With either option, the tibial apparatus must be assembled and applied to the tibia first. Steps three and four can then be performed in the order preferred.

Take standing weight-bearing A/P and lateral radiographs of the affected knee, and a skyline radiograph of the patella. Then take a supine A/P radiograph showing the center of the femoral head, the knee, and as much of the tibia as possible (preferably including the ankle). This radiograph is used to determine limb malalignment.

The goal of the procedure is to establish mechanical alignment that is slightly undercorrected relative to a neutral mechanical axis (see Fig. 1). **Do not overcorrect the alignment. It is better to be slightly undercorrected than to risk overcorrection.**

An additional radiograph while stressing the limits of the tissues may be helpful in assessing the appropriate correction.

When evaluating the patient and planning for the procedure, consider TKA if:

- Degenerative changes are present in the contralateral compartment and/or the patellofemoral joint.
- The ACL is deficient.
- A significant flexion contracture exists.
- Slight undercorrection is not attainable.
- There is significant overcorrection with a valgus stress.
- There is an existing valgus or varus deformity  $\geq 15^\circ$ .

## PATIENT PREPARATION

With the patient in the supine position, test the range of hip and knee flexion. If unable to achieve  $120^\circ$  of knee flexion, a larger incision may be necessary to create sufficient exposure.

Wrap the ankle area with an elastic wrap. Do not place bulky drapes on the distal tibia, ankle, or foot. A bulky drape in this area will make it difficult to locate the center of the ankle, and will displace the Tibial Resector, which may cause inaccurate cuts.

Be sure that the proximal femur is accessible for assessing the femoral head location. Use anatomic landmarks to identify the location of the femoral head. Alternatively, the surgeon may prefer to reference the anterior-superior iliac spine.

### *Technique Tip*

*Place a marker, such as an EKG electrode, over the center of the femoral head. Then confirm the location with an A/P radiograph or fluoroscopy.*





## EXPOSURE

The incision can be made with the leg in flexion or extension, according to preference. Make a medial parapatellar skin incision extending from the medial pole of the patella to about 2cm-4cm below the joint line adjacent to the tibial tubercle (Fig. 2).

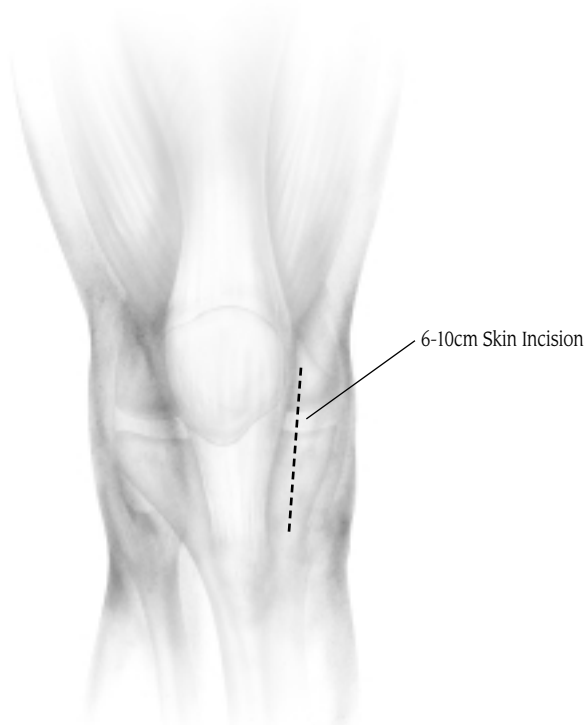

Fig. 2

Incise the joint capsule in line with the skin incision beginning just distal to the vastus medialis muscle and extending to a point distal to the tibial plateau (Fig. 3). Excise the fat pad, as necessary to facilitate visualization. Reflect the soft tissue subperiosteally from the tibia along the joint line back towards, but not into, the collateral ligament. Excise the anterior third of the meniscus. The remainder of the meniscus will be removed after bone resection.

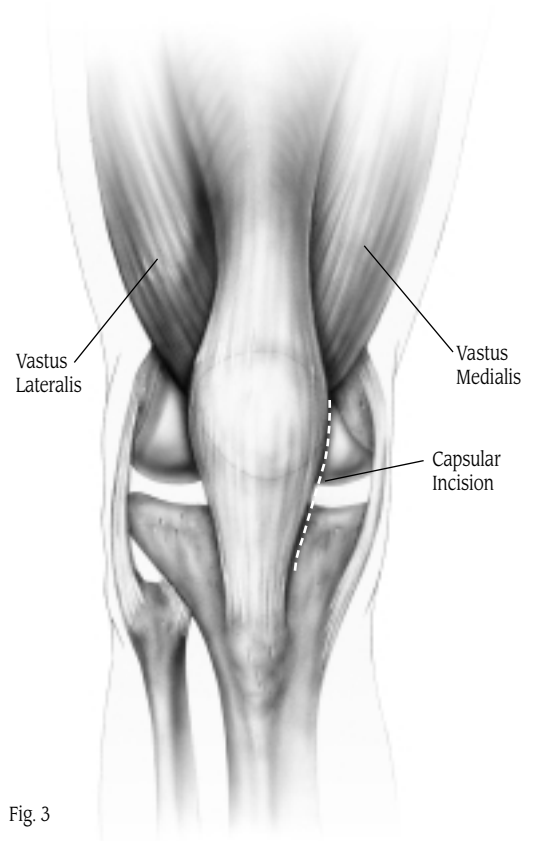


Fig. 3

A subperiosteal dissection should be carried out towards the midline, ending at the patellar tendon insertion. This will facilitate positioning of the tibial cutting guide.

Debride the joint and inspect it carefully. Remove intercondylar osteophytes to avoid impingement with the tibial spine or cruciate ligament. Also, remove peripheral osteophytes that interfere with the collateral ligaments and capsule. With medial compartment disease, osteophytes are commonly found on the lateral aspect of the medial tibial eminence and anterior to the origin of the ACL. Final debridement will be performed before component implantation. **Careful osteophyte removal may be important in achieving full extension.**





## STEP ONE: APPLY THE INSTRUMENTATION

With the knee in flexion, use an oscillating saw to resect the anterior tibial boss, being careful not to undercut the tibial articular surface (Fig. 4). Then extend the knee, and position a towel or “block” under the ankle to help maintain full extension.

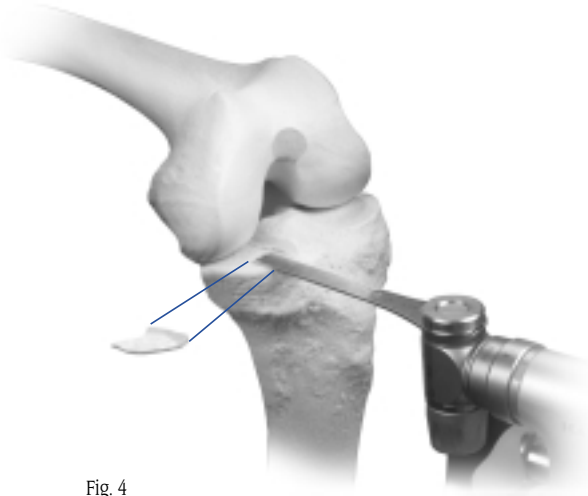


Fig. 4

The *Zimmer* Unicompartmental High Flex Knee System is designed for an anatomic position with a 5° posterior slope. It is important that the proximal tibial cut be made accurately. The tibial assembly consists of an Ankle Clamp, a Distal Telescoping Rod, a Tibial Resector Stem, a Tibial Resector Base, a Tibial Resector, and a Distal Femoral Resector (Fig. 5). **Positioning of the Tibial Resector and Distal Femoral Resector is crucial.**

## ASSEMBLE THE INSTRUMENT

Slide the Ankle Clamp onto the dovetail at the bottom of the Distal Telescoping Rod, and tighten the knob opposite the dovetail to temporarily hold the clamp in place. Then insert the appropriate length Tibial Resector Stem into the proximal end of the Distal Telescoping Rod and tighten the knob.

Attach the appropriate Tibial Resector to the corresponding Tibial Resector Base. Note that the resector and base are available in two configurations: LT MED/RT LAT and RT MED/LT LAT. Then slide the dovetail on the Tibial Resector Base onto the proximal end of the Tibial Resector Stem and tighten the knob on the stem. The dovetail provides a slide adjustment that allows M/L positioning.

The Distal Femoral Resector is available with a choice of paddle lengths and distal femoral depths. To resect 2mm less bone from the distal femoral condyle, attach the -2mm Distal Femoral Resector. Select the appropriate paddle length to ensure that the most prominent aspect of the distal femoral condyle is referenced. Attach the Distal Femoral Resector to the dovetail on the proximal end of the Tibial Resector and insert the Distal Femoral Resector Holding Peg.

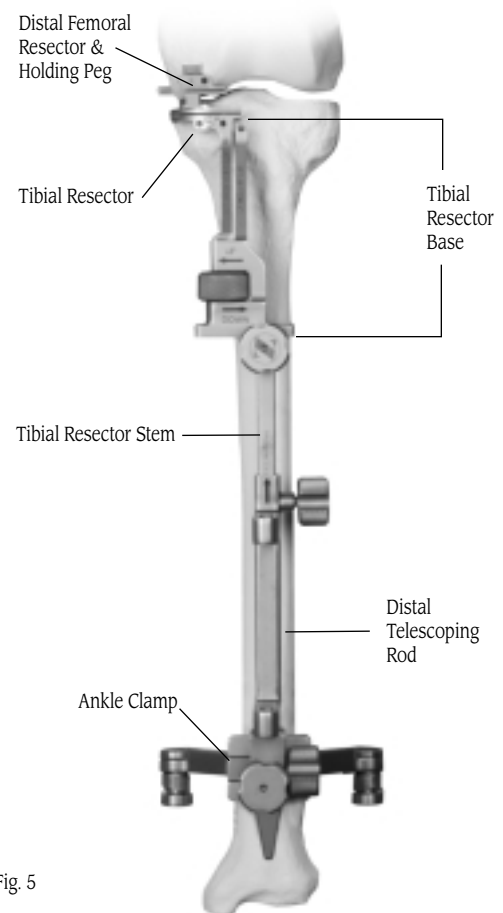


Fig. 5



## APPLY THE INSTRUMENT

Secure the distal portion of the assembly by placing the spring arms of the Ankle Clamp around the ankle proximal to the malleoli (Fig. 6). Loosen the knob at the top of the Distal Telescoping Rod and extend the proximal portion of the assembly to the joint line.

While applying a valgus stress to the leg, introduce the paddle of the Distal Femoral Resector into the affected compartment (Fig. 7). **Be sure that the paddle abuts the most distal aspect of the femoral condyle,** and that the Tibial Resector engages the anterior tibia. Then retighten the knob at the top of the Distal Telescoping Rod.

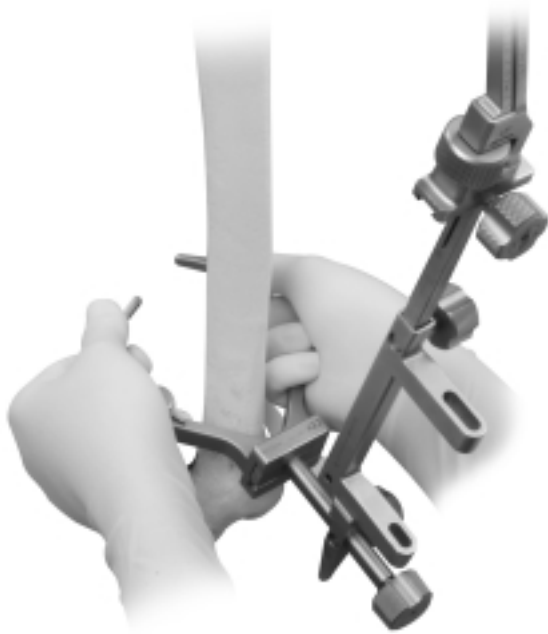


Fig. 6

### Technique Tip

*If the Distal Femoral Resector will not fit into the joint while attached to the assembly, remove the holding peg and resector. Then place the Tibial Resector against the tibia, and slide the Distal Femoral Resector onto the dovetail with the paddle inserted between the distal femoral condyle and proximal tibial plateau.*

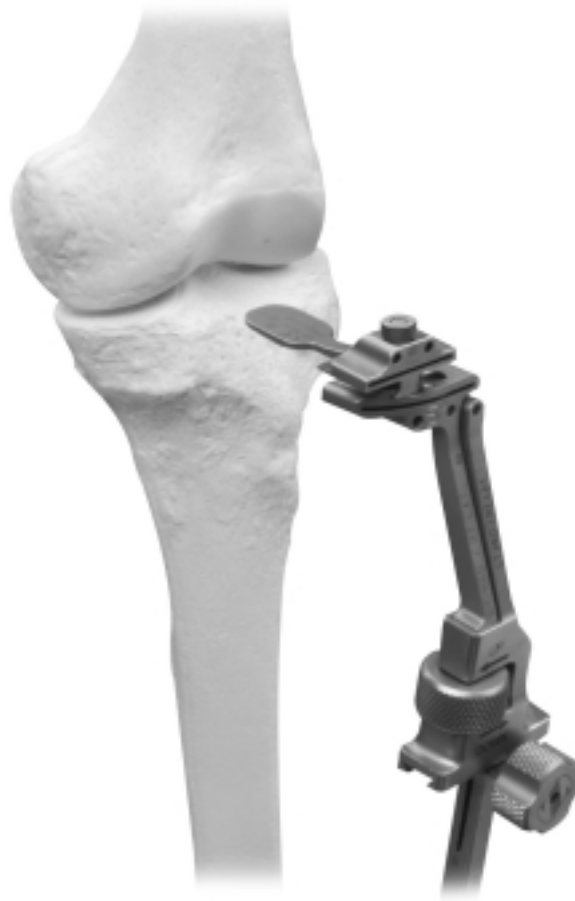

Fig. 7





While holding the proximal portion of the assembly in place, loosen the knob that provides mediolateral adjustment of the Distal Telescoping Rod. Adjust the distal end of the rod so it lies directly over the tibial crest. Then fully tighten the knob to secure it in place. This will help ensure that the proximal portion of the guide is parallel to the mechanical axis of the tibia. Mediolateral adjustments can also be made proximally, but the proximal portion will always remain parallel to the distal portion and, therefore, parallel to the mechanical axis of the tibia.

Use the M/L slide adjustment at the midshaft of the assembly to position the fixation arm of the Tibial Resector Base and Tibial Resector so it lies just medial to the midpoint of the tibial tubercle and is in line with the center of the intercondylar eminence (Fig. 8).

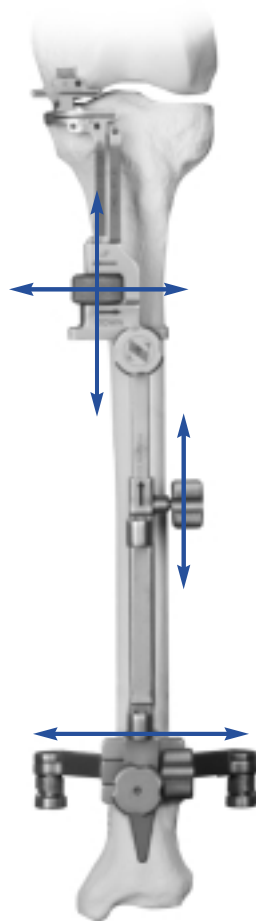


Fig. 8

In the sagittal plane, align the assembly so it is parallel to the anterior tibial shaft (Fig. 9) by using the A/P slide adjustment at the distal end of the Distal Telescoping Rod. Tighten the knob for the adjustment. If there is a bulky bandage around the ankle, adjust the assembly to accommodate the bandage. This will help with cutting the tibia in the proper slope.

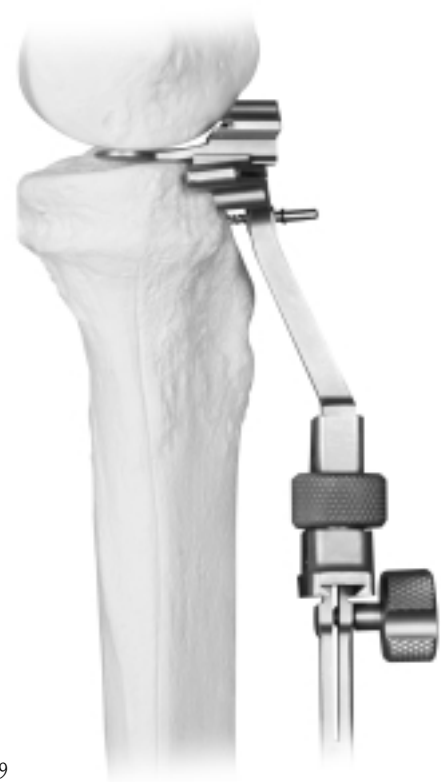

Fig. 9



**Optional Technique:**

*If the patient has a slight flexion contracture, cutting less posterior slope may help as it would result in less bone resection posteriorly than anteriorly, thereby opening the extension gap more relative to the flexion gap. This can be accomplished by moving the assembly closer to the leg distally. Then check the depth and angle of resection with the Resection Guide.*

Secure the assembly to the proximal tibia by inserting a 48mm Headed Screw, or predrilling and inserting a Holding Pin, through the hole in the fixation arm of the Tibial Resector Base (Fig. 10).

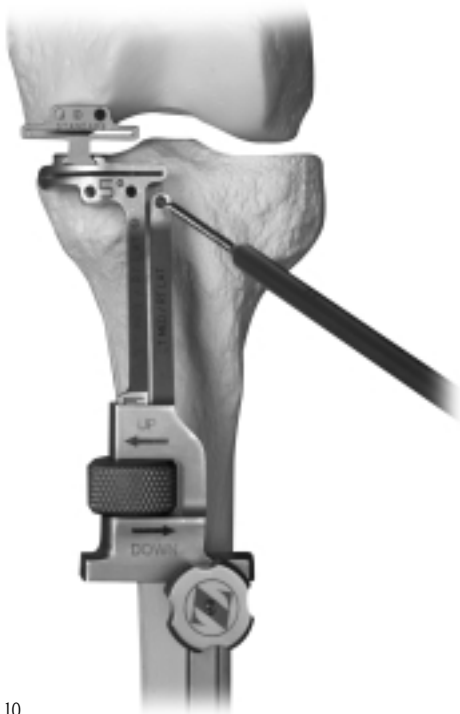

Fig. 10



## STEP TWO: ALIGN THE JOINT

*Note: Avoid aligning the limb in a way that may result in overcorrection. It is preferable to align the limb in slight varus for a medial compartment arthroplasty, or in slight valgus for a lateral compartment arthroplasty, rather than overcorrect the alignment.*

Manually correct the alignment of the leg. Ask an assistant to maintain the alignment, holding the joint open. Check the alignment of the assembly by inserting the Alignment Rod into the towers on the Distal Telescoping Rod. Attach the Targeting Guide to the proximal end of the Alignment Rod and position the guide near the femoral head (Fig. 11).

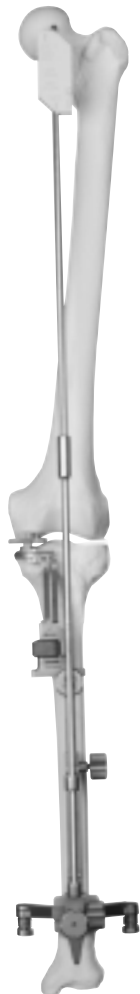

Fig. 11

While maintaining this corrected position, use the thumb screw on the Tibial Resector Base to move the cutting guides superiorly until the paddle on the Distal Femoral Resector contacts the distal femoral condyle. **It is important to manually hold the joint open and raise the paddle to meet the condyle rather than using the paddle to open the joint.** Once the paddle contacts the distal femoral condyle, the instrument will maintain the joint alignment without manual assistance.

Use the Holding Pin Pliers to remove the Distal Femoral Resector Holding Peg. Remove the Alignment Rods and Targeting Guide.

With the limb in full extension, secure the Distal Femoral Resector by predrilling and inserting Holding Pins, or inserting 48mm Headed Screws through the two holes (Fig. 12).

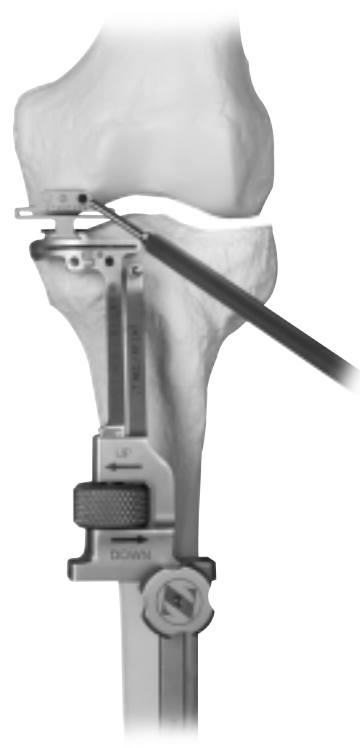

Fig. 12

Secure the Tibial Resector to the proximal tibia by predrilling and inserting Gold Headless Holding Pins, or inserting 48mm Headless Holding Screws, through the two holes (Fig. 13). Use electrocautery or the reciprocating saw to score the tibial surface where the sagittal cut will be made. Check this point both in extension and flexion.

If desired, the depth of both the femoral and tibial cuts can be verified by inserting the Resection Guide through the cutting slots (Fig. 14).

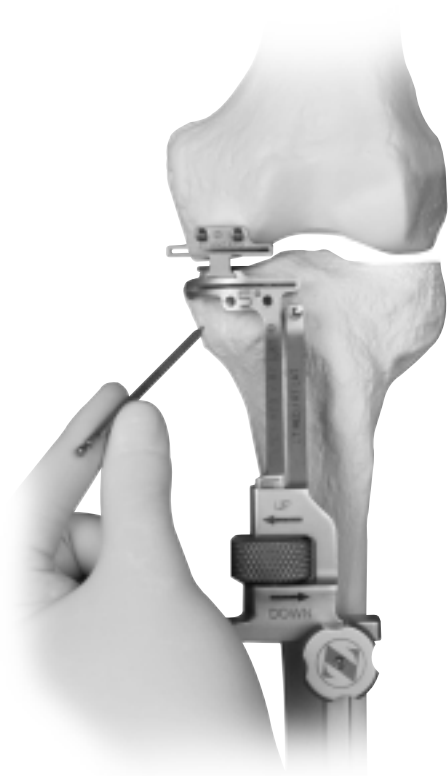


Fig. 13

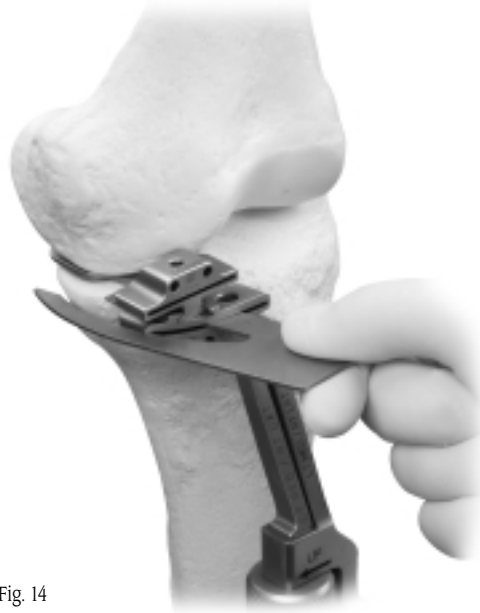

Fig. 14





### STEP THREE: RESECT THE DISTAL FEMORAL CONDYLE

Insert a retractor medially to protect the medial collateral ligament. Using a narrow, 1.27mm (0.050-inch) thick oscillating saw blade, resect the distal femoral condyle through the slot in the Distal Femoral Resector (Fig. 15). To avoid damaging the posterior popliteal area, do not extend the saw blade beyond the posterior margin of the femoral condyle while the knee is in extension. Begin the femoral cut with the knee in extension. Before flexing the knee, use the

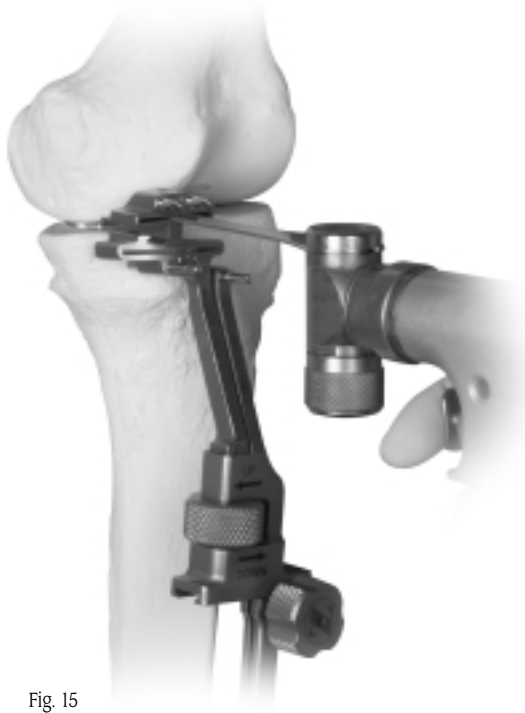

Fig. 15

Removal Hook to remove the Distal Femoral Resector (Fig. 16) by sliding it over the headless pins or screws, or by removing the headed pins or screws.

**Note:** *If completing the distal femoral cut after removing the Distal Femoral Resector, the cut must be finished with the knee in flexion.*

Check to ensure that the distal bone cut is flat. Remove any prominent bone to allow subsequent instruments to sit flat on the bone surface.

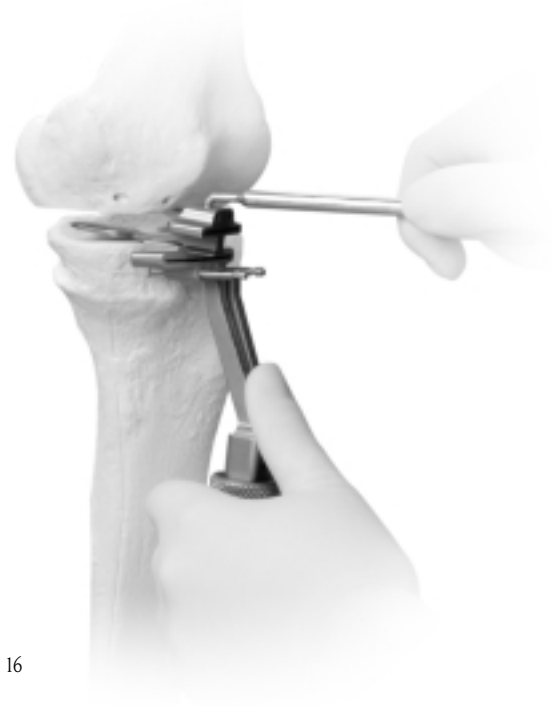

Fig. 16



## **STEP FOUR: RESECT THE PROXIMAL TIBIA**

Use a 1.27mm (0.050-inch) oscillating saw blade through the slot in the Tibial Resector to make the transverse cut. The Tibial Resector must remain against the bone during resection.

Make the sagittal cut with the knee flexed. Position the reciprocating saw blade at the base of the tibial eminence, and parallel to the eminence in the A/P plane. Cut along the edge of the ACL down to, but not beyond, the intended level of the transverse cut (Fig. 17). Be careful to avoid the ACL attachment.

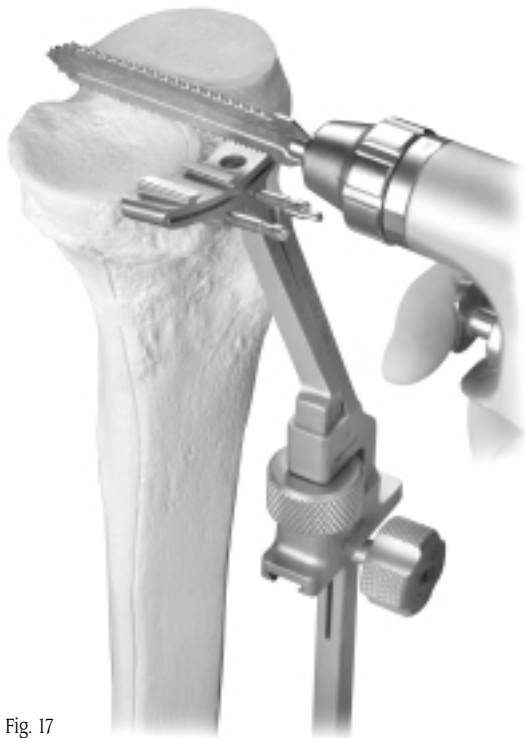


Fig. 17

When the tibial preparation is complete, remove the tibial assembly.





## **STEP FIVE: CHECK FLEXION/EXTENSION GAPS**

To assess the flexion and extension gaps, different Flexion/Extension Gap Spacers are available that correspond to the 8mm, 10mm, 12mm, and 14mm tibial articular surface thicknesses. The thick end of each spacer duplicates the combined thickness of the corresponding tibial and femoral components in extension. The thin end of each spacer simulates the thickness of the tibial component in flexion.

Check the extension gap by inserting the thick end of the 8mm Flexion/Extension Gap Spacer into the joint (Fig. 18).

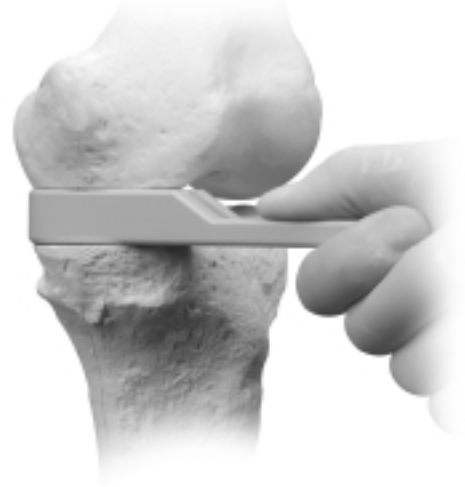


Fig. 18

Remove the Flexion/Extension Gap Spacer and flex the knee. Check the flexion gap by inserting the thin end of the selected Flexion/Extension Gap Spacer into the joint (Fig. 19).

If, in both flexion and extension, the joint space is too tight to insert the 8mm Flexion/Extension Gap Spacer, then more tibial bone must be removed. Then use the Flexion/Extension Gap Spacers to recheck the gaps.

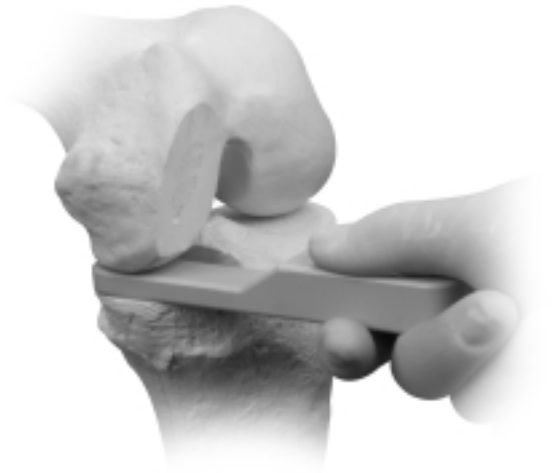


Fig. 19

If in both flexion and extension the joint space is too loose, insert progressively thicker Flexion/Extension Gap Spacers and repeat the gap checking.

If tight in extension and acceptable in flexion, two options may be pursued:

- 1) recut proximal tibia with less tibial slope
- 2) recut 1mm - 2mm of distal femur

After any adjustment of the flexion and/or extension gap is made, use the Flexion/Extension Gap Spacers to recheck the gaps. **Verifying the gaps at this stage of the procedure will reduce the likelihood of a gap imbalance during the trial reduction.**





## STEP SIX: SIZE THE FEMUR

There are seven sizes of femoral implants and corresponding sizes of Femoral Sizer/Finishing Guides. The outside contour of the Femoral Sizer/Finishing Guides matches the contour of the corresponding implant.

Insert the prongs on the Insertion Handle into the corresponding holes of the appropriate left or right Femoral Sizer/Finishing Guide (Fig. 20). Then thread the handle into the guide and tighten it securely (Fig. 21).



Fig. 20

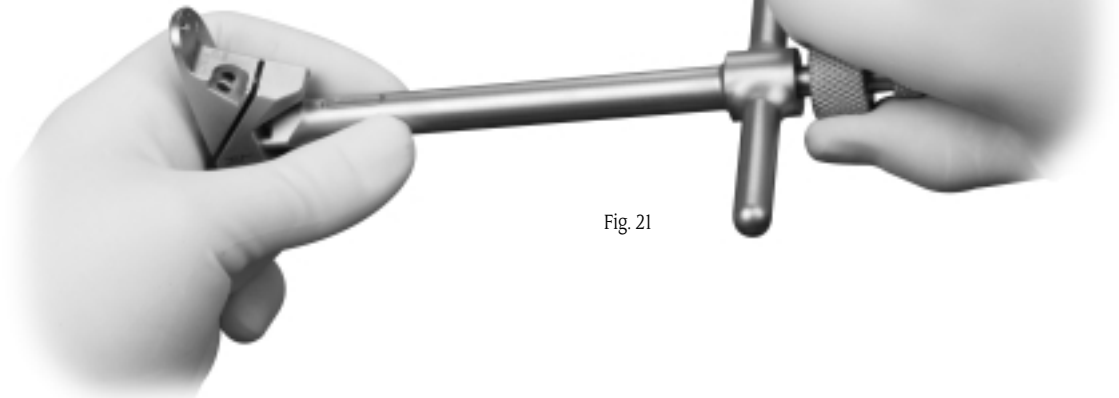


Fig. 21



Insert the foot of the guide into the joint and rest the flat surface against the cut distal condyle. Pull the foot of the guide anteriorly until it contacts the cartilage/bone of the posterior condyle. There should be 2mm-3mm of exposed bone above the anterior edge of the guide (Fig. 22). Repeat with additional guides until the proper size is selected (Fig. 23). If the condyle appears to be between two sizes, choose the smaller size. This helps prevent the patella from impinging on the prosthesis.

**Note:** Be sure that there is no soft tissue or remaining osteophytes between the Femoral Sizer/Finishing Guide and the cut distal condyle. It is important that the Femoral Sizer/Finishing Guide sits flush against the bone. Any gaps between the guide and the bone will compromise the accuracy of the cuts and, subsequently, component fit may be compromised. Do not allow the patella to cause improper alignment of the guide. The patella may move the finishing guide medially in a medial UKA.

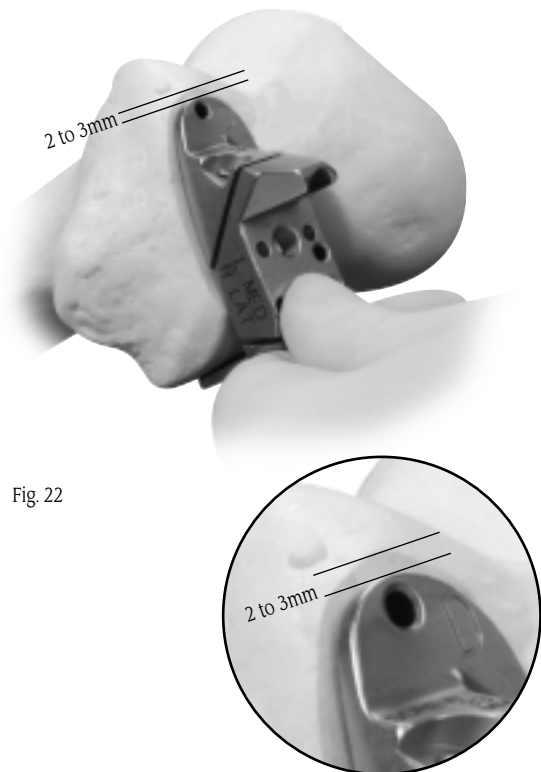
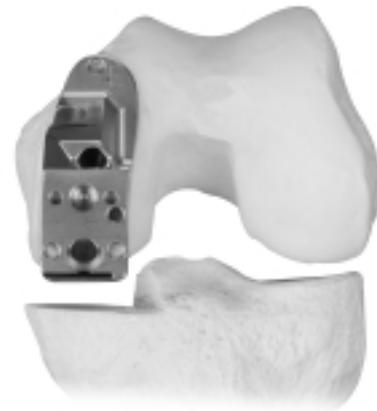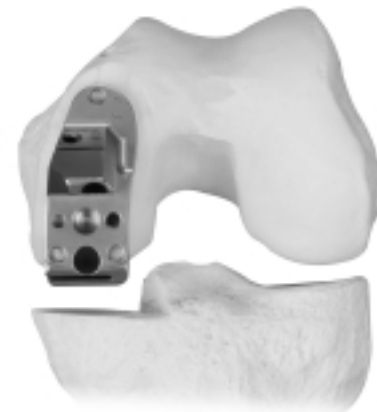


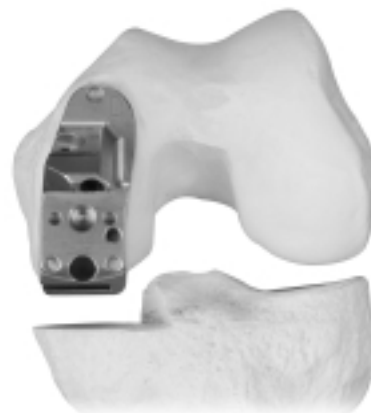Fig. 22



Too Large



Too Small



Just Right

Fig. 23



## STEP SEVEN: FINISH THE FEMUR

The following order is recommended to maximize the stability and fixation of the Femoral Sizer/Finishing Guide. This will help ensure that the cuts and holes are precise.

1. With the proper size Femoral Sizer/Finishing Guide in position, insert a 48mm Headed Screw into the top pin hole, or predrill and insert a Holding Pin (Fig. 24). Rotate the guide on the screw/pin until the posterior edge of the guide is parallel to the cut surface of the tibia (Fig. 25). Make sure there is exposed bone on both sides of the guide to ensure that the Femoral Sizer/Finishing Guide does not overhang.

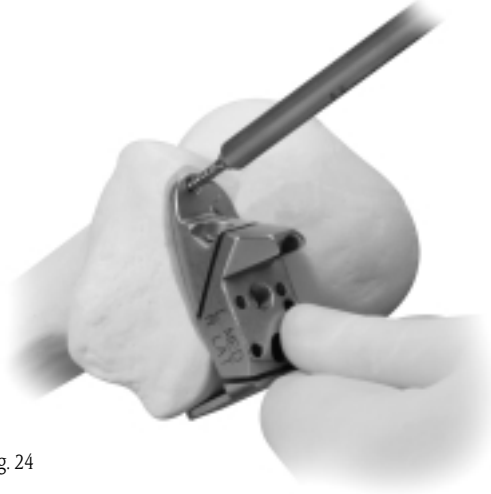


Fig. 24

2. Insert one 33mm Headed Screw (gold head) into the angled anterior pin hole, which is parallel to the chamfer cut (Fig. 26). For best fixation, seat the screw head slowly. This should stabilize the guide sufficiently to finish the femur. For additional stability, insert a 48mm Headed Screw or predrill and insert a Short Head Holding Pin into the middle hole closest to the intercondylar notch. If this hole is used, it will be necessary to remove the Femoral Sizer/Finish Guide before finishing the femoral cuts.

**Note:** For Femoral Sizer/Finishing Guide sizes A and B, the angle of the pin hole is different from the larger sizes. This is due to the relative difference in the size of the pegs on the size A and B femoral components, and does not affect the technique.

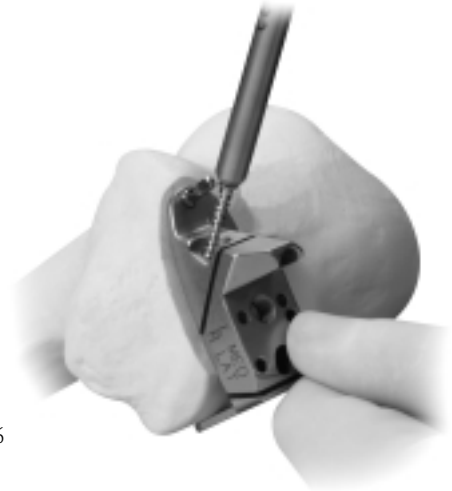


Fig. 26

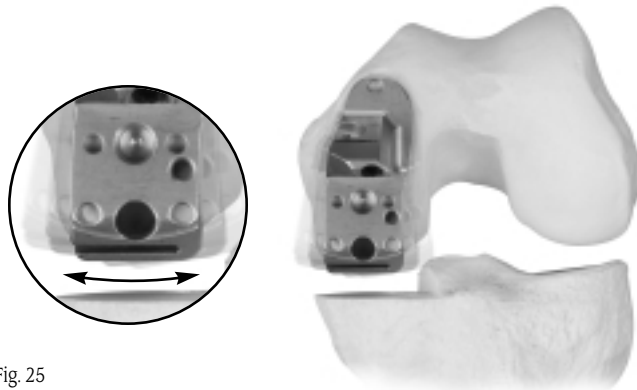


Fig. 25

3. Insert the Femoral Drill w/Stop into the anterior post hole, and orient it to the proper angle (Fig. 27). **Do not attempt to insert or align the drill bit while the drill is in motion.** When the proper alignment is achieved, drill the anterior post hole and, if necessary, insert a Femoral Holding Peg for additional stability.
4. Drill the posterior post hole in the same manner. This hole is angled the same as the anterior post hole (Fig. 28).



Fig. 27



Fig. 28

5. Remove the anterior Femoral Holding Peg and cut the posterior chamfer through the cutting slot in the guide. If a screw/pin was inserted into a middle hole, either remove the screw/pin or cut around it. The remaining island of bone can then be resected after removing the Femoral Sizer/Finishing Guide. If posterior screws/pins were used, cut until the saw blade almost contacts the screws/pins (Fig. 29).

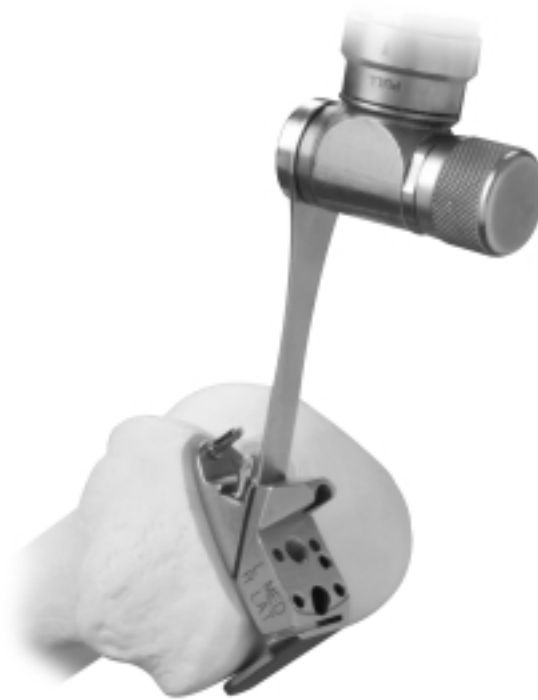

Fig. 29





6. Cut the posterior condyle through the cutting slot in the guide (Fig. 30).




Fig. 30

7. Remove the screws/pins and the Femoral Sizer/Finishing Guide, and finish any incomplete bone cuts.
8. Ensure that all surfaces are flat. Remove any prominences or uncut bone.

Debride the joint and inspect the posterior condyle. **If any prominent spurs or osteophytes are present, especially in the area of the superior posterior femoral condyle, remove them with an oscillating saw or an osteotome, as they could inhibit flexion or extension (Fig. 31).**

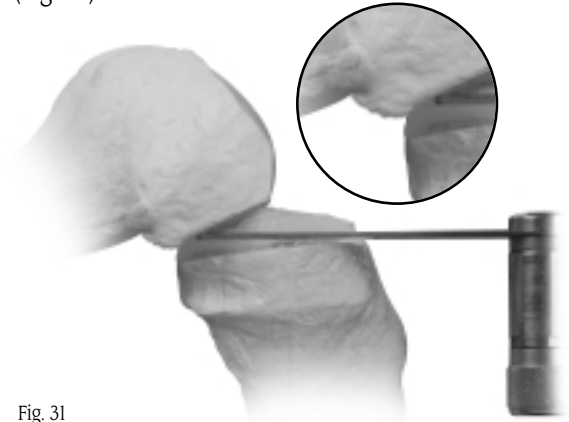


Fig. 31

#### ***Technique Tip***

*The Femoral Provisional may be put in place and the knee flexed. This would aid in identifying and removing any residual posterior condylar bone which could limit flexion.*



## STEP EIGHT: FINISH THE TIBIA

Resect the remaining meniscus and remove any osteophytes, especially those interfering with the collateral ligament.

Place the head of the Tibial Sizer on the cut surface of the tibia with the straight edge against the surface created by the sagittal cut. Verify the proper rotation of the sagittal cut in the transverse plane. The rotation is correct when the sizer handle is 90° to the coronal plane (Fig. 32). Select the Tibial Sizer that best covers the resected proximal tibia in both the A/P and M/L dimensions. If desired, use the resected tibial bone fragment as an aid in sizing. If necessary, a second sagittal cut can be made to allow for optimal coverage with the next larger size tibial base plate.

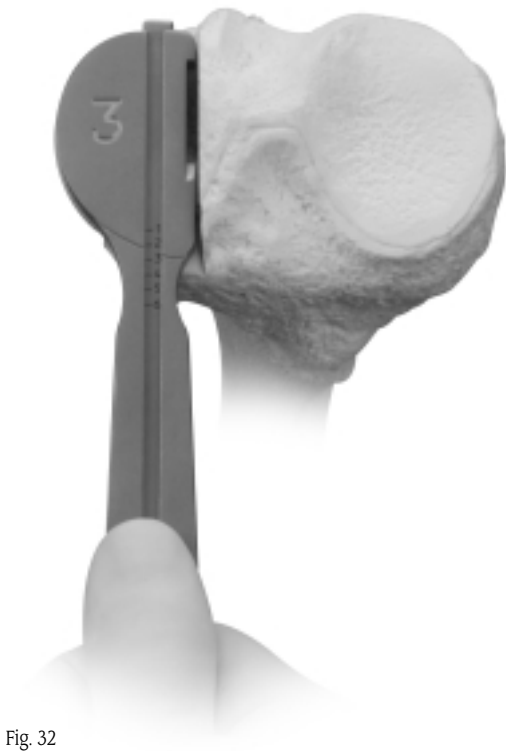

Fig. 32

The Tibial Sizer has a sliding ruler which facilitates measuring in the A/P dimension (Fig. 33). Be sure that the head of the sizer rests on cortical bone near the edge of the cortex around its entire perimeter. **Be sure that it does not overhang.** Pull the Tibial Sizing Slider anteriorly until the hook on the tip of the slider contacts the posterior edge of the tibia (Fig. 34).

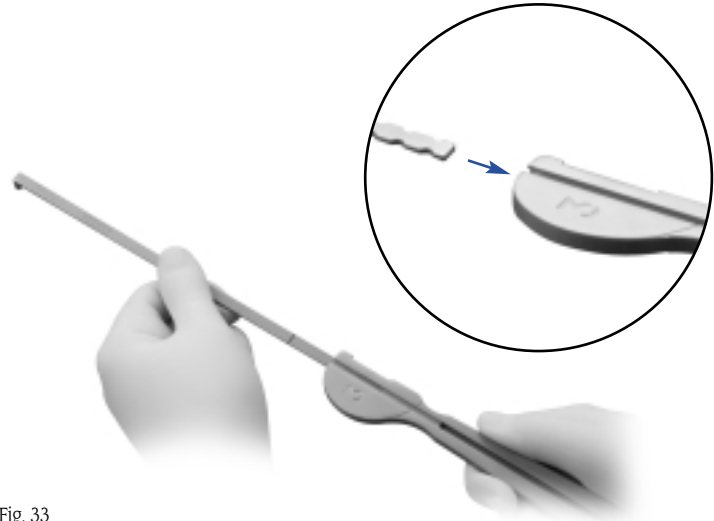


Fig. 33

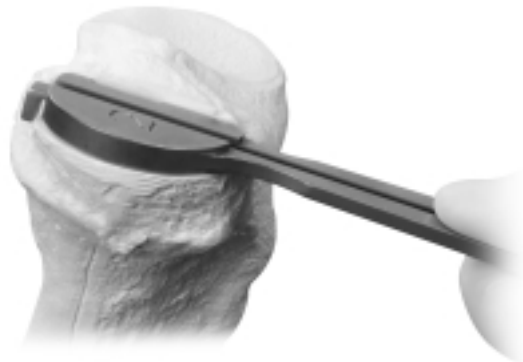


Fig. 34





**Technique Tip**

*Clean the edge of the bone cut with a curette so the sizer will fit flush against the cut.*

There are a number of indicators on the Tibial Sizer. If the slider is used without the sizer, the etch marks 1 through 6 on the slider indicate the A/P length of the corresponding implant. If the slider is used with the sizer, the A/P length is indicated on the sizer handle (Fig. 35). An additional measurement on the slider at the tip of the sizer handle indicates the length of exposed bone posteriorly (behind the implant) with the sizer head in this particular position (Fig. 35). Also, the cutout on the straight edge of the sizer head indicates the location of the tibial keel for marking.

Remove the Tibial Sizer. Then remove all soft tissue debris from the popliteal region.

**Technique Tip**

*To facilitate insertion of the Tibial Fixation Plate Provisional, externally rotate the tibia while the knee is flexed.*

Place the corresponding size Tibial Fixation Plate Provisional onto the cut surface of the tibia.

Insert the Tibial Plate Impactor into the recess on the provisional and impact it so the central fin engages the bone and the provisional sits flush on the tibial surface (Fig. 36).

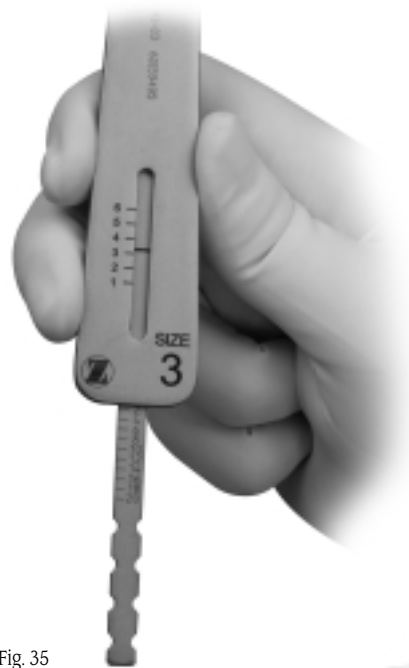

Fig. 35



Fig. 36



Pre-drill and insert a 17mm Short-head Holding Pin (00-5977-056-02) into the anterior fixation hole (Fig. 37).

Use the Tibial Drill w/Stop to drill the two tibial peg holes (Fig. 38). **Note that these holes are angled 20° posteriorly** to facilitate drilling. Although the pegs on the implant are at 90°, the drill is designed so that the pegs will fit into these angled holes.

Leave the Tibial Fixation Plate Provisional in place on the bone.

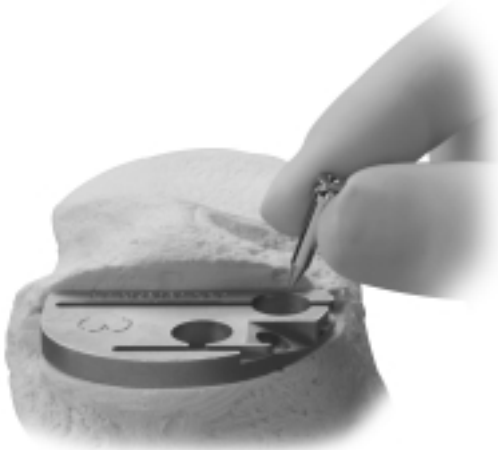

Fig. 37

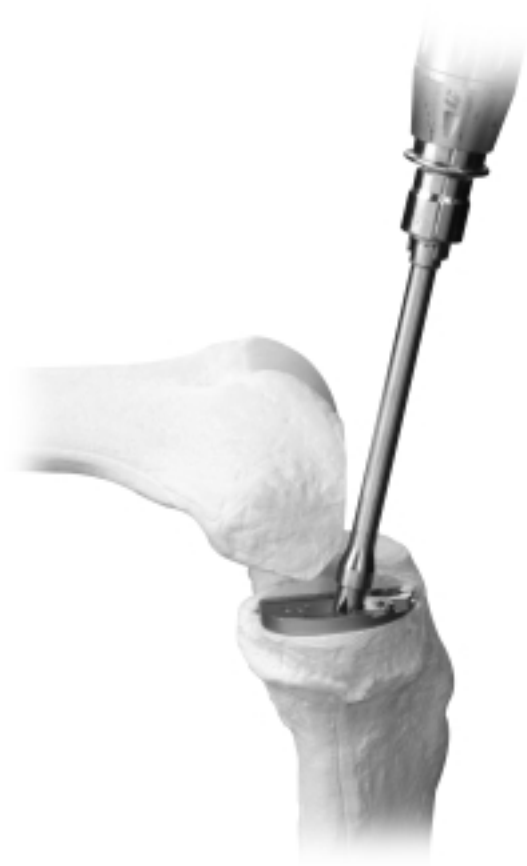

Fig. 38



## STEP NINE: PERFORM TRIAL REDUCTION

Remove the IM Patellar Retractor. With all bone surfaces prepared, perform a trial reduction with the appropriate size Femoral Provisional, Tibial Fixation Plate Provisional, and Tibial Articular Surface Provisional. The Concave Tibial Spacer can be used in place of the combined Tibial Fixation Plate Provisional and Tibial Articular Surface Provisional.

Insert the prongs on the Insertion Handle into the corresponding holes on the Femoral Provisional (Fig. 39). Thread the handle into the provisional and tighten it securely (Fig. 40).




Fig. 39

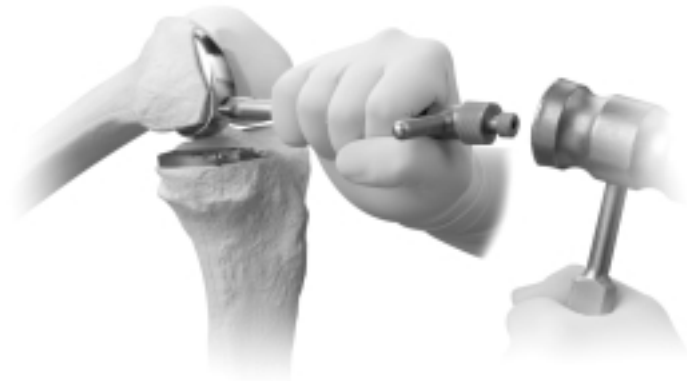

Fig. 40

To help guide the femoral provisional past the patella, place the leg in deep flexion to begin the insertion. Insert the long post first. Then adjust the leg to a midflexion position, rotating the provisional around and in back of the patella. Reposition the leg in deep flexion to complete the insertion. Impact the provisional onto the femur with a mallet.

Slide the rails on the bottom of the Tibial Articular Surface Provisional into the grooves on the Tibial Fixation Plate Provisional (Fig. 41). Check the fit of the provisional components. If necessary, perform minor trimming of bone surfaces.

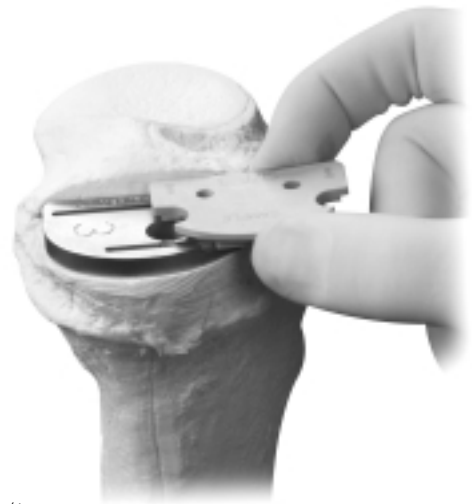

Fig. 41

With all trial components in place, check for proper range of motion and ligament stability. The Tibial Articular Surface Provisional or Concave Tibial Spacer used should permit full flexion and full extension. Overstuffing should be avoided, as this will transfer stress to the contralateral compartment.

Evaluate soft tissue tension in flexion and extension. Use the 2mm end of the Tension Gauge to help ensure that flexion and extension gaps are not too tight (Figs. 42).

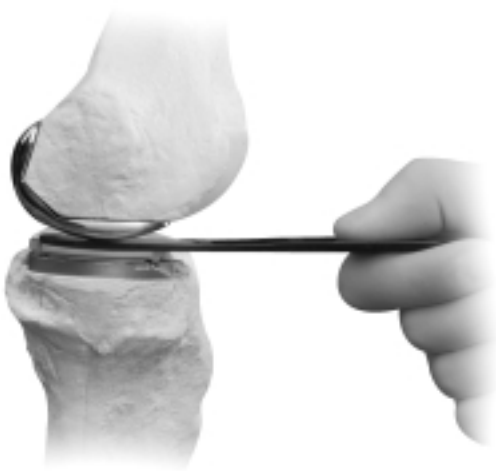

Fig. 42

The correct thickness of the prosthesis is one that produces the desired alignment and does not cause excessive stress on the collateral ligaments. As a rule, the correct prosthesis should allow the joint space to be opened approximately 2mm when a stress is applied, with the knee in full extension and without soft tissue release.

The knee must also be tested in 90° of flexion to allow a 2mm flexion gap. Excessive flexion tightness will prevent postoperative flexion and may cause the tibial prosthesis to lift up anteriorly as the femoral component rolls posteriorly on the tibial component. If the joint is too tight in flexion, try using a thinner tibial articular surface component or increasing the posterior slope of the tibial resection.

#### ***Technique Tip***

*Use the 2mm end of the Tension Gauge to help balance the knee in both flexion and extension. With the knee flexed 90°, position the 2mm end of the Tension Gauge between the Femoral Provisional and the Concave Tibial Spacer. This should be a snug, but not an overly tight fit. Then use the same test with the knee in full extension.*





## STEP TEN: IMPLANT FINAL COMPONENTS

Obtain the final components and implant the tibial component first.

### *Technique Tip*

*With the modest amount of bone removed, particularly from the tibia, there may be a sclerotic cut surface. If the resected surfaces of the tibia and/or femur are sclerotic, drill multiple holes with a small drill (2.0mm-3.2mm) to improve cement intrusion.*

### **Tibial Component**

To facilitate insertion, flex the knee and externally rotate the tibia. If desired, place an opened and slightly moist sterile gauze sponge behind the tibia before implanting the components to help collect excess cement behind the tibia.

Apply cement and press the tibial base plate or the all-polyethylene tibial component onto the tibia. Position and press down the posterior portion of the component first. Then press the anterior portion of the component, expressing excess cement anteriorly.

Use the Tibial Plate Impactor to impact the tibial base plate (Fig. 43).

**Note:** *Do not use the Tibial Plate Impactor to impact an all-polyethylene tibial component.*

Remove the sterile gauze sponge slowly from behind the joint, and use the Cement Removal Tool to remove any excess cement.



Fig. 43



## Femoral Component

Apply cement and begin the femoral component insertion with the leg in deep flexion. Insert the long post first. Adjust the leg to a midflexion position, rotating the implant around and in back of the patella. Then reposition the leg in deep flexion and seat the component with the Femoral Impactor (Fig. 44).



Fig. 44

If using a modular tibial component, confirm the correct size and thickness of the final tibial articular surface by testing with the Tibial Articular Surface Provisionals in maximum flexion and extension. Use the Tension Gauge to assess the flexion and extension gaps. Then recheck alignment to verify that the joint has not been overcorrected.

## Tibial Articular Surface

After the cement has cured, remove any remaining excess cement before the final placement of the tibial articular surface.

**Do not proceed with locking the final articular surface component until cement has fully cured.**

With the engraved side down, slide the edge of the polyethylene component under the posterior lip of the base plate. Then insert the tab on the lower jaw of the Tibial Articular Surface Inserter into the notch on the front of the tibial base plate. Bring the polyethylene tip on the upper jaw of the inserter down until it contacts the articular surface implant. Squeeze the handles of the inserter together until the articular surface implant snaps into place (Fig. 45).

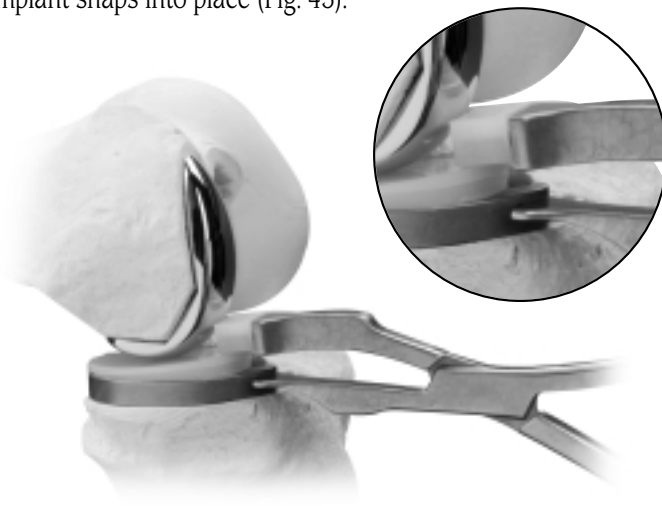


Fig. 45

## CLOSURE

Irrigate the knee for the final time and close. Cover the incision with a sterile dressing and wrap the leg with an elastic bandage from the toes to the groin.









1. Berger RA, Nedeff DD, Barden RM, et al. Unicompartamental knee arthroplasty: Clinical experience at 6 to 10 year follow-up. *Clin Orthop*. 1999;367:50-60.
2. Cartier P, Seinouiller JL, Grelsamer RP. Unicompartamental knee arthroplasty 10-year minimum follow-up period. *J Arthroplasty*. 1996;11(7):782-788.

Please refer to package insert for complete product information, including contraindications, warnings, precautions, and adverse effects.



Contact your Zimmer representative or visit us at [www.zimmer.com](http://www.zimmer.com)

