



Anatomical Shoulder™ System Surgical Technique



Removable head option for improved surgical results

Anatomical Shoulder Prosthesis
Developed in conjunction with

Christian Gerber, M.D.
Switzerland

Laurence Higgins, M.D.
Assistant Professor
Division of Orthopaedic Surgery
Duke University Medical Center
Durham, NC USA

Jon J.P. Warner, M.D.
Chief, Harvard Shoulder Service
Massachusetts General Hospital
Boston, MA USA

Table of Contents

Anatomical Shoulder™ System	3
Preoperative Planning	4

Surgical Technique

Positioning of the Patient and Approach	6
Implantation of the Cemented or Uncemented Shoulder Prosthesis	8
Glenoid, Preparation and Implantation	16
Postoperative Treatment	21
Special Version for Setting Fractures	23

Revision

Removal of the Implant Head	25
Removal of the Implant Stem	28

Instruments

Preparation and Description of the Assembly of the Instruments	29
Review of the Instrument Trays	31

Anatomical Shoulder
System “removable head”
The implant head can be separated
from the stem below the plane of
resection of the head.



Uncemented (press-fit) shoulder prosthesis

Cemented shoulder prosthesis

Removable prosthetic head



Anatomical Shoulder System

Cemented Shoulder Prosthesis Uncemented (Press-Fit) Shoulder Prosthesis

Indications

- primary and secondary osteoarthritis
- arthritis of the shoulder (rheumatoid arthritis, ankylosing spondylitis, etc.)
- avascular necrosis of the humeral head
- tumor resection is sufficient
- “cuff-tear arthropathy”
- complex fractures of the proximal humerus
- post-traumatic malposition of the proximal humerus

Contraindications

- acute infection
- neuroarthropathy shoulder (Charcot shoulder)

See also package insert

Preoperative Planning

Three radiographic images of the shoulder joint are required for planning the operation:

1. Full-size anterior-posterior view with neutral rotation (0°), centered on the articular cavity
2. Axial view
3. CT scans for planning the glenoid insertion

Preoperative planning – humerus

After aligning the humeral stem on the anterior-posterior X-ray at 0°, place the humeral-head template on the stem template and determine the size of the head of the prosthesis. It is determined on the basis of the distance from the junction between the greater tuberosity and the humeral head to the cartilage – bone boundary on the calcar of the humerus. The line connecting these two points corresponds to the resection plane.

If there is marked deformation of the head, planning should be based on the healthy contralateral joint on the other side.

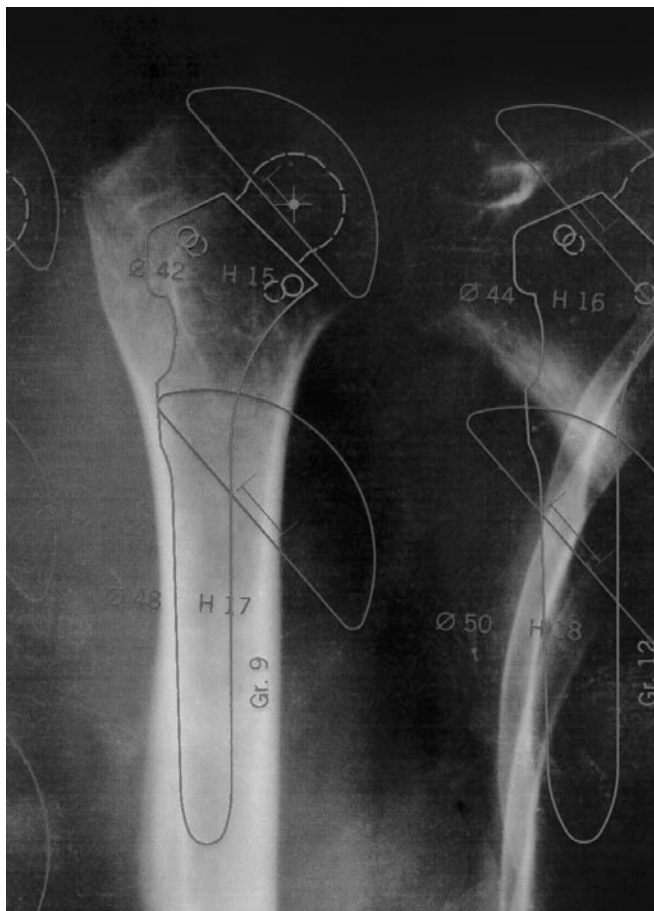
Determine the size of the stem of the prosthesis on the basis of the anterior-posterior and axial X-rays.

The stem should approximately fill the medullary canal, both proximally and distally. Eccentricity and retrotorsion are adjusted intra-operatively.

For proximal fractures of the humerus, carry out the planning on the contralateral shoulder and place a tracing referring to the normal proximal humerus under the fractured proximal humerus.

Draw in the optimum height of the stem of the prosthesis and the size and position of the head of the prosthesis.

During the operation, relate the position of the prosthesis to the fracture land-marks that are useful for reproducing the height that has been drawn in.



Template Options

X-ray template of cemented prosthetic stem
Reference Literature Number 06.00640.000

X-ray template of uncemented (press-fit) prosthetic stem
Reference Literature Number 06.00859.000

X-ray template of humeral heads
Reference Literature Number 06.00642.000

Comment
X-ray templates are magnified by 10%.

Preoperative planning – glenoid

The glenoid should be evaluated on CT scans.

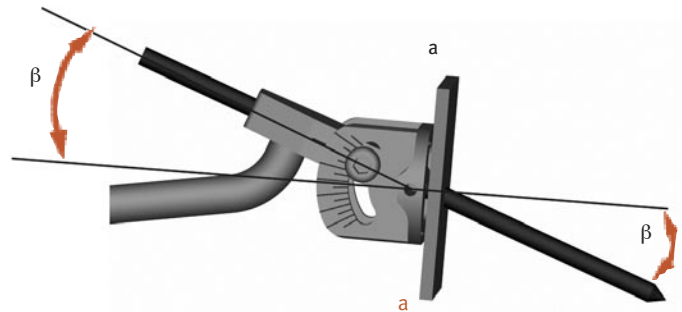
Preoperative CT investigation is recommended whenever a total shoulder prosthesis is used. If there is a defect in the posterior glenoid, this must be corrected either by corrective reaming or by bone reconstruction (using the resected head).

As illustrated below, measure the first horizontal CT section below the tip of the coracoid process and read off the glenoid version (α) (any osteophytes must be identified and not taken into consideration). Now determine the correction angle on the basis of the measured glenoid version, knowing that the coronal (physiological) retroversion amounts to between 0° and 10° (retro).

Enter the correction angle you have calculated on the glenoid positioning guide. Care must be taken both while drawing and during surgery, to ensure that the glenoid positioning guide lies on plane a-a.

Carry out cranio-caudal alignment of the Kirschner wire under visual monitoring.

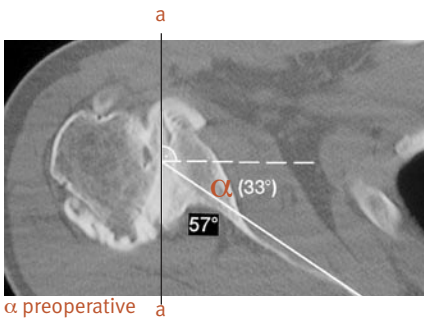
Then set this correction angle on the glenoid positioning guide, keeping in mind that one graduation mark corresponds to 5° (see page 17).




Glenoid guidance instrument (one mark = 5°)

$\beta = \alpha \text{ preoperative} - \alpha \text{ postoperative}$

A preoperative CT scan is recommended for the purpose of determining the possible need for realignment of the articulating surface. The target value is a coronal (physiological) retroversion of between 0 and 10° (retro).



α preoperative



α postoperative

Surgical Technique Positioning of the Patient and Approach

The patient should be placed in a “beach-chair” position on the edge of the operating table (Fig. 1). The arm must be freely movable and it must be possible to extend it fully. An armrest is optional.

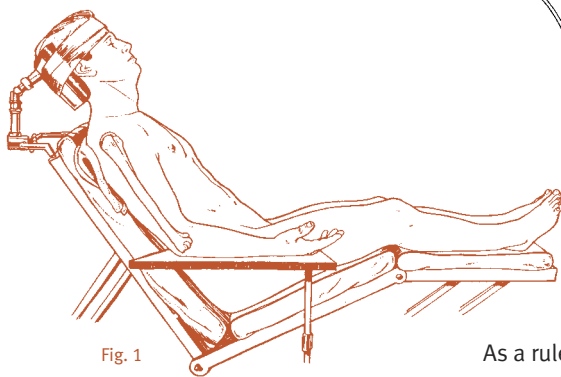


Fig. 1

Make a skin incision in a straight line starting from the lateral edge of the coracoid as far as the insertion of the deltoid muscle. Seek out the cephalic vein between the deltoid muscle and the pectoralis major muscle. Make the approach medial to the vein (Fig. 2).

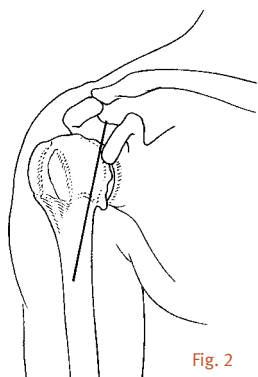


Fig. 2

After exposing the subacromial space, retract the deltoid muscle with a deltoid retractor.

Retract the common tendon of the short biceps and the coracobrachialis muscles with a Langenbeck retractor (Fig. 3).

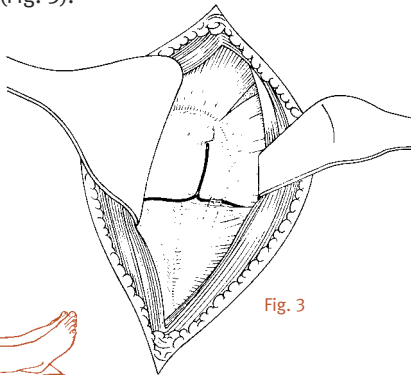


Fig. 3

As a rule it is not necessary to nick the pectoralis major muscle.

Rotate the arm outwards as far as possible and bring the subscapularis muscle into the field of vision (Fig. 4).

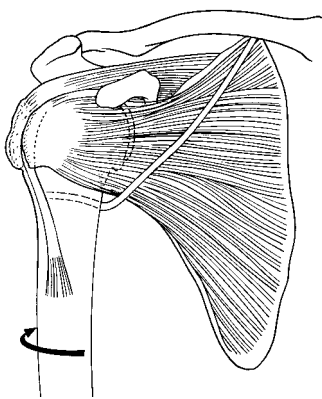


Fig. 4

Make a vertical incision 1 cm lateral to the muscle tendon junction of the subscapularis, so that approximately 1 cm of tendon remains attached to the muscle. Alternatively, it is possible to detach the tendon of the subscapularis muscle either subperiostally or with an osteotome from the lesser tuberosity, securing it back into place transosseously after the operation (see also page 7, Figure 7).

Mobilize the subscapularis muscle by means of a capsulotomy and loop 4 to 5 strong non-absorbable sutures around it (Fig. 5). An incision into the coracoacromial ligament should be made only in exceptional cases.

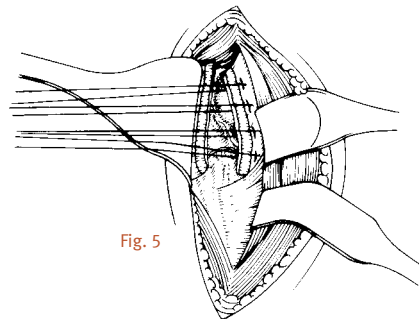


Fig. 5

Adduct the arm and put the humerus retractor (ring retractor) into place, so that the glenoid can be exposed. It is now possible, by pulling on the subscapularis muscle, to expose the axillary nerve with the arm both adducted and flexed, and also to protect it (Fig. 6).

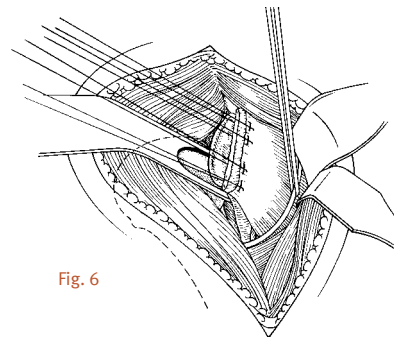


Fig. 6

If there is pronounced internal rotation contracture, it may be necessary to undertake partial release of the subscapularis muscle from the fossa (Fig. 7).

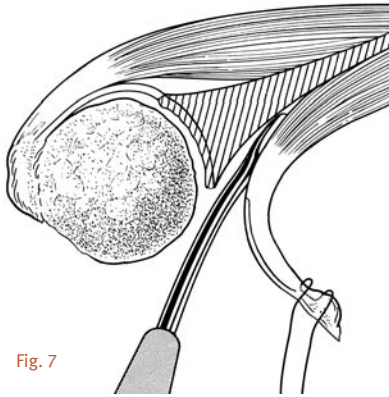


Fig. 7

After exposing the axillary nerve, remove the ring retractor and dislocate the humerus by rotating it externally. The proximal end of the humerus is now free. Keep the arm adducted, rotated externally and extended. Then place a blunt Hohmann retractor on the calcar and carefully remove all the osteophytes from the anatomical neck using a rongeur. Now expose the attachment of the cartilage to the humeral head by inserting an 8 mm hook behind the biceps tendon (Fig. 8).

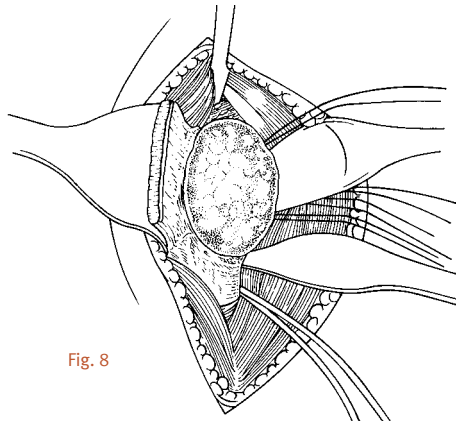


Fig. 8

**Implantation of
the Cemented or
Uncemented (Press-Fit)
Anatomical Shoulder™
Shoulder Prosthesis**



Cemented shoulder prosthesis with glenoid



Uncemented (press-fit) shoulder prosthesis with glenoid

The humeral head should be resected exactly at the level of the anatomical neck.

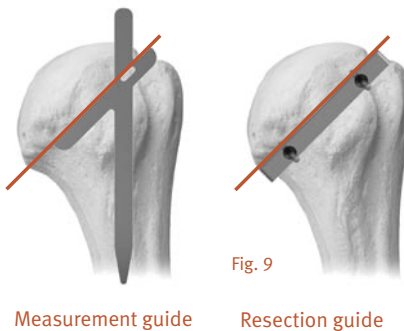
In the superior and anterior superior aspects, the anatomical neck corresponds to the insertions of the tendons of the cuff (supraspinatus and uppermost section of the subscapularis). In the inferior aspect, there is a smooth transition between the cartilage of the head and the cortical bone of the humerus.

In the posterior aspect, in the region of the infraspinatus and teres minor, is the sulcus, which is a groove of 6 to 8 mm in length, without cartilage or attached tendons.

The incision must start exactly on the cartilage. Do not resect the cartilage-free area.

The humeral head is now resected exactly at the height of the anatomical neck with the aid of the oscillating saw – i.e. in the cartilage-covered section of the head.

The resection is in the caudal direction. The measurement and/or resection guides can be used for orientation or assistance (Fig. 9).



Measurement guide

Resection guide

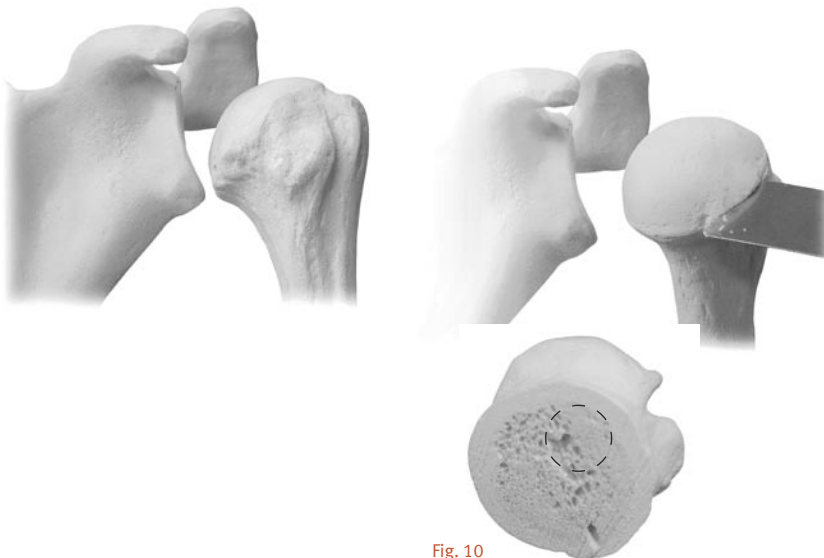

Fig. 10

After the osteotomy of the humeral head, the point of insertion of the reamer can be marked with a 3 mm awl under the highest point of the resection, directly medial to the bicipital tendon (Fig. 10).

For this purpose, the arm is externally rotated and extended and the elbow is rested on the body.

If a glenoid is used

The plane of the humeral resection can be protected with a disk-shaped protector (Fig. 11). Disks of three different diameters (40, 44 and 48) are available. The pins on the lower side of the disks are inserted at the level of the incision (glenoid, preparation and implantation; see page 17).

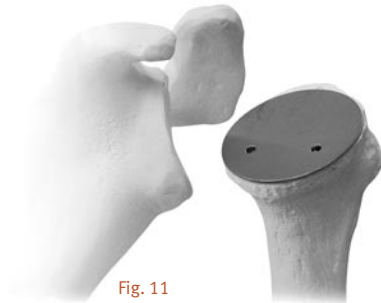


Fig. 11

After the point of insertion has been determined, the medullary cavity is opened, starting with a size 7 reamer (Fig. 12).

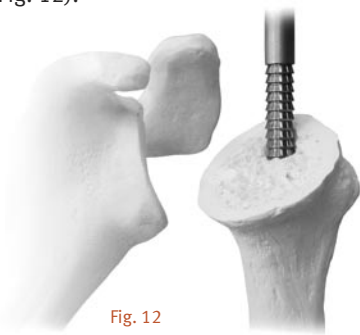

Fig. 12

The medullary cavity is gradually widened, using reamers of increasing sizes as required – sizes 9, 10.5, 12 and 14. The depth of penetration is defined by the uppermost tooth.

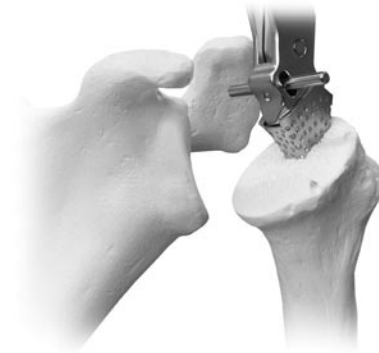Care should be taken to ensure that the uppermost tooth of the reamers is fully inserted into the medullary cavity.

If a revision stem is used, the additional marking is used as reference.

After opening the medullary canal, the proximal section of the humerus is prepared with the aid of modular rasps, starting with rasp size 7.



The fin is directed towards a point approximately 9 mm behind the sulcus. The proximal section of the humerus is then prepared stepwise with rasps of size 9, 10.5, 12 and 14, up to the size of the previously used reamer.



Care should be taken to ensure that the rasps are fully inserted into the humerus, i.e. until the movable crosspin is visible on top and contacts both anterior and posterior metaphyseal surfaces (Fig. 13). If full insertion of the rasp to this extent is not successful, the uncemented (press-fit) shaft of this size may not be used.

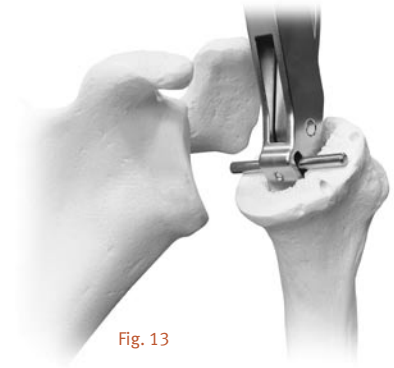

Fig. 13

The rasp handle is now removed and the modular rasp left in the humerus (Fig. 14).

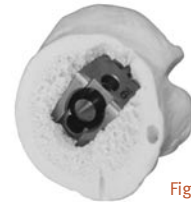


Fig. 14

The rasped lateral fin is now visible posterior to the bicipital tendon.

Additional optional fixation of the modular rasp in the humerus can be performed by inserting a rasp fixation screw into the modular rasp (Fig. 15). (This is recommended if the bone quality is inadequate.) This ensures that the rasp will not subside when the humeral head is impacted onto it.

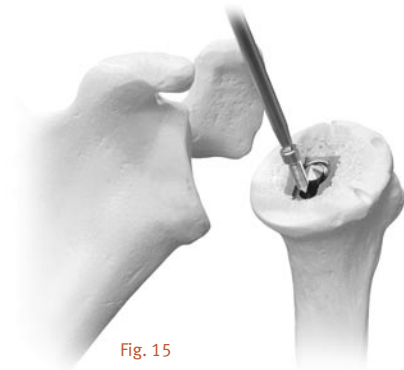


Fig. 15

The preparation of the humerus is now complete.

The size of the head of the prosthesis to be used is determined by means of a comparison with the resected humeral head and, in particular, with the resection area of the humerus. If osteophytes are present, they must be removed before this comparison. The diameter is the most important criterion for head size (Fig. 16).



Fig. 16

The diameter is fixed as the first parameter (Fig. 17).



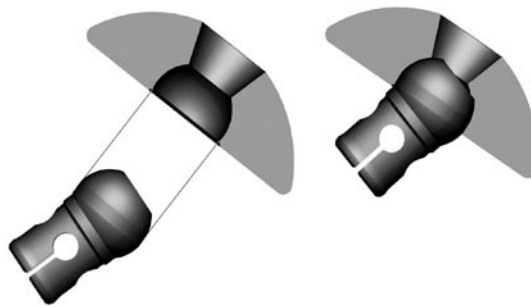
Fig. 17

The head height must also be selected for diameters of 48, 50, 52 mm.

The selected humeral head test prosthesis is inserted onto the test ball taper (Fig. 18).



Fig. 18



All grub screws must be tightened in place again outside the internal ball of the head.

The loosely connected humeral test prosthesis is placed on the modular rasp in the humerus, so that the underside of the head is resting on the humerus (Fig. 19).

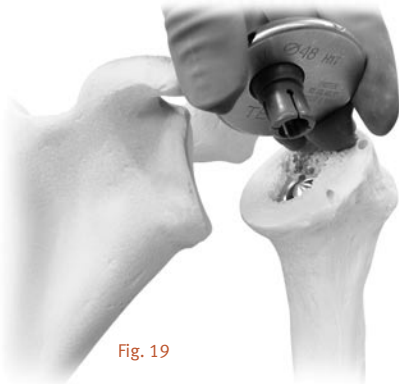


Fig. 19

The test head is then turned with the aid of an Allen wrench, until it exactly covers the area of the humeral resection incision, resulting in an exact anatomical restoration of the resected head (Fig. 20, 21).

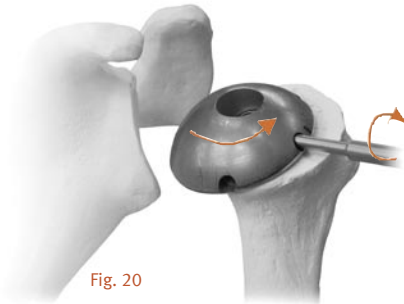


Fig. 20

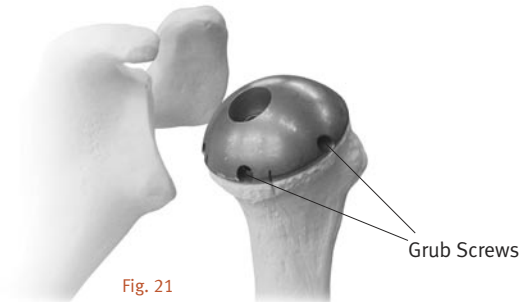



Fig. 21

With the aid of the grub screws, the humeral head test prosthesis can be fixed on the test ball taper, using the Allen wrench.

The offset laser marking of the humeral head test prosthesis is then transferred to the humerus by an incision and the humeral test prosthesis is then removed from the humerus.

The definitive prosthesis shaft (of the size determined by the last used modular rasp) the ball taper component, the standard cone and the set screw are unpacked.



cemented

uncemented

The standard cone is then placed into the ball taper component (Fig. 22).

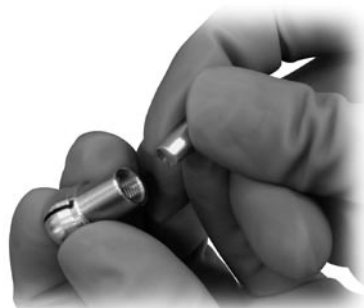

Fig. 22

The standard cone is fixed into the ball taper component using the insertion rod, without causing any spreading (Fig. 23).

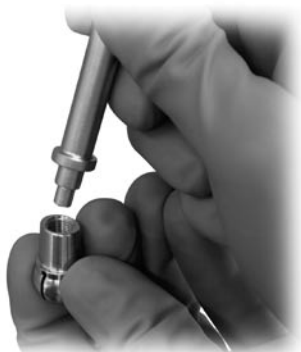

Fig. 23

The definitive prosthetic head is now unpacked. The size of the head has been defined by the previously used test prosthetic head.

The head is now inserted into the ball taper component as shown (Fig. 24).

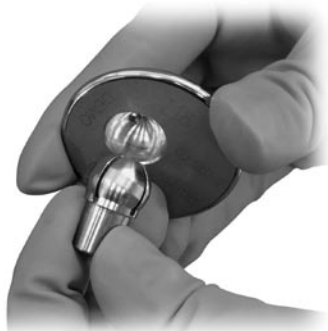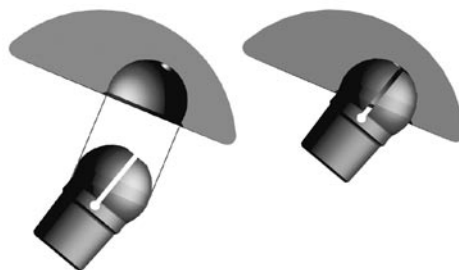


Fig. 24

The implant is now loosely assembled and the standard cone is located inside the ball taper component (Fig. 25).



Fig. 25



The assembled head is now fitted onto the oval internal profile of the modular rasp (Fig. 26).

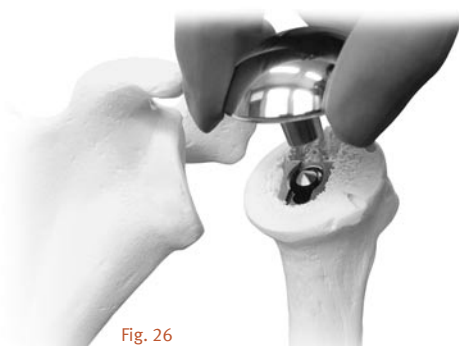


Fig. 26

The head is adjusted so that it covers the resection plane of the humerus.

A gap between the resection plane and the under side of the head is required, as the head must first be fixed onto the ball taper component.

The gap between the under side of the head and the resection plane is required before fixation. When the head has been set to be parallel and the offset laser marking of the head is aligned with the incision on the humerus, the head is prefixed to the ball taper component. Use three consecutive defined impulses from the Impactor for impaction (Fig. 27).



Fig. 27

Care should be taken to ensure that the Impactor is pressed centrally onto the ball area of the head and up to the maximum compression of the spring, before the three defined pulses are triggered.

These pulses propel the standard cone inside the ball taper component towards the ball. The standard cone is spread and the head is prefixed on the ball taper component.

The prefixed head component is now removed from the modular rasp. The inclination, retroversion and offset have now all been prefixed.

The screw is unpacked and inserted from the lower side of the head into the ball taper component using the socket wrench. The screw is then screwed loosely into the ball taper component until it sticks (Fig. 28).

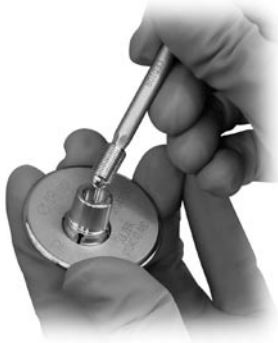

Fig. 28

The head implant is then inserted into the assembled mounting block and lightly fixed with the threaded rod (Fig. 29).



Fig. 29

The screw is then fastened with the torque wrench, using the nut, until it is tight.

The head prosthesis has now been permanently fixed and can be carefully removed from the mounting block.

The stem prosthesis is now placed into the stem holder (Fig. 30). Before the prosthesis head can be placed on the prosthesis shaft, the cones must be carefully cleaned of blood and possible other residues.



Fig. 30

The cone plug connection must be clean when they are connected (Fig. 31).



Fig. 31

The offset incision on the humerus is now examined, to see whether this is medial or lateral and anterior or inferior on the humerus. The head prosthesis is now placed on the stem prosthesis, after appropriate rotation.

The prosthesis head is now finally impacted onto the prosthesis stem with the aid of the Impactor (Fig. 32).



Fig. 32

Care should be taken to ensure that the Impactor is centrally located on the ball surface before the defined pulse is triggered.

The humeral implant has now been prepared specifically for this patient.

The modular rasp can now be removed again from the humerus (Fig. 33). If the rasp screw has been used it must be removed first. The rasp handle cannot be mounted without removing this screw.

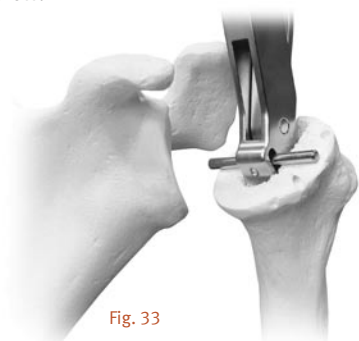

Fig. 33

If the rasp handle can not be attached, the modular rasp can also be removed from the humerus by means of the rasp extraction instrument (Fig. 34).

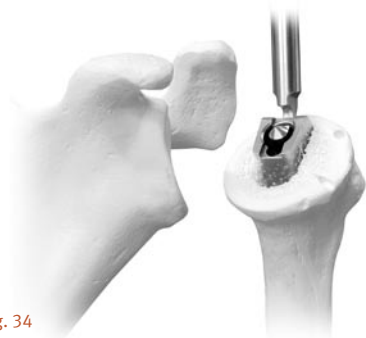

Fig. 34

Implantation of the prosthesis into the humeral shaft

With the cemented prosthesis, a cement restrictor can be inserted into the humerus, followed by the cement, in a relatively fluid consistency (Fig. 35).



Fig. 35

The implant is now inserted into the humerus, by applying controlled force with the thumb on the head. The lateral stem fin is used as orientation here. This is done until the lower side of the humeral head is resting on the humerus (Fig. 36).



Fig. 36

The implant is brought into the final position with careful blows from the humeral stem impactor. If the cemented prosthesis is being used, excess cement is then carefully removed.

The end the subscapularis is repaired using heavy, non-absorbable sutures either end to end or with transosseous sutures. The repair is started with a suture which adapts the lateral most aspect of the rotator interval.

Stitch the subscapularis and the supraspinatus tendons to each other with absorbable thread (Fig. 37).

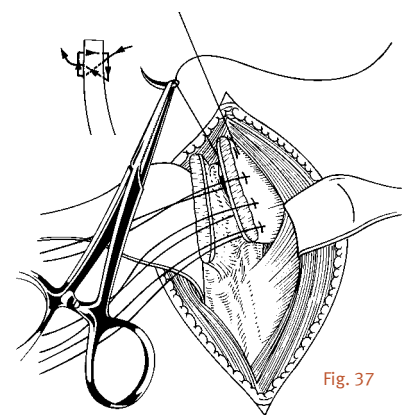
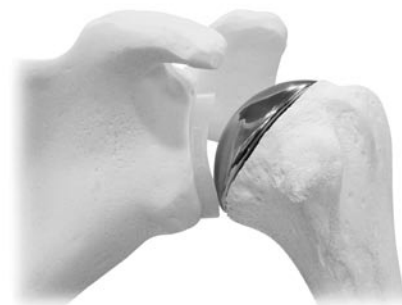
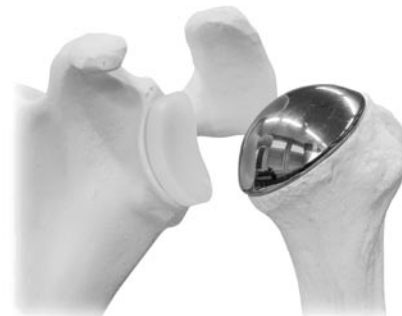
Fig. 37

At this point, also reconstruct the rotator cuff if required.

Glenoid, Preparation and Implantation



Glenoid component, 4-peg anchoring



Glenoid component, keel anchoring

Preparation

After removal of all the glenoid osteophytes, a ring retractor is inserted and the proximal humerus levered out posteriorly (Fig. 38). The inferior capsule must be incised carefully preserving the axillary nerve. Attention should be paid that the axillary nerve is protected. The caudal capsule is incised and the glenoid exposed.

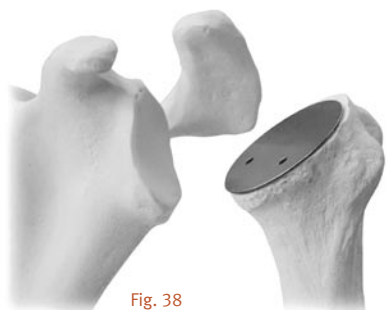


Fig. 38

Set the correction of version determined from the preoperative CT scan on the positioning guide, identify the optimal position for the guide pin and introduce the guide pin not further than 3mm into the glenoid bone (Fig. 39).

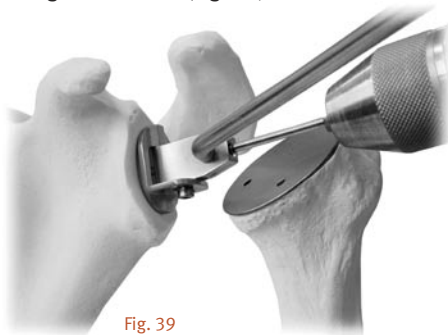

Fig. 39

The scaling from one engraved mark to the next corresponds to 5° on the positioning guide (see page 5).

The laser marking on the 3mm Kirschner wire must disappear slightly into the eyelet of the positioning guide.

After this, remove the positioning guide over the 3mm Kirschner wire.

The 3mm Kirschner wire is now perpendicular to the required alignment of the articulating surface, which was determined preoperatively (Fig. 40).

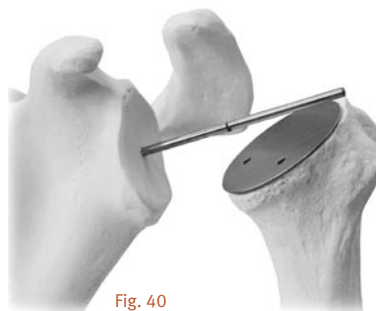

Fig. 40

The reamer and then the handle are mounted on the guide wire. For sclerotic glenoids the separate reamer may be used to start the reaming process.

If it is not impossible to insert the Kirschner wire, then you will have to drill a hole in the center of the glenoid with the glenoid drill and then machine the glenoid using the handle with the center locator (Fig. 41).

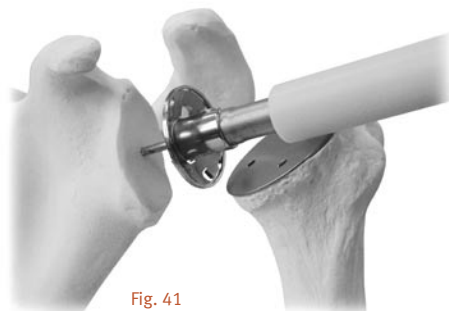



Fig. 41



Now ream the glenoid on the basis of the reamer size and ream in the new alignment of the articulating surface (Fig. 42).

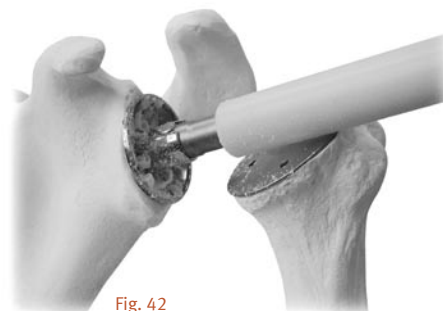


Fig. 42

The size of the last-used reamer corresponds to the size of the glenoid.

Note: If selection of the prosthetic components is difficult, it is generally preferable to err towards smaller heads and towards larger glenoids, but all sizes of glenoids can be combined with all sizes of humeral heads.

Glenoid components with 4-peg anchoring

Now guide the glenoid drill guide with the central hole along the 3mm Kirschner wire and place it on the surface of the glenoid.

The glenoid drill guide can also be secured in place by means of a drilled centering peg (Fig. 43).

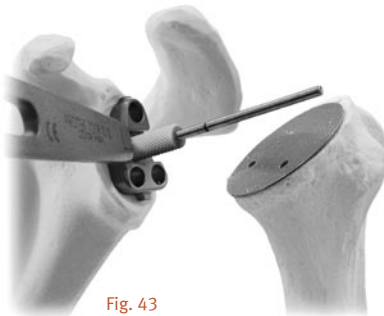


Fig. 43

The proximal hole with a diameter of 6.2mm is now bored with the glenoid drill.

Care should be taken to ensure that drilling is continued as far as possible with the glenoid drill guide (Fig. 44).

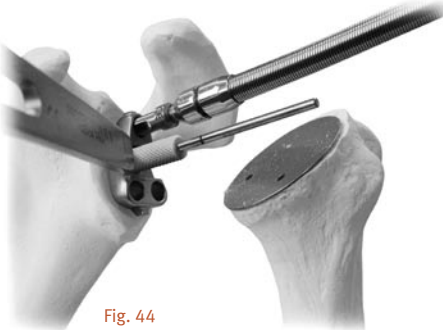


Fig. 44

The proximal bored hole is then fixed with a centering pin and one of the two distal holes is bored. This is then also fixed with a centering pin and the second distal hole is bored (Fig. 45).

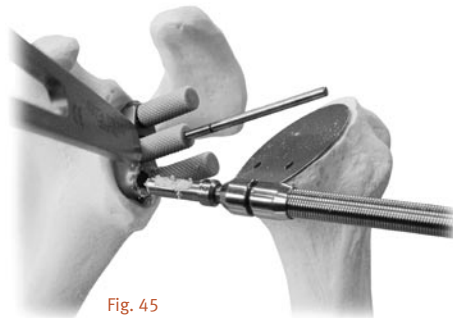


Fig. 45

The third bored hole is now fixed and the 3mm Kirschner wire and the centering pin are removed (Fig. 46).

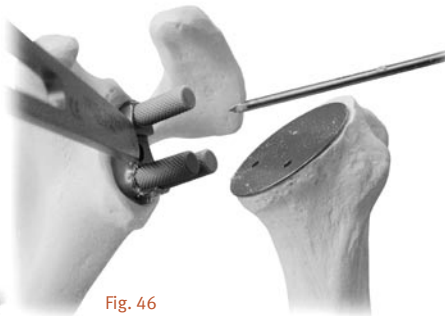


Fig. 46

Now drill the central hole.

Again, take care to drill as far as the limit stop on the glenoid drill guide (Fig. 47).

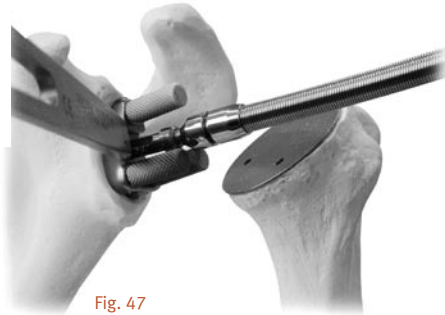

Fig. 47

Engage all the holes with the countersink in order to enable perfect seating of the glenoid component (Fig. 48).

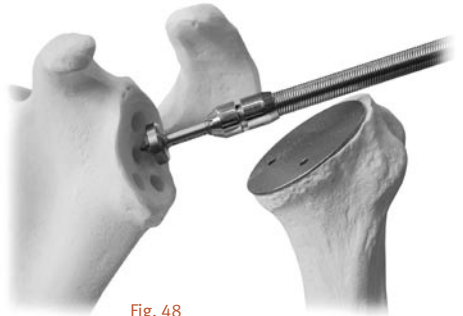

Fig. 48

Now insert the glenoid trial prosthesis into the glenoid prepared as above, using the holding forceps (Fig. 49).

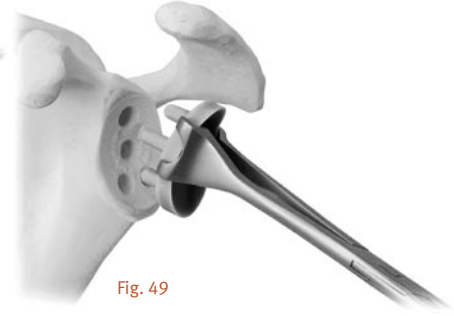


Fig. 49

Glenoid component with keel

After removing all the glenoid osteophytes that are exposed (this must also be investigated by means of a CT scan), apply a ring retractor to the rear edge of the glenoid.

Take care not to damage the axillary nerve.

Make an incision in the caudal capsule and expose the glenoid.

Please note

The glenoid drill guide is available in two sizes: sizes S and M for the keel glenoid of sizes S and M, and size L for the keel glenoid of size L.

Set the correction determined on the basis of the CT scan on the glenoid positioning guide and thread the 3mm Kirschner wire through the eyelet drilled in the positioning guide into the center of the glenoid and leave it in place.

The scaling from one engraved mark to the next corresponds to 5° on the positioning guide (see page 5).

The proximal bored hole is then fixed with a centering pin and the distal hole is bored (Fig. 50). This is then also fixed with a centering pin. The 3mm Kirschner wire and the centering pin are removed.

Now drill the central hole. The reamer and then the cannulated handle for reamer can now be guided along the 3mm Kirschner wire.

If the glenoid is sclerotic, it is advisable to ream it first with the separate reamer.

To help ensure optimal preparation of the bone to the keel glenoid, as a final step the bone is processed into a keel with a rasp (Fig. 51). This step gives optimal concentration of the bone.

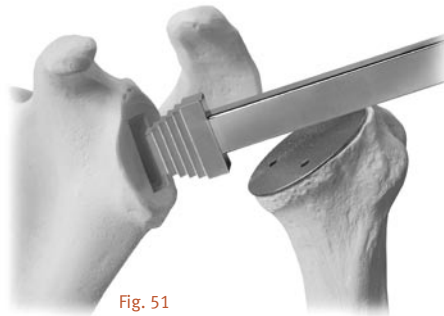


Fig. 51

If the drill guide of sizes S or M are used, the rasp of sizes S and M are used. The rasp of size L is used for size L.

The glenoid test prosthesis is inserted into the prepared glenoid using the holding forceps (Fig. 52).

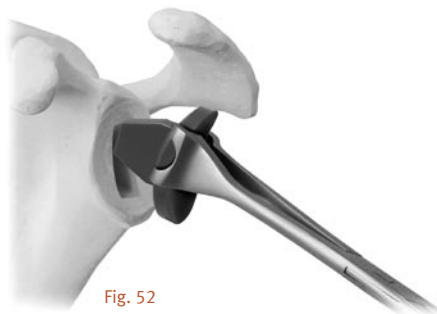


Fig. 52

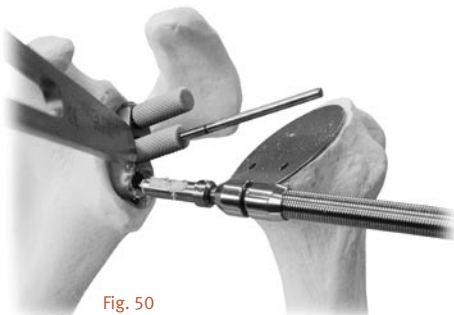
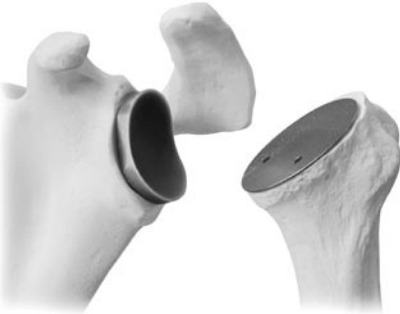

Fig. 50

Cementing

The glenoid test prosthesis is used to test whether the connection is stable.



The glenoid surface and the anchoring holes are now carefully cleaned and dried. The anchoring holes are filled with bone cement and the cement is pressed into the anchoring holes with a clean compress or using the instruments shown in the illustrations. The anchoring holes are then filled where necessary and cement is applied to the glenoid surface and the reverse side of the implant.

The implant is then cemented in place using the glenoid impactor (Fig. 53).

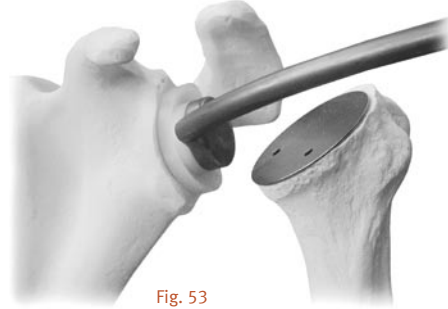



Fig. 53

Do not use the Impactor on the implant while the cement is hardening.

The excess cement is immediately and carefully removed with a knife blade.



Postoperative Treatment

From the first day after the operation the patient should take the arm out of the immobilizing dressing several times a day to stretch his elbow.

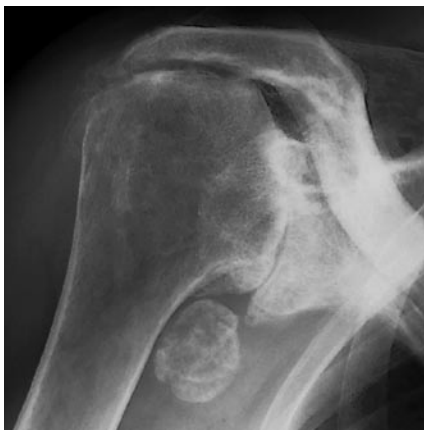On the day of the operation pendulum exercises are started, on the first day with passive flexing exercises, best performed using a cord passed over a roller.

Depending on the intra-operative findings, active exercises can be started from the third week.

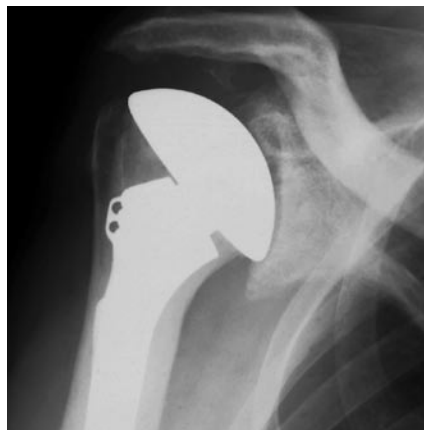If the rotator cuff was sutured or reconstructed, an abduction splint may be necessary for 4 to 6 weeks.

Case report 1

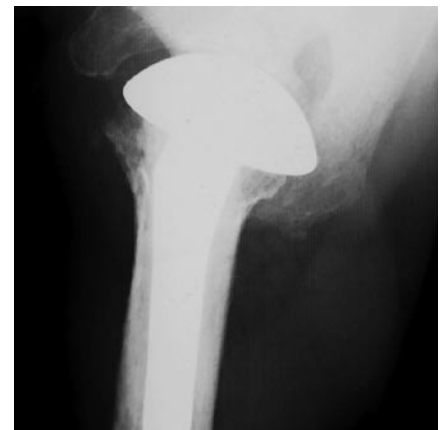Male patient, 78-year old, arthrosis with rotator cuff rupture



anterior/posterior



postoperative a/p

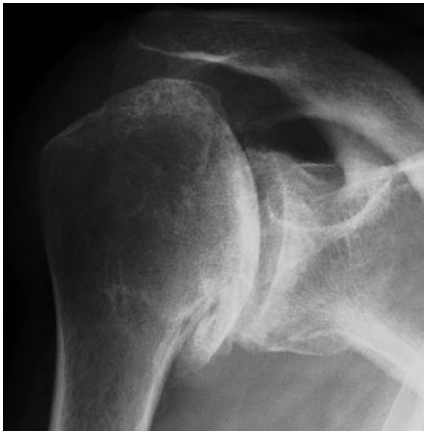

postoperative axial

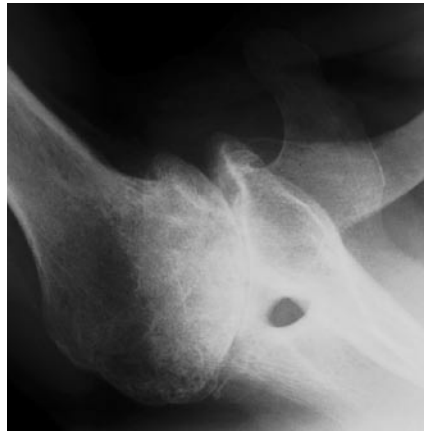
Case report 2

Male patient, 68-year old, severe osteoarthritis with posterior subluxation.

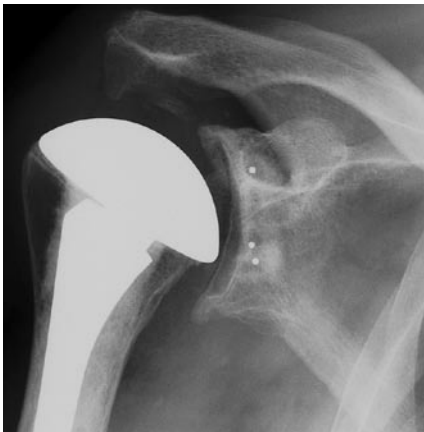
Correction of the glenoid version with a glenoid guidance instrument has led to anatomical reconstruction of the humerus and recentering of the joint.



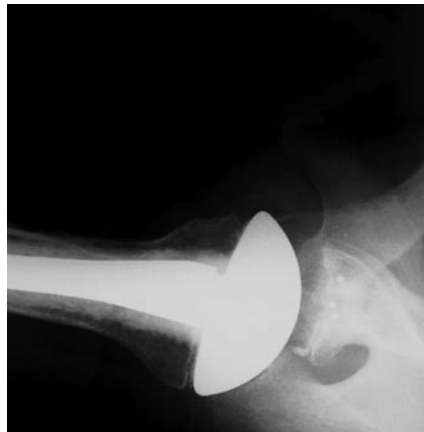anterior/posterior



axial



postoperative a/p



postoperative axial

Special Version for Setting Fractures

Following fractures of the proximal humerus, the humerus prosthesis is set at an average retrotorsion of 18° and a mean inclination (cervico-diaphyseal angle) of 130°. Fixation of the head of the prosthesis in this position is achieved by means of the fracture cone with a pin that is anchored in the drilled hole provided for this purpose.

Carry out preoperative planning according to the instructions provided on page 4, on the contralateral side

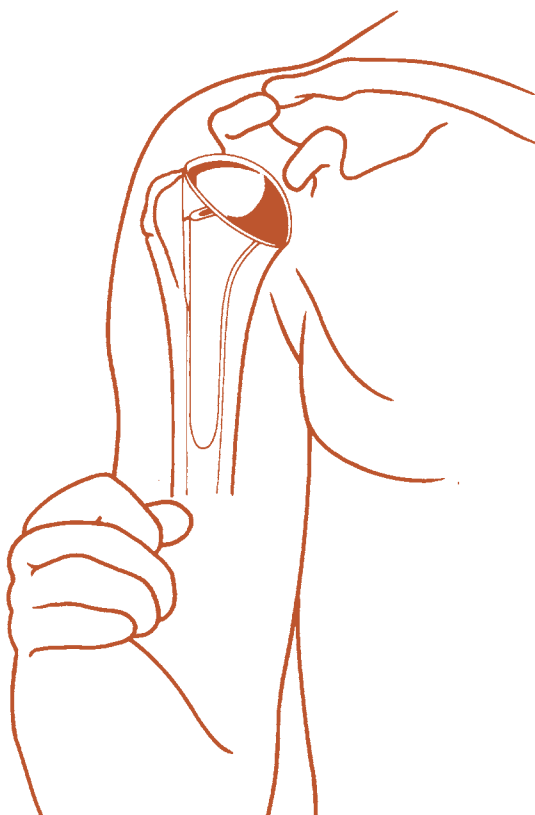Carry out the rasping and implant the humerus prosthesis with the elbow bent at an angle of 90° parallel to the axis of the epicondyle of the distal humerus. This automatically gives rise to an inclination of 130° and a retrotorsion of 18°.

After this, the tuberosities are fixed using strong thread passed through the hole in the proximal stem and the medial hole.

Unpack the permanent stem of the prosthesis and head (the size of the stem and that of the head were defined earlier on the basis respectively of the trial stem of the prosthesis and head used previously).

Then unpack the ball taper component, the fracture cone and the expanding screw.

Place the stem of the prosthesis on one side.



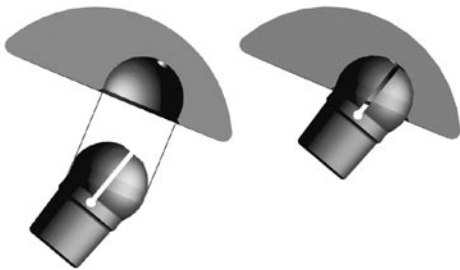
Now introduce the cone holder for fractures into the assembly block.

A left and a right cone holder are available.



Now fit the head onto the ball component as illustrated.

Introduce the fracture cone with its anchoring peg into the ball taper component from the underside of the head and secure it in place gently, using the nut in such a way that no expansion will take place as yet.



Introduce the head implant into the mounted assembly block in the cone holder.

After this, turn the prosthesis until the mark on the cone holder coincides with the one on the head, before fixing the head of the prosthesis in the assembly block with the threaded rod.



Before fixing the head on the ball taper component, it is necessary to make sure that the laser marking on the head coincides with the one on the cone holder and that the head of the prosthesis is positioned perfectly on the cone holder.



Once this has been done, tighten the expanding screw using the nut with the torque wrench, until this disengages.

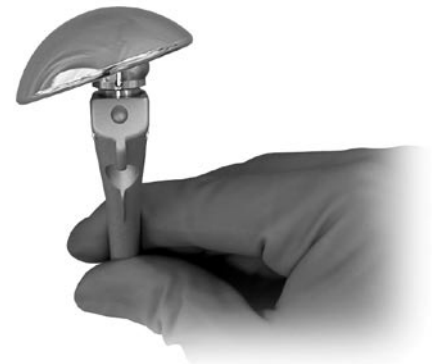

The head of the prosthesis is now irreversibly in place and can be removed from the assembly block, proceeding with care.

A mean inclination of 130°, an average retroversion of 18° and the appropriate offset have now been successfully transferred to the head implant.

Now put the head implant into place on the stem implant. It can now be implanted.

It must be stated that the prosthetic shaft must now be introduced exactly in neutral rotation that is in 0 degrees of version because the average version is given by the tilt of the head on the shaft.



**Revision – Removal of
the Implant Head and
the Implant Shaft**



Revision of humeral head and shoulder prostheses

Removal of the Implant Head

After exposing the axillary nerve, remove the ring retractor and sublux the humerus by externally rotating it. The proximal end of the humerus is now free. Keep the arm adducted, rotated outwards and extended. Then place a blunt Hohmann retractor on the calcar and carefully remove all the osteophytes from the anatomical neck using a rongeur. Now expose the attachment of the cartilage to the humeral head by inserting an 8mm hook behind the biceps tendon.

With a cemented humeral stem the humeral head is free of cement with a Lexer chisel so that the extraction instrument can be applied.

The extraction instrument is now applied to the humeral head and fixed with a two-edged screw (Fig. 54). With the aid of the impactor instrument and the slide hammer weight the humeral head is separated from the humeral stem parallel to the lower side of the humeral head.



Fig. 54

To remove the cement from the thread if the humeral stem is cemented, a drill jig is first inserted into the oval cone of the humeral stem and then used to guide the drill (Fig. 55). Care should be taken to ensure that drilling is continued as far as possible.



Fig. 55

Any remaining cement is now removed from the thread of the stem with the thread reamer (Fig. 56).



Fig. 56

The X-pin is now screwed into the humeral stem (Fig. 57). The X-pin guides the reamer and is absolutely essential for directing and fixing the new head. Care should be taken to ensure that the X-pin is fully screwed in and that the oval internal cone is not damaged when this happens.

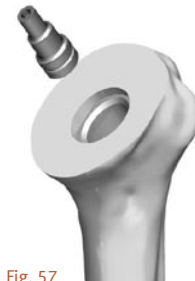

Fig. 57

To remove the cement above the oval cone, use the RH reamer (Fig. 58). Reaming is performed with the cannulated handle from the glenoid tray.

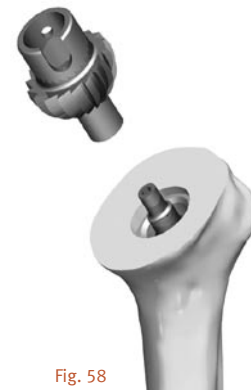

Fig. 58

The resection plane is recreated using the oscillating saw.

The plane of the humeral osteotomy is then protected with the humeral head protector.

Glenoid preparation and implantation can start – see page 16 of this surgical technique.

After completing treatment of the glenoid, examine the removed humeral head with the ball taper fixed to it for damage.

If you, as the surgeon, have established without doubt that the removed humeral head with the ball taper fixed in place is still in perfect condition, you may place the same humeral head back on the humeral stem in the same position as before, positioning the oval cone with the required orientation.

Otherwise, a new humeral head with a new ball taper must be prepared and then inserted.

The cone plug connection between humeral head and humeral stem must be clean and dry when they are impacted together.

Removal of the Implant Stem

The stem holder with impactor is used if the humeral stem must also be removed after removal of the humeral head and reaming of the resection plane.

The stem holder is positioned on the cone of the stem as illustrated (Fig. 59). The X-pin must previously have been removed from the humeral stem. The stem holder is fixed tightly on the humeral stem, using a tension screw which is screwed into the thread of the stem. The tension screw is tightened with the hexagonal spanner.




Fig. 59

The impactor with slide hammer weight can now be screwed onto the stem holder.

The implant stem is now removed from the humeral canal with energetic blows.

If the ball head cannot be removed with the humeral head, a monoblock construct must be accepted. A readjustment of the humeral head on a humeral stem of this type is not possible, the implant stem must be fully removed.

The reamer is passed over the tapered ball of the implant, opening up a free position for applying the stem extraction instrument (Fig. 60).



Fig. 60

Reaming is performed using the cannulated handle from the glenoid tray.

The stem extraction instrument consists of a collet chuck, an extraction shell and a screw with an internal hexagon (Fig. 61). This is required for the removal of the humeral stem. The collet chuck is first placed on the ball. The extraction shell is then placed over this collet chuck. The screw with the internal hexagon is tightened, resulting in a secure connection between the collet chuck and the extraction shell.




Fig. 61

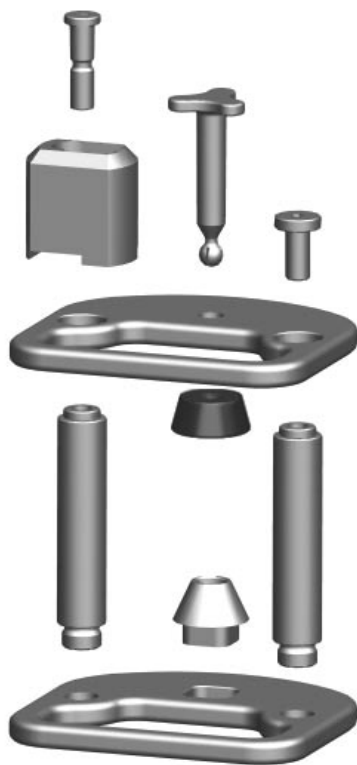

The impactor instrument with slap hammer weight can now be connected (Fig. 62). The implant is now removed from the humerus along the shaft axis.

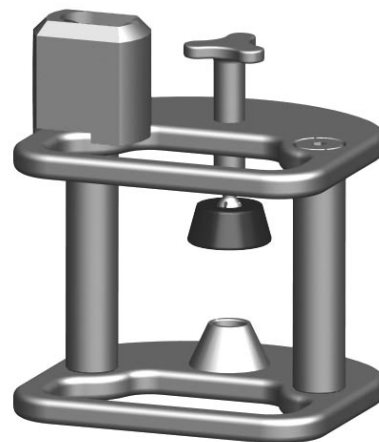
Fig. 62

Preparation and Description of the Assembly of the Instruments


Assembly block for the humeral head



Either the cone holder – right fracture – or the cone-holder – left fracture – should be used in preparation for fracture care. (See special fracture setting on page 23.)



Assembly and disassembly of the Impactor





Charging the Impactor

Tense the Impactor with the help of the loading aid (charger).

The Impactor is connected through the shaft of the charger.

There are two possible procedures:
 Either the charger is placed on the table, or the charger is held in one hand, the Impactor in the other, while the shaft of the charger is inserted into the Impactor and tenses the Impactor.



Review of the Instrument Trays

Instrument tray I



Instrument tray II



Glenoid tray



Revision tray



Contact your Zimmer representative or visit us at www.zimmer.com

